



Syncopal Episode as a Result of Elevated Ammonia Levels: A Case Report

Abuagla Q*, Aljaberi M and Calvello E

Tawam Hospital, United Arab Emirates University, UAE

Abstract

Valproic acid is an increasingly common medication used as an anticonvulsant, a mood stabilizer and in the prophylaxis of migraine headaches. Generally, Valproic Acid (VPA) is well tolerated, with a favorable safety profile. Serious adverse reactions such as hepatic failure, pancreatitis, thrombocytopenia, and hyperammonemic encephalopathy are rare. While the incidence of VPA-induced hyperammonemic encephalopathy is unknown, it can progress to fatal outcome without early recognition and appropriate treatment. We present a case of VPA-induced hyperammonemia in an epileptic patient presenting with a chief complaint of syncope and confusion.

Case Presentation

A 40 year old male was brought by ambulance to our emergency department after a 10 minute syncopal event at work witnessed by his co-workers. The bystanders reported that the patient appeared dizzy prior to losing consciousness. There was no reported head trauma, generalized tonic-clonic movement, tongue biting or urinary incontinence. Upon arrival the patient was unable to give a reliable history secondary to ongoing confusion. Collateral information was obtained from the wife via a phone interview who confirmed the patient's history of seizure disorder treated with lamotrigine, topiramate, levetiracetam and VPA [1-3]. The wife reported that the patient was unable to drive his car due to multiple episodes of dizziness that morning. She denied any history of similar past symptoms, change in recent medication regimens or possibility of intentional overdose for her husband

Initial vital signs showed a heart rate of 68 beats per minute, respiratory rate 23 breathes per min, blood pressure 115/87 mmHg and oxygen saturation of 98% by pulse oximeter. Blood glucose level was 7.5 mmol/L. Physical examination was within normal limits except for confusion and slowed speech and horizontal nystagmus. Laboratory investigations of electrolytes, blood urea nitrogen, creatinine, cardiac enzymes, D-dimer and liver function tests were within normal limits. A valproate level of 46 mg/L (50-100 mg/L) and ammonia elevated at 63 imol/L (9-35 imol/L). Computed tomography of the head showed no intracranial pathology. Electrocardiography revealed normal sinus rhythm with normal intervals and no ischemic changes or evidence of arrhythmias. The patient was diagnosed with presumptive VPA - induced hyperammonemia encephalopathy and admitted for observation after discontinuation of the VPA and treatment with lactulose in the Emergency Department. During the inpatient hospitalization, the patient's confusion resolved with repeated doses of lactulose. An EEG was performed and found to be normal. The patient refused to take VPA or any antiepileptic medication as inpatient because he didn't trust the generic drug name, meanwhile his hyperammonemia resolved (repeat level 35 imol/L) within 48 hours and the patient was discharged to outpatient follow up with resumption of his previous regimen of antiepileptic's with the same dosage.

Discussion

The incidence of symptomatic valproate induced hyperammonemia are not well established, It has been described that 16.2% to 52.3% of patient on VPA had hyperammonemia [2]. In a case series, asymptomatic hyperammonemia was observed in 52 percent of patients receiving valproate monotherapy [4]. A case review that reviewed 19 cases of VPA -induced encephalopathy showed 13 patients had normal or slightly increased ammonia level where 6 patients had increased ammonia level averaging 191- 191.2 gmol/l (111—259 gmol/l) [5]. There are currently no specific recommendations for routine screening for asymptomatic hyperammonemia, nor are there any known consequences [1-3,5-12]. VPA -induced hyperammonemic encephalopathy may have wide-ranging presentation starting from simple fatigue, gastrointestinal symptoms, such as anorexia

OPEN ACCESS

*Correspondence:

Qais Abuagla, Tawam Hospital, United Arab Emirates University, Bin Zayad Street (32nd Street), Khalidia, P.O. Box: 109090, UAE;

E-mail: qaiselfadil@gmail.com

Received Date: 16 Dec 2016

Accepted Date: 04 Feb 2017

Published Date: 07 Feb 2017

Citation:

Abuagla Q, Aljaberi M, Calvello E. Syncopal Episode as a Result of Elevated Ammonia Levels: A Case Report. *Ann Clin Case Rep.* 2017; 2: 1260.

Copyright © 2017 Abuagla Q. This is an open access article distributed under the Creative Commons Attribution License, which permits unrestricted use, distribution, and reproduction in any medium, provided the original work is properly cited.

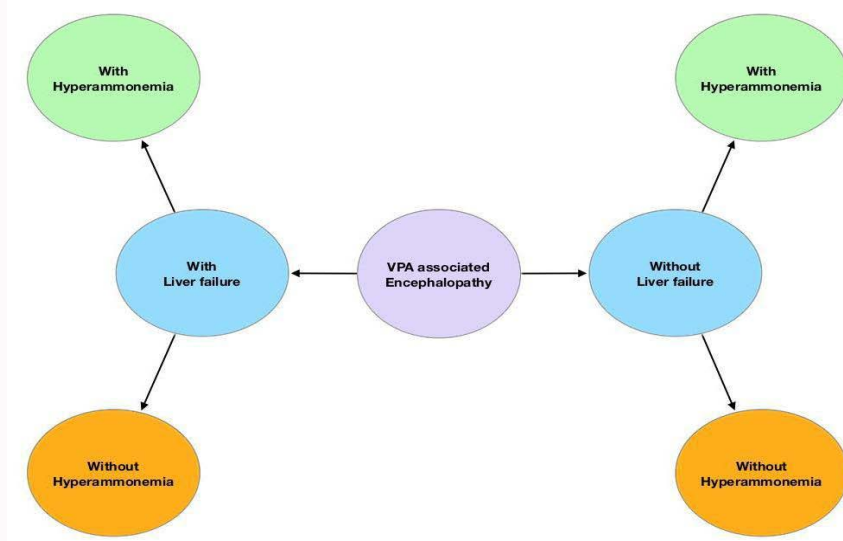


Figure 1: Types of VPA-Associated Encephalopathy.

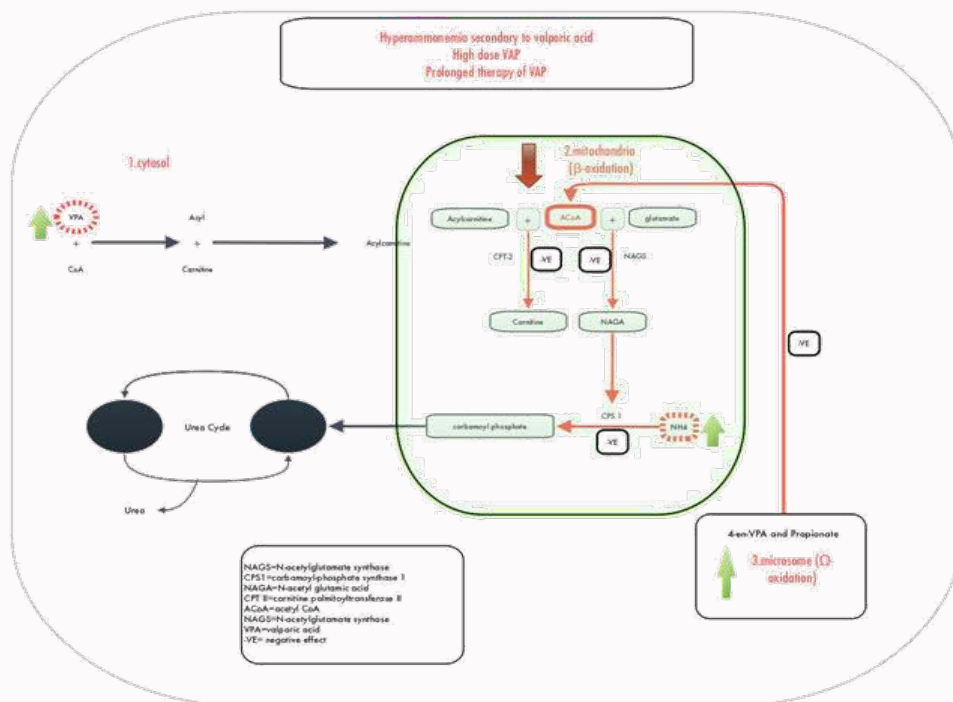


Figure 2: Schematic representation of potential mechanisms of valproate-induced hyperammonemia (VHA). Ammonia, a byproduct of amino acid conversion to a-keto acids, is ultimately converted in the liver to urea. VPA interferes with this process the rough direct inhibition of carbamoyl phosphate synthetase (CPS) the first enzyme of the urea cycle, and indirectly by depleting carnitine.

and vomiting, and neurological symptoms such as finger tremor and nystagmus, gradually resulting in disturbed consciousness [6]. VPA -induced hyperammonemic encephalopathy has been described and classified into four forms based on liver function, VPA level and ammonia: direct toxic effect of VPA inducing encephalopathy, with high serum levels of VPA, but normal ammonia; hyperammonemic encephalopathy; encephalopathy with impaired liver function and hyperammonemia; and encephalopathy with hepatopathy, but with normal ammonia (Figure 1). VPA -induced encephalopathy should also be considered whenever a patients presents with a rapidly progressing severe delirium who is on VPA. These patients

do deserve an electroencephalogram and blood tests for serum ammonia, liver enzymes and VPA serum levels [1,8,12]. Pathogenesis of hyperammonemia caused by VPA is not entirely understood but appears to be the main cause of encephalopathy [1,3,12]. Ammonia is produced by the breakdown of amino acids in the liver and is then directly excreted in the urine or converted into urea, the main pathway of nitrogen excretion. Blood ammonia levels may increase as a result of VPA induced increase renal ammonia production due to reduced glutamine synthesis therefore accumulation of glutamate and ammonia. Another proposed mechanism may be due to the inhibition of carbamoyl phosphate synthetase or the reduction

of hepatic ammonia metabolism owing to decreased carnitine availability, which leads to suppression of fatty acid β -oxidation. Hyperammonemia may occur more frequently among patients with carnitine deficiency and those with congenital enzymatic defects in the urea cycle (Figure 2). Another potential mechanism is by direct neuronal toxicity due to increased intracellular concentrations of glutamate and ammonium in astrocytes which may lead to neuronal injury and cerebral edema [2,5,7-9]. Phenobarbital, and less frequently, phenytoin, carbamazepine and topiramate may exacerbate valproate related hyperammonemic encephalopathy [2,7]. The primary treatment of VPA-induced Encephalopathy is withdrawal of VPA and standard medical management is similar to hepatic encephalopathy. Lactulose, a nonabsorbable disaccharide, acidifies the gastrointestinal lumen which decreases ammonia production by coliform bacteria [13]. Alternatively, antibiotics to target ammonia producing bacteria such as rifaximin, neomycin or metronidazole may be given [7]. For some with severe hyperammonemia, hemodialysis may be required [7,8]. As VPA causes decreased serum levels of carnitine, administration of L-carnitine (50-100 mg/kg/day orally or IV) has been shown to be effective in reducing ammonia levels and in symptomatic improvement [2,5,9]. L-carnitine administration has been shown to reduced mortality in patients with severe VPA-induced Encephalopathy [2,5,9].

Conclusion

Our patient had a 30-year history of epilepsy, controlled by VPA that presented to the ED with a chief complaint of syncope and confusion and was found to have hyperammonemia with a normal VPA level. The patient responded well to conservative medical therapy with drug cessation and lactulose administration. L-carnitine was not given while inpatient. Surprisingly, the inpatient team did not recommend cessation of the patient's VPA for unclear reasons. Best practice management for VPA-induced hyperammonemia includes drug cessation, lactulose, L-carnitine and consideration of an antibiotic such as rifaximin. VPA -induced encephalopathy is a potentially serious consequence of the use of VPA. Emergency physicians should consider VPA-induced encephalopathy early in their assessment of a patient presenting with syncope, change in mental status, dizziness or nystagmus. Diagnostics evaluation should include liver function tests, ammonia and VPA levels with early aggressive management of hyperammonemia and VPA cessation as death has been a consequence of this condition [1,5,8,12]. Early consideration and treatment of hyperammonemia by ED physician in any patient taking VPA, regardless of VPA level, can help avoid unnecessary life-threatening complications in these patients.

References

1. Gerstner T, Bell N, König S. Oral valproic acid for epilepsy – long-term experience in therapy and side effects. *Expert Opin Pharmacother*. 2008; 9: 285-292.
2. Alberto Verrotti DT, Guido Morgese, Francesco Chiarelli. Valproate-Induced Hyperammonemic Encephalopathy. *Metabolic Brain Disease*. 2002; 17: 367-373.
3. Segura-Bruna N, Rodriguez-Campello A, Puente V, Roquer J. Valproate-induced hyperammonemic encephalopathy. *Acta Neurol Scand*. 2006; 114: 1-7.
4. R N Ratnaik, G J Schapel, G Purdie, R H Rischbieth, S Hoffmann. Hyperammonaemia and hepatotoxicity during chronic valproate therapy: enhancement by combination with other antiepileptic drugs. *Br J clin Pharmacol*. 1986; 22: 100-103.
5. Wadzinski J, Franks R, Roane D, Bayard M. Valproate-associated Hyperammonemic Encephalopathy. *J Am Board Fam Med*. 2007; 20: 499-502.
6. Kifune A, Kubota F, Shibata N, Akata T, Kikuchi S. Valproic acid-induced hyperammonemic encephalopathy with triphasic waves. *Epilepsia*. 2000; 41: 909-912.
7. Carr RB, Shrewsbury K. Hyperammonemia due to valproic acid in the psychiatric setting. *Am J Psychiatry*. 2007; 164: 1020-1027.
8. Lewis C, Deshpande A, Tesar GE, Dale R. Valproate-induced hyperammonemic encephalopathy: a brief review. *Curr Med Res Opin*. 2012; 28: 1039-1042.
9. Mihaela Stefan, Samuel Bavli. Recurrent Stupor Associated with Chronic Valproic Acid Therapy and Hyperammonemia. *Hospital Physician*. 2009; 47: 17-20.
10. Paolo Federico, Saleh Alqahanti, Robert P Myers. Possible new clinical sign of hyperammonemia. *CMAJ*. 2008; 178: 326-326a.
11. Saleh Alqahtani, Paolo Federico, Robert P Myers. A case of valproate-induced hyperammonemic encephalopathy: look beyond the liver. *Canadian Medical Association Journal*. 2007; 177: 568-569.
12. Gerstner T, Buesing D, Longin E, Bendl C, Wenzel D, Scheid B, et al. Valproic acid induced encephalopathy--19 new cases in Germany from 1994 to 2003 --A side effect associated to VPA-therapy not only in young children. *Seizure*. 2006; 15: 443-448.
13. Cash WJ, McConville P, McDermott E, McCormick PA, Callender ME, McDougall NI. Current concepts in the assessment and treatment of hepatic encephalopathy. *QJM*. 2010; 103: 9-16.