



## Unusual Presentation of a Metastatic Choriocarcinoma: A Case Report of Non-Gestational Choriocarcinoma Presenting as Advanced Colorectal Cancer

Elizabeth Parker<sup>1</sup>, Julie Middleton<sup>1</sup>, Rochelle L Garcia<sup>2</sup>, Mark R Kilgore<sup>2</sup> and Renata R Urban<sup>3\*</sup>

<sup>1</sup>Department of Psychiatry and Behavioral Sciences, University of Washington School of Medicine, USA

<sup>2</sup>Department of Pathology, University of Washington Medical Center, USA

<sup>3</sup>Department of Obstetrics and Gynecology, University of Washington Medical Center, USA

### Abstract

**Case:** A 51-year-old perimenopausal female presented with persistent vaginal bleeding, elevated human chorionic gonadotropin (hCG), and colonic and liver masses. Her initial diagnosis was felt to be metastatic colorectal cancer. Given that her hCG was rising, her pathology was re-reviewed and felt to be consistent with choriocarcinoma. To date, she received three cycles of EMA-CO chemotherapy with resultant drop in hCG.

**Conclusion:** This patient's presentation and subsequent diagnosis with metastatic choriocarcinoma highlight the importance of evaluating a gynecologic complaint noted in the context of a diagnosis of advanced cancer. Although the initial presentation with anemia in the setting of colorectal and liver masses painted a clinical picture raising concern for metastatic colorectal cancer, the significantly elevated hCG level found in the investigation of irregular bleeding requires additional evaluation. This case report emphasizes the importance of considering a diagnosis of choriocarcinoma even in patients with remote or unclear history of pregnancy.

### OPEN ACCESS

#### \*Correspondence:

Renata R Urban, Department of  
Obstetrics & Gynecology, University of  
Washington Medical Center, 1959 NE  
Pacific Street, Campus Box 356460,  
Seattle, WA 98195-6460, USA,  
E-mail: urbanr@uw.edu

Received Date: 03 Oct 2016

Accepted Date: 25 Oct 2016

Published Date: 01 Nov 2016

#### Citation:

Parker E, Middleton J, Garcia RL,  
Kilgore MR, Urban RR. Unusual  
Presentation of a Metastatic  
Choriocarcinoma: A Case Report of  
Non-Gestational Choriocarcinoma  
Presenting as Advanced Colorectal  
Cancer. *Ann Clin Case Rep.* 2016; 1:  
1173.

Copyright © 2016 Urban RR. This is  
an open access article distributed under  
the Creative Commons Attribution  
License, which permits unrestricted  
use, distribution, and reproduction in  
any medium, provided the original work  
is properly cited.

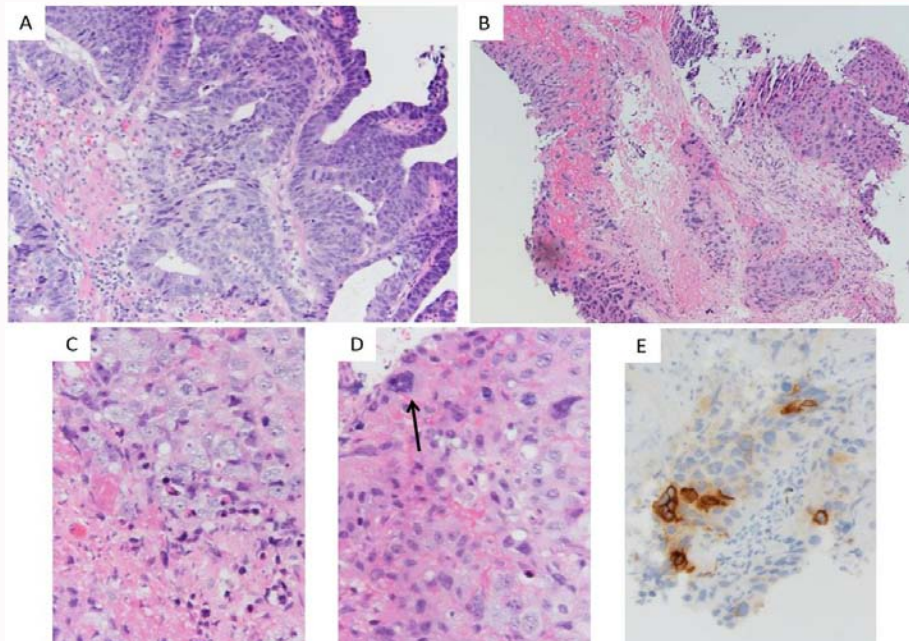
**Keywords:** Gestational trophoblastic disease; Hcg; EMA-CO; Choriocarcinoma; Colon cancer

### Introduction

Colorectal cancer is the third most common cancer in the United States with an incidence of nearly 136,000 cases each year. A common presentation is iron deficiency anemia secondary to blood loss from cancerous lesions. Nearly 95% of colorectal cancer is adenocarcinoma with varying morphologic features and cell differentiation. A number of risk factors contribute to the accumulation of mutations that are present in colorectal neoplasia. Obesity, western diet, inflammatory bowel disease, family history, and genetic predisposition are all thought to factor into the stepwise progression of mutations transforming adenomas to adenocarcinoma. In the advanced stage of disease, metastasis is most common to the liver through hematogenous spread from venous blood supply [1].

In contrast to this common malignancy, the incidence of choriocarcinoma is 1 in 20-40,000 pregnancies. The diagnosis is made by rising hCG in the absence of a gestation and histology, if available. Because the tumors are highly vascular, biopsy of metastases is not recommended due to bleeding risk. Presenting symptoms include vaginal bleeding, dysmenorrhea, and focal symptoms related to common areas of metastasis such as hemoptysis, vaginal bleeding, and focal neurologic symptoms. Metastatic spread is common for this highly vascular malignancy, and at presentation 80% of patients have lung involvement, 30% vaginal involvement, 10% liver involvement, and 10% central nervous system involvement. Not all choriocarcinomas are preceded by a gestational event, and can be gestational (half molar pregnancies and half non-molar pregnancies) or non-gestational [2]. Primary ovarian choriocarcinoma is exceedingly rare [3].

The management of high-risk metastatic gestational trophoblastic neoplasms such as choriocarcinoma (stage II/III with prognostic score  $\geq 7$  and stage IV) includes multi-agent chemotherapy with possible radiation or surgery depending on involved sites and is associated with 80-90% survival [4]. Early management included MAC, methotrexate, actinomycin-D, and cyclophosphamide with a 63-71% cure rate. In the 1980s, management evolved into CHAMOCA



**Figure 1:** (A) Representative foci more reminiscent of colorectal-type neoplasm (10x). (B) Representative foci of extensively necrotic high-grade neoplasm with associated necrotic debris (10x). (C) Foci of probable cytotrophoblast-like neoplastic cells with associated apoptotic bodies and necrotic debris (40x). (D) Focus of neoplasm with multinucleated cell (arrow) suggestive of syncytiotrophoblast-like neoplastic cells intermixed with probable cytotrophoblast-like neoplastic cells, hemorrhage, and apoptotic bodies (40x). (E) Beta-HCG immunohistochemical stained slide revealing immunoreactivity in a subset of neoplastic cells.

(cyclophosphamide, hydroxyurea, actinomycin D, methotrexate with folic acid, vincristine, doxorubicin) although this combination was problematic with significant toxicity. Management further evolved with the recognition of the activity in treating GTN with etoposide. Subsequent therapy with EMA-CO (etoposide, methotrexate with folic acid, actinomycin D, cyclophosphamide, vincristine) resulted in improved survival rates [5].

## Case Presentation

A 51-year-old G1P0010 perimenopausal woman was in her usual state of good health until experiencing increasingly heavy menses in 2015. She presented as an outpatient to her primary care physician, was found to be anemic, and was treated with iron. In January 2016, she again experienced persistent vaginal bleeding. She presented again in April to care and was prescribed Provera. She was then referred to an obstetrician/gynecologist.

She felt well until June 2016 when she developed right upper quadrant pain and presented to a local emergency room. Her initial evaluation included an elevated serum human chorionic gonadotropin (hCG) of 18,000, but a pelvic ultrasound revealed an empty uterus and unremarkable adnexa. A subsequent CT of the abdomen and pelvis revealed a mass in the ascending colon, enlarged mesenteric lymph nodes and multiple hypodense liver lesions. A PET/CT scan confirmed a hypermetabolic mass in the ascending colon and mesentery, multiple liver masses and mesenteric and retroperitoneal lymphadenopathy. There were also hypermetabolic peritoneal and pelvic deposits including in the adnexa. Colonoscopy revealed a partially obstructive ascending colonic mass which was biopsied. The pathology was read as poorly differentiated adenocarcinoma of the ascending colonic mass and tubulovillous adenoma of the polyp. The patient was diagnosed with presumed colorectal carcinoma and plans were made to start a FOLFOX chemotherapy regimen. During this time, her hCG was rechecked and was found to have

rised to 96,000. Given the discrepancy between the rising hCG and tumor presentation, the pathology was reviewed at a tertiary care center and was felt to be consistent with choriocarcinoma (Figure 1). Immediately after diagnosis, the patient was brought in for emergent initiation of chemotherapy with EMA-CO. Additional evaluation prior to chemotherapy included a brain MRI which showed no evidence of cerebral disease.

Upon further discussion, her gynecologic history included menarche at age 12 years with irregular and painful menses, and an elective abortion at age 16 without additional pregnancies. She used oral contraception between the age of 16 to 40, and used condoms for birth control.

The morphologic and immunohistochemical findings in this clinical scenario are most consistent with a diagnosis of choriocarcinoma. All photos are taken with a 0.55 mm objective and an Olympus DP73 camera, A-D is photos of H&E-stained slides taken at the indicated power.

## Discussion

This patient's presentation and subsequent diagnosis with metastatic choriocarcinoma highlights certain clinical concepts. Even in a perimenopausal female, incorporating hCG into the evaluation of abnormal vaginal bleeding is appropriate. In addition, an elevated hCG in the absence of pregnancy should raise serious concerns for a gestational trophoblastic neoplasm or ovarian germ cell tumor. Although the patient's initial presentation with anemia in conjunction with colon mass and hepatic metastases raised concern for metastatic colorectal cancer, a rising hCG level cannot be ignored.

This case report emphasizes the importance of considering a diagnosis of choriocarcinoma even in patients with remote or unclear history of pregnancy. The differentiation of gestational versus non-gestational choriocarcinoma is useful in guiding management and

providing prognostic information to patients. Because gestational choriocarcinomas arise from gestational tissue, the tumors boast paternal DNA, with or without maternal DNA. Nongestational choriocarcinoma is a malignant transformation of trophoblastic cells unrelated to a gestational event. As such, the tumors boast maternal DNA without paternal DNA. Importantly, nongestational choriocarcinoma is highly aggressive, more so than gestational choriocarcinoma, and all cases of nongestational choriocarcinoma are treated with multiagent chemotherapy regardless of stage and prognostic score [6].

Genetic technology has advanced such that reliable assays using PCR-based DNA analysis of microsatellite markers or short tandem repeat analysis of genetic material can correctly identify if tumor DNA is paternal, maternal or both [7,8]. A good clinical history may mitigate the need to distinguish between gestational and nongestational choriocarcinoma, however that is not always the case. In 2014 Buza et al. [6] reported a case of a 22 year old G1P1 who presented with her last menstrual period 10 weeks prior, elevated hCG to >200,000 and a right adnexal mass. Upon DNA genotyping she was determined to have nongestational choriocarcinoma. The patient did well after surgical resection and multiagent chemotherapy with EMA-EP (etoposide, metotrexate, actinomycin D, and cisplatin [6].

Regarding management, nongestational choriocarcinoma is thought to be more aggressive, warranting multiagent chemotherapy regardless of stage [2]. Distinguishing gestational versus nongestational choriocarcinoma would be important if the patient has stage I or stage II/III disease with a low prognostic score disease, since these patients would receive single agent chemotherapy per current guidelines. However, choriocarcinoma is an aggressive tumor often presenting with metastases, so many patients receive multiagent chemotherapy and management does not change by distinguishing gestational versus nongestational disease.

## Conclusion

For this patient, the measurement of hCG and subsequent follow-up values in the context of irregular bleeding was critical in providing the unusual diagnosis in what seemed to be an advanced colorectal carcinoma. Without this and careful review of pathology slides, the diagnosis of choriocarcinoma would not have been made. Emergent

and immediate initiation of chemotherapy drastically improves the prognosis of advanced choriocarcinoma. Whether the distinction of gestational vs non-gestational choriocarcinoma is important to the management of disease through DNA genotyping is not yet known, although it would be most important in stage I or stage II/II with a low prognostic score so the proper chemotherapy is administered.

## Author's Contribution

EP was involved with this patient's initial admission and the writing of this manuscript. JM was involved with writing this manuscript. RU provided guidance, mentorship, and editing. RG and MK provided guidance, pathologic expertise and micrographs.

## References

1. Siegel RL, Miller KD, Jemal A. Cancer statistics. *CA Cancer J Clin.* 2016; 66: 7-30.
2. Lurain JR. Gestational trophoblastic disease I: epidemiology, pathology, clinical presentation and diagnosis of gestational trophoblastic disease, and management of hydatidiform mole. *Am J Obstet Gynecol.* 2010; 203: 531-539.
3. Vance RP, Geisinger KR. Pure nongestational choriocarcinoma of the ovary. Report of a case. *Cancer.* 1985; 56: 2321-2325.
4. Lurain JR. Gestational trophoblastic disease II: classification and management of gestational trophoblastic neoplasia. *Am J Obstet Gynecol.* 2011; 204: 11-18.
5. Newlands ES, Bagshawe KD, Begent RH, Rustin GJ, Holden L. Results with the EMA/CO (etoposide, methotrexate, actinomycin D, cyclophosphamide, vincristine) regimen in high risk gestational trophoblastic tumours, 1979 to 1989. *Br J Obstet Gynaecol.* 1991; 98: 550-557.
6. Buza N, Rutherford T, Hui P. Genotyping diagnosis of nongestational choriocarcinoma involving fallopian tube and broad ligament: a case study. *Int J Gynecol Pathol.* 2014; 33: 58-63.
7. Aranake-Chrisinger J, Huettner PC, Hagemann AR, Pfeifer JD. Use of short tandem repeat analysis in unusual presentations of trophoblastic tumors and their mimics. *Hum Pathol.* 2016; 52: 92-100.
8. Cankovic M, Gaba AR, Meier F, Kim W, Zarbo RJ. Detection of non-maternal components of gestational choriocarcinoma by PCR-based microsatellite DNA assay. *Gynecol Oncol.* 2006; 103: 614-617.