



Rapid Relief of Acute Posttraumatic Headache and Face Pain with Lower Cervical Spine Paravertebral Intramuscular Injections

Gary A Mellick^{1*} and Larry B Mellick²

¹Department of Neurology, DeKalb Regional Medical Center, USA

²Department of Pediatrics, DeKalb Regional Medical Center, USA

Abstract

Background: Treatment of headaches and facial pain with lower cervical injections has been reported previously but such treatment of acute posttraumatic headaches has not previously been reported.

Aims: Describe the lower cervical paravertebral injection technique and report the efficacy of the injections in a series of patients with acute posttraumatic headaches.

Methods: In a series of patients with recent head injuries and resultant acute posttraumatic headache, local anesthetic was injected intramuscularly into the lower cervical region approximately 2 inches lateral to the seventh cervical vertebral process.

Results: In this series of patients, there was rapid headache relief with resolution of the headache pain as well as accompanying facial and dental pain.

Conclusions: The results are indicative that lower cervical intramuscular local anesthetic injections may be an effective therapeutic modality to treat acute posttraumatic headaches.

Keywords: Posttraumatic headache; Head trauma; Cervical injections; Trigeminovascular system; Cephalgia; Pain; Traumatic brain injury

Introduction

Posttraumatic headache (PTH) ascribed to head injury is defined as a secondary headache according to the International Classification of Headache Disorders, 3rd edition (beta version) (ICHD-3 beta) [1]. The criteria for acute posttraumatic headache (APTH) require that the headache begins within 7 days after the head injury and resolves within 3 months of the head injury [1]. Recent media attention on concussion and sports related injuries [2-4] and head injuries as a result of the Iraq and Afghanistan military conflicts⁵ has greatly increased public awareness of posttraumatic headache since it is the most common symptom that results from head injury [6,7]. Acute posttraumatic headache (APTH) is the most frequent finding after closed head injury in the US military [8] and headache is the most constant symptom following concussion occurring in more than 90 % of athletes with sports-related concussion [9]. The prevalence of chronic daily headache (CDH) in returning U.S. soldiers after a deployment-related concussion is 20%, or 4- to 5-fold higher than that seen in the overall U.S. population [10]. Despite an incidence of approximately 3.8 million sports-related concussions per year, the pathophysiological basis of this injury continues to be poorly understood [11]. APTH has remained a distinct treatment challenge for medical personnel and as a result, it is often inadequately controlled [12]. APTH frequently confounds deployment or return to play decisions [11]. The treatment of PTH is largely empiric. To date, no randomized, blinded, prospective, class I medication treatment trials of PTH have been conducted [12].

This is the first case series reporting the use of the lower cervical intramuscular bupivacaine injection in the treatment of acute posttraumatic headache. The lower cervical injection for the treatment of headache and orofacial pain has been previously reported [13-16]. The lower cervical paraspinous injection is similar to a typical intramuscular trigger point injection and is performed as follows. A syringe is filled with 3 or 4 cc of 0.5% bupivacaine HCL. The lower dorsal cervical spine is sterilely prepped by swabbing with an antiseptic solution and then with the patient sitting in

OPEN ACCESS

*Correspondence:

Gary Mellick, Department of Neurology, DeKalb Neurology and Sleep, DeKalb Regional Medical Center, Fort Payne, AL, USA,

E-mail: mellickg@msn.com

Received Date: 22 Jun 2016

Accepted Date: 12 Sep 2016

Published Date: 14 Sep 2016

Citation:

Mellick GA, Mellick LB. Rapid Relief of Acute Posttraumatic Headache and Face Pain with Lower Cervical Spine Paravertebral Intramuscular Injections. *Ann Clin Case Rep.* 2016; 1: 1132.

Copyright © 2016 Mellick GA. This is an open access article distributed under the Creative Commons Attribution License, which permits unrestricted use, distribution, and reproduction in any medium, provided the original work is properly cited.

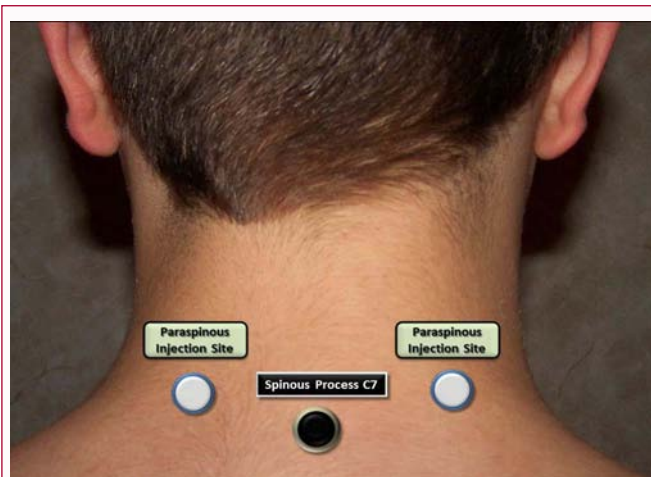


Figure 1: Injection sites bilateral to the sixth or seventh cervical vertebral spinous process.

front of the clinician with their head held upright in a relaxed, neutral position, the medication is slowly guided into untensed musculature 2 to 3 cm lateral to the C6 or C7 vertebral spinous process along an axis horizontal to the floor (Figure 1). The needle should be inserted approximately one inch into the paravertebral musculature perpendicular to or with a small upward angulation to the transverse plane of the lower dorsal neck on both sides of the spine. As with any injection procedure careful identification of anatomical landmarks, aspiration before injection, and appropriate precautions should be taken to manage the potential of vasodepressor syncope.

Case Presentation

Case 1: A 17 year old female driving her mother's truck at 50 mph bent down to pick up something off the floor and crashed into back of a stopped car. She reported hitting her head against the steering wheel as well as hitting her anterior left leg against another part of the truck. No airbags deployed. However, the front of the truck was severely crushed and windows were shattered. She experienced no loss of consciousness. She reported that her headache was diffuse and 8 out of 10 in severity. She also reported forehead soreness where her head struck the steering wheel. Her neurologic examination was non-focal and normal. Minimal edema and erythema was noted of the forehead. After discussing imaging options and risks with the patient's mother a decision was made to not obtain a CT scan and to observe the patient for a period of time in the emergency department.

Paraspinal cervical injections with bupivacaine were offered to the patient for management of her post traumatic headache. The cervical injections resulted in complete headache relief rapidly and within 5 to 10 minutes. The patient was subsequently discharged home headache free after a period of observation in the emergency department.

Case 2: While visiting a friend, a 23-year-old male attempted to sit on a nine-foot high horizontal metal bar. When he jumped on to the bar, he fell backwards and landed headfirst on a cement patio. He immediately experienced a brief loss of consciousness. During the subsequent ED evaluation he received sutures for a scalp laceration, cervical spine x-rays and a head CT scan that showed no intracranial pathology. In addition to local neck and head pain at the site of impact, he complained of a severe, generalized unrelenting headache that was resistant to treatment with NSAIDs, isometheptene and

acetaminophen with codeine. This headache persisted for 3 weeks following the injury. The headache intensity was always above 6/10 on a verbal pain scale and was associated with photophobia and blurred vision. On presentation to a private pain practice the examination was significant only for dorsal scalp allodynia and occipital hyperalgesia. When the lower cervical paravertebral injections were completed the patient reported that he felt a heavy, warm sensation travel up the back of his neck. His headache disappeared completely in less than 3 minutes. The dorsal scalp allodynia and hyperalgesia were also completely relieved, as was the associated photophobia. When seen two weeks later, the patient reported that his headache following the injection was never more than 1-2/10 in severity. A second injection was completed with complete relief of the headache. Approximately two weeks later the patient reported a return of his headache after bicycling and vigorous exercise. Following a lower cervical injection the patient's headache again completely resolved along with associated symptoms.

Case 3: Five days prior to evaluation this 21 year-old male was struck in the left temporal area by a pitched softball. A continuous headache developed following the head injury. His examination was significant for mechanical hyperalgesia over the impact region. Headache severity was rated at 7/10. Bilateral lower cervical intramuscular injection with bupivacaine and solumedrol resulted in rapid and complete headache relief. Additionally, the hyperalgesia of the contusion area was also relieved. When re-evaluated 3 weeks later, the patient related that his headache had not returned. Temporal scalp pain was 1-2/10 in severity for two additional days before the pain completely resolved. On subsequent visits, the patient reported that his headache never returned.

Case 4: A 22-year-old white male sustained a head injury and orofacial trauma after colliding with a friend while roller blade skating. A brief loss of consciousness occurred. Additionally, there was avulsion and subsequent reimplantation of the right maxillary central incisor as well as extrusive luxation of the mandibular central incisors. Since the accident the patient had experienced ongoing severe right maxillary dental pain with hypersensitivity to cold water and light touch. He also experienced significant dental and gingival pain in the luxated but stabilized teeth. His pain was unresponsive to hydrocodone with acetaminophen or oxycodone with acetaminophen. In addition, the patient reported a constant, throbbing, posterior headache rated at 7-10/10 in severity. A C6-C7 paraspinal intramuscular bupivacaine injection was performed bilaterally. Not only was the patient's headache relieved, his dental pain was reduced to 1/10 in severity. Subsequent to the injection, the patient was able to bite down, drink tap water, and run cold water over his previously painful teeth. In follow-up, the patient reported that his dental pain remained diminished and that the headache had not returned.

Case 5: This 20 year-old male was assaulted at a local service station with resultant multiple face contusions. When he presented to the clinic one day after the injuries, he complained of continuous headache, severe facial pain and sleep disruption. His examination showed extensive ecchymoses and abrasions. The neurologic examination was unremarkable. Palpatory examination of the left orbital wall revealed crepitus and mechanical hyperalgesia over and around areas of facial injury as well as over his posterior scalp where he had fallen striking the back of his head with brief loss of consciousness. A subsequent facial CT scan showed an orbital wall

fracture and he was referred for ophthalmology specialty care. Treatment options were discussed with the patient and he elected to have a bilateral C6-C7 bupivacaine injection. The injection resulted in complete relief of the headache and facial pain. Examination after the injection showed complete relief of mechanical hyperalgesia of the head and face. He denied having further headache.

Case 6: A 21-year-old female United States Air Force security personnel presented with frequent and severe left sided posttraumatic migraine type that began approximately three weeks prior to evaluation when an M16 rifle fell seven feet from where it was hanging striking her in the region of the left temple. Since the event the patient had been experiencing a severe throbbing generalized headache and neuropathic allodynia at the site of weapon impact that was exquisitely tender to palpation. The first author discussed treatment options including bilateral lower cervical bupivacaine injections. When this procedure was eventually completed, she described rapid and complete headache relief. In addition, when the right temple was palpated, she described greatly diminished allodynia and hyperalgesia. When the patient returned for a subsequent visit, she reported that she had remained headache free for three days. She subsequently underwent a series of further lower cervical paravertebral injections but unfortunately the headaches and allodynia would return. A regimen of gabapentin 600 mg qid, 50 mg of amitriptyline qhs and duloxetine 300 mg po BID managed to reduce frequency and severity of her headaches as well as reduce the associated posttraumatic neuropathic pain.

Case 7: A 32-year-old Hispanic male sustained a brief loss of consciousness, head trauma and facial lacerations after flipping a 4-wheeler while camping. When he regained consciousness, he described an intense throbbing, generalized headache. A head CT and brain MRI were both negative for brain injury and cervical spine x-rays were normal. The facial lacerations were sutured and he was prescribed gabapentin 300 mg po qid and hydrocodone 7.5 mg po tid for pain and released. One week later, when seen for a neurology consultation, the patient complained of ongoing severe headache. Options of therapy were given and the patient opted to have a bilateral C6-C7 cervical intramuscular injection. When this was completed using 1.5 cc bupivacaine bilaterally, the patient experienced rapid headache resolution. He also reported a reduction in his residual facial pain which dropped from 5/10 to 1/10 in severity. At his one month follow up, he reported that the headache had never returned and his residual facial pain was of a lower intensity.

Case 8: A 19-year-old male presented with a severe (10/10), generalized headache one day after a head-on motor vehicle crash associated with a brief loss of consciousness. His work-up in a local emergency department consisted of brain imaging and cervical radiographs. His radiological studies and neurologic evaluation were normal. Palpation of the occiput and upper neck was painful. The patient elected to have the bilateral C6-C7 level intramuscular bupivacaine injections. The injections resulted in headache relief that occurred in less than one minute. Furthermore, the palpable occipital and upper neck tenderness were also relieved. When reevaluated one month and one year later, the patient reported that the headache had never returned.

Discussion

The mechanism of development of the APTH continues to be poorly understood. Multiple events and nociceptive stimuli activate

the trigeminovascular system, the final common pathway to a spectrum of headache presentations. Other headache classifications as well as migraine headaches and their associated signs and symptoms have been attributed to activation of the trigeminovascular system and the subsequent release of vasoactive neuropeptides [17-19]. Vasoactive neuropeptides such as calcitonin gene-related peptide (CGRP), substance P, and neurokinin A are released from trigeminal nerve terminals and these induce cranial vessel dilatation and inflammatory reactions in meningeal blood vessels. Vasodilatation, plasma protein extravasation, neurogenic inflammation and activation of trigeminovascular afferents are the end result [17,20,21]. Recent research by Tali Benromano, et al. [22] shows that mild closed head injury in mice is coupled with a selective enhancement of deep cranial trigeminal nociceptive processing. They found that mild head injury caused a rapid bilateral acute degranulation of periosteal mast cells which they believe leads to increased cranial nociception due to enhanced sensitivity of the trigeminal nociceptive system where the trigeminal ganglion holds the cell bodies of nociceptive fibers that innervate the calvarial periosteum and deeper cranial tissues where these fibers synapse centrally on neurons in the trigeminal nucleus caudalis which is part of the brainstem dorsal horn or what some call the trigeminal brainstem sensory nuclear complex [22]. In their opinion, this pro-inflammatory response within the cranial periosteum results in the APTH and that augmented pain processing by supraspinal nociceptive pathways does not appear to play a major role in mediating the resultant acute trigeminal hypernociception seen following head trauma.

The mechanism of pain relief following injection of anesthetic into the lower paravertebral cervical spine is unknown. One possible explanation is that pain relief may be related to the convergence of the trigeminal nerve with sensory fibers from the upper cervical roots at the trigeminal nucleus caudalis. It is also possible that these injections are interrupting afferents that are involved somehow in sustaining or possibly generating the headache and activating the trigeminovascular system. It may involve an inhibitory neuronal network that descends from the frontal cortex and hypothalamus through the periaqueductal gray to the rostral ventromedial medulla to the medullary and spinal dorsal horn. These cells are known to modulate the activity of the trigeminal nucleus caudalis and dorsal horn neurons [23-25].

Whatever the mechanism of pain relief, the apparent "soft reboot" process results in complete headache resolution along with relief of all associated signs and symptoms including centrally mediated scalp allodynia, [26,27] nausea, vomiting, photophobia, and phonophobia found with migraines headaches. The response is robust resulting in resolution of acute posttraumatic headache and orofacial pain within minutes.

In conclusion, our experience suggests that acute posttraumatic headaches are especially responsive to paraspinal injections with 0.5% bupivacaine. In this article we present a representative case series of patients presenting with acute posttraumatic headache who experienced rapid relief of headache and associated orofacial pain following intramuscular injection of 0.5% bupivacaine bilateral to the spinous process of a lower cervical vertebrae. A better understanding of the physiology behind the pain relief associated with this injection technique will provide greater insight into the genesis and pathophysiology of acute posttraumatic headache and other IHS categories of headaches.

References

1. Headache Classification Committee of the International Headache Society (IHS). The International classification of headache disorders, 3rd edition (beta version). *Cephalalgia*. 2013; 33: 629-808.
2. Jeanne M Hoffman, Sylvia Lucas, Sureyya Dikmen, Cynthia A Braden, Allen W Brown, Robert Brunner, et al. Natural history of Headache after Traumatic Brain Injury. *J Neurotrauma*. 2011; 28: 1719-1725.
3. Makdissi M, Darby D, Maruff P, Ugoni A, Brukner P, McCrory PR. Natural history of concussion in sport: markers of severity and implications for management. *Am J Sports Med*. 2010; 38: 464-471.
4. Pellman EJ, Powell JW, Viano DC, Casson IR, Tucker AM, Feuer H, et al. Concussion in professional foot ball: epidemiological features of game injuries and review of the literature- part 3. *Neurosurgery*. 2004; 54: 81-94.
5. Hoge CW, McGurk D, Thomas JL, Cox AL, Engel CC, Castro CA. Mild traumatic brain injury in U.S. soldiers returning from Iraq. *N Engl J Med*. 2008; 358: 453-463.
6. S Rezaei Jouzdani, Ali Ebrahimi, Maryam Rezaee, Mehdi Shishegar, Abbas Tavallaii, Gholamreza Kaka. Characteristics of posttraumatic headache following mild traumatic brain injury in military personnel in Iran. *Environ Health Prev Med*. 2014; 19: 422-428.
7. Erickson JC. Treatment outcomes of chronic post-traumatic headaches after mild head trauma in US soldiers: an observational study. *Headache*. 2011; 51: 932-944.
8. Holtkamp MD, Grimes J, Ling G. Concussion in the Military: an Evidence-Base Review of mTBI in US Military Personnel Focused on Posttraumatic Headache. *Curr Pain Headache Rep*. 2016; 20: 37.
9. Evans RW. Posttraumatic headaches in civilians, soldiers, and athletes. *Neurol Clin*. 2014; 32: 283-303.
10. Theeler BJ, Flynn FG, Erickson JC. Chronic daily headache in U.S. soldiers after concussion. *Headache*. 2012; 52: 732-738.
11. Seifert TD. Sports concussion and associated post-traumatic headache. *Headache*. 2013; 53: 726-736.
12. Watanabe TK, Bell KR, Walker WC, Schomer KS. Systematic review of interventions for post-traumatic headache. *PM R*. 2012; 4: 129-140.
13. Mellick LB, McIlrath ST, Mellick GA. Treatment of headaches in the ED with lower cervical intramuscular bupivacaine injections: a 1-year retrospective review of 417 patients. *Headache*. 2006; 46: 1441-1449.
14. Mellick GA, Mellick LB. Regional head and face pain relief following lower cervical intramuscular anesthetic injection. *Headache*. 2003; 43: 1109-1111.
15. Mellick LB, Mellick GA. Treatment of primary headache in the emergency department. *Headache*. 2004; 44: 840-841.
16. Mellick LB, Pleasant MR. Do pediatric headaches respond to bilateral lower cervical paraspinous bupivacaine injections? *Pediatr Emerg Care*. 2010; 26: 192-196.
17. Moskowitz MA. Neurogenic inflammation in the pathophysiology and treatment of migraine. *Neurology*. 1993; 43: S16-20.
18. Williamson DJ, Hargreaves RJ. Neurogenic inflammation in the context of migraine. *Microsc Res Tech*. 2001; 53: 167-178.
19. Bolay H, Reuter U, Dunn AK, Huang Z, Boas DA, Moskowitz MA. Intrinsic brain activity triggers trigeminal meningeal afferents in a migraine model. *Nat Med*. 2002; 8: 136-142.
20. Moskowitz MA. Neurogenic versus vascular mechanisms of sumatriptan and ergot alkaloids in migraine. *Trends Pharmacol Sci*. 1992; 12: 307-311.
21. Buzzi MG, Bonamini M, Moskowitz MA. Neurogenic model of migraine. *Cephalalgia*. 1995; 15: 277-280.
22. Tali Benromanoa, Defrin R, Ahn AH, Zhao J, Pick CG, Levy D. Mild closed head injury promotes a selective trigeminal hypernociception: Implications for the acute emergence of post-traumatic headache. *Eur J Pain*. 2015; 19: 621-628.
23. Basbaum AI, Fields HL. Endogenous pain control mechanisms: review and hypothesis. *Ann Neurol*. 1978; 4: 451-462.
24. Fields HL, Bry J, Hentall I, Zorman G. The activity of neurons in the rostral medulla of the rat during withdrawal from noxious heat. *J Neurosci*. 1983; 3: 2545-2552.
25. Sandkuhler J, Gebhart GF. Characterization of inhibition of a spinal nociceptive reflex by stimulation medially and laterally in the midbrain and medulla in the pentobarbital-anesthetized rat. *Brain Res*. 1984; 305: 67-76.
26. Malick A, Burstein R. Peripheral and central sensitization during migraine. *Funct Neurol*. 2000; 15: 28-35.
27. Burstein R, Cutrer MF, Yarnitsky D. The development of cutaneous allodynia during a migraine attack clinical evidence for the sequential recruitment of spinal and supraspinal nociceptive neurons in migraine. *Brain*. 2000; 123: 1703-1709.