



## Cesarean Scar Syndrome: Diagnostic Imaging and Histopathological Findings from Two Women who Underwent Hysterectomy

Toshimitsu Tohya\*, Yuko Imamura, Chisato Motooka, Sabro Kuwahara and Yuji Matsuo

Department of Obstetrics and Gynecology, Kumamoto Rosai Hospital, Japan

### Abstract

This article details diagnostic imaging and histopathological findings from two women with Cesarean scar syndrome (CSS) who underwent hysterectomy. Patient one, a 44-year-old woman, was examined with transvaginal ultrasound (TVUS) and magnetic resonance imaging (MRI). Characteristic histological findings included a defect of the muscle layer of her Cesarean scar. Patient two, a 39-year-old woman, experienced intermittent genital bleeding and severe anemia after undergoing a Cesarean section. The MRI examination showed a prominent Cesarean scar. Patient two underwent total abdominal hysterectomy, with histological examination of the uterus revealing a similar defect of the muscle layer annexed to the Cesarean scar tissue. TVUS examination and MRI examination were essential for diagnosis. The salient histological finding in both cases was tearing and a defect of the anterior uterine muscle layer at the border of the cervix and the endometrium.

**Keywords:** Cesarean scar; Cesarean scar syndrome; Cesarean scar pregnancy

### Introduction

Cesarean section has an extensive, storied history. Today, the procedure can be conducted safely thanks to modern advances in anesthesiology, blood infusion and the like. Correspondingly, the number of Cesarean sections has gradually increased each year because of various clinical factors. Moreover, Cesarean section offers many benefits to pregnant women and their newborn babies.

Despite advances in medical technology, Cesarean section involves risks we should highlight. Among these risks, we recently became aware of problems associated with a Cesarean section scar. Some women who have multiple children are at risk of developing a Cesarean scar pregnancy (CSP), which can result in placenta previa or placenta accreta that results in the death of the pregnant woman [1,2]. In practice, menstrual abnormalities and secondary infertility after Cesarean sections are reported often [3]. Therefore, the reproductive subcommittee of the Japan Society of Obstetrics and Gynecology recommends calling these disorders Cesarean Scar Syndrome (CSS) [3,4]. However, the numbers of histopathological reports of CSS are limited. In this paper, we report the diagnostic imaging and histopathological findings for two women, one involving a case of CSP and one involving a case of menstrual abnormality after undergoing Cesarean section, who underwent hysterectomy.

### Case Presentation

#### Case 1

Patient one was a 44-year-old woman (gravida 3, para 3) who underwent two Cesarean sections at the age of 30 and 33, respectively. She was found to be pregnant at a local clinic and was referred to our hospital after CSP was suspected. Transvaginal ultrasound (TVUS) indicated CSP (Figure 1A), which was followed by magnetic resonance imaging (MRI) to confirm the diagnosis (Figure 1B). After a discussion of therapeutic options, the patient decided to undergo a total abdominal hysterectomy. In reality, histological examination of the uterus revealed CSP. The characteristic finding was a defect of the muscle layer beneath the Cesarean scar. Decidual change was visible in the scar portion and in normal endometrium tissue. In addition, microscopic bleeding was detected in the scar area as well as the normal endometrium tissue (Figure 1C and D).

#### Case 2

Patient two was a 39-year-old woman (gravida 2, para 2) who underwent two Cesarean sections

### OPEN ACCESS

#### \*Correspondence:

Toshimitsu Tohya, Department of Obstetrics and Gynecology, Kumamoto Rosai Hospital Yatsushiro, Kumamoto 866-8533, Japan, Tel: 965-33-4151; Fax: 965-32-4405, E-mail: sanfu-tohya@kumamotoh.rofuku.go.jp

Received Date: 28 Jul 2016

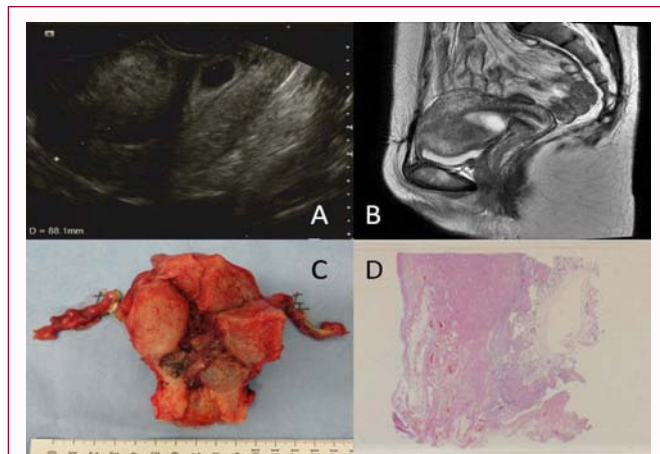
Accepted Date: 18 Aug 2016

Published Date: 01 Sep 2016

#### Citation:

Tohya T, Imamura Y, Motooka C, Kuwahara S, Matsuo Y. Cesarean Scar Syndrome: Diagnostic Imaging and Histopathological Findings from Two Women who Underwent Hysterectomy. *Ann Clin Case Rep.* 2016; 1: 1117.

**Copyright** © 2016 Tohya T. This is an open access article distributed under the Creative Commons Attribution License, which permits unrestricted use, distribution, and reproduction in any medium, provided the original work is properly cited.



**Figure 1:** (a) Transvaginal ultrasound finding indicates the gestational sac was located in the anterior wall of the cervix. The endocervical canal is clearly visible. (b) Magnetic resonance imaging shows Cesarean scar pregnancy (CSP); the gestational sac may be seen invading adjacent serosa of the uterus. (c) Macroscopic appearance of the resected uterus; the gestational sac is present in the Cesarean scar. (d) Loupe appearance of the CSP; the muscle layer of the Cesarean scar is very thin.

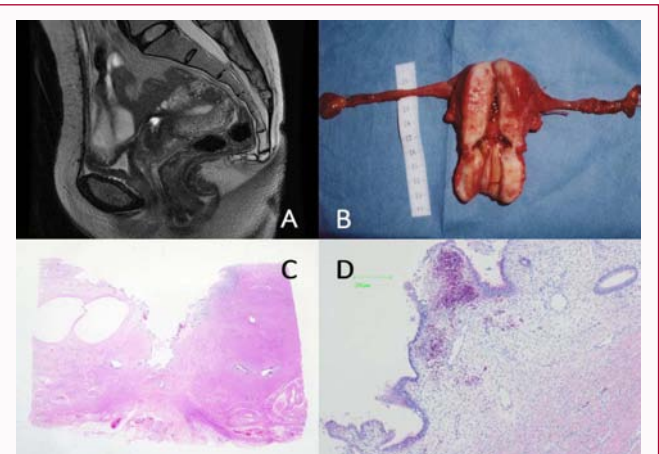
at the age of 32 and 37, respectively. After the second Cesarean section, she experienced intermittent genital bleeding. TVUS examination revealed a Cesarean scar and small intramural myoma (Figure 2A). MRI examination showed a prominent Cesarean scar (Figure 2B). This patient experienced intermittent genital bleeding and severe anemia, which prompted her to undergo total abdominal hysterectomy. Histological examination of the uterus revealed a characteristic defect of the muscle layer in the Cesarean scar portion at the border of the cervix and the endometrium (Figure 2C and D).

## Discussion

In 1995, based on pathological findings, Morris suggested some clinical disorders occur after Cesarean section [5]. Symptoms include lower abdominal pain, dyspareunia, and dysmenorrhea.

In recent years, the number of Cesarean sections has increased. Consequently, obstetricians and gynecologists have been forced to confront an increased number of patients with CSP, postmenstrual abnormal uterine bleeding, pelvic pain, or infertility. We refer to these various symptoms as CSS, all of which should be considered dangerous and possibly life-threatening [1,2]. Proper diagnosis and management of CSP are essential, both of which rely on diagnostic imaging and careful interpretation of histopathological findings.

Concerning the diagnostic imaging of CSS, TVUS and MRI are very useful. TVUS examination, in particular, is essential to properly diagnose CSP. Vial et al. [6] has proposed two different types of CSP, with the first type following implantation of the gestational sac on the Cesarean scar with progression toward either the cervico-isthmic space or the uterine cavity. This situation may lead to a viable birth, but with an increased risk of life-threatening bleeding from the site of implantation. The second type involves deep implantation in Cesarean scar tissue, which causes rupture and bleeding during the first trimester. To confirm this second type of CSP, Vial et al. [6] proposed the following ultrasound diagnosis criteria: [1] the trophoblast must be mainly located between the bladder and the



**Figure 2:** (a) Magnetic resonance imaging shows bloody fluid retention in the Cesarean scar. (b) Macroscopic appearance of the resected uterus; the Cesarean scar is prominent. (c) Loupe appearance of the Cesarean scar; the muscle layer of the Cesarean scar is very thin. (d) Histological findings of the Cesarean scar defect; some bleeding is visible in the Cesarean scar.

anterior uterine wall; [2] no fetal parts must be visible in the uterine cavity; and [3] on sagittal view of the uterus running through the gestational sac, a discontinuity in the anterior wall of the uterus should be demonstrated. In practice, our case studies showed these ultrasound features.

MRI has been used with a small number of patients as an adjunct to TVUS. However, MRI is actually indispensable for precisely identifying the relationship of CSP to adjacent structures, placenta increta or percreta, bladder invasion, and so on. Takeda et al. [7] reported that three-dimensional computed tomographic angiography is potentially useful for evaluating uteroplacental neovascularization in hemodynamically stable CSP. It can provide additional yet critical information for proper management and therapy of appropriate patients. These findings indicate a combination of TVUS and MRI is essential for diagnosis.

Very few studies of the histopathological findings associated with CSS have been conducted. To address this gap in the literature, we have discussed a case of CSP and a case of abnormal bleeding with CSS. In both cases, the characteristic finding was a tearing and defect of the anterior uterine muscle layer. Thin decidua was noted on the surface of the defective tissue. Tanimura et al. [4] published a pathological report concerning surgically extracted specimens from cases featuring Cesarean scar dehiscence. They reported that the endometrial gland or stromal tissue was identified in the deep part of the scar for 27.2% of cases. Morris [5] first reported pathological changes in the area of the post-Cesarean scar for a series of 51 hysterectomy specimens. Scar tissue contributed to significant pathological changes, including distortion and widening of the lower uterine segment (75%), overhang of congested endometrium above the scar recess (61%), polyp formation conforming to the contours of the scar recess (16%), moderate to marked lymphocytic infiltration (65%), residual suture material with foreign body giant cell reaction (92%), capillary dilatation (65%), free red blood cells in the endometrial stroma of the scar (suggesting recent hemorrhage) (59%), fragmentation and breakdown of the endometrium of the scar (37%), and iatrogenic adenomyosis confined to the scar (28%). These

findings suggest that anatomical abnormalities caused by the scar could give rise to physical symptoms such as lower abdominal pain, dyspareunia, or dysmenorrhea.

In our experience, the main abnormality associated with Cesarean section scar tissue is tearing and deformation of the anterior uterine muscle layer at the border of the cervix and the endometrium. It is likely that repair of the muscle layer after Cesarean section does not proceed normally in some patients anomalies in healing may occur, in particular, at the border of the cervix and the endometrium. Accordingly, the incision and suture methods applied to the uterine wall should be carefully considered.

## References

1. Herman A, Weinraub Z, Avrech O, Maymon R, Ron-El R, Bukovsky Y. Follow up and outcome of isthmic pregnancy located in a previous caesarean section scar. *Br J Obstet Gynecol.* 1995; 102: 839-841.
2. Yamaguchi M, Honda R, Uchino K, Tashiro H, Ohba T, Katabuchi H. Transvaginal methotrexate injection for the treatment of cesarean scar pregnancy: efficacy and subsequent fecundity. *J Minim Invasive Gynecol.* 2014; 21: 877-883.
3. Tsuji S, Murakami T, Kimura F, Tanimura S, Kudo M, Shozu M, et al. Management of secondary infertility following cesarean section: Report from the Subcommittee of the Reproductive Endocrinology Committee of the Japan Society of Obstetrics and Gynecology. *J Obstet Gynaecol Res.* 2015; 41: 1305-1312.
4. Tanimura S, Funamoto H, Hosono T, Shitano Y, Nakashima M, Ametani Y, et al. New diagnostic criteria and operative strategy for cesarean scar syndrome: Endoscopic repair for secondary infertility caused by cesarean scar defect. *J Obstet Gynaecol Res.* 2015; 41: 1363-1369.
5. Morris H. Surgical pathology of the lower uterine segment caesarean section scar: is the scar a source of clinical symptoms. *Int J Gynecol Pathol.* 1995; 14: 16-20.
6. Vial Y, Petignat P, Hohlfeld P. Pregnancy in a Caesarian scar. *Ultrasound Obstet Gynecol.* 2000; 16: 592-593.
7. Takeda A, Imoto S, Sakai K, Nakamura H. Three-dimensional computed tomographic angiography in the diagnosis and conservative management of cesarean scar pregnancy with prominent neovascularization. *Taiwan J Obstet Gynecol.* 2014; 53: 385-388.