



## When a Tongue Causes a Heart-Break: A Case Report of a Single Myocardial Metastasis from a Primary Tongue Squamous Cell Carcinoma

Kattan C<sup>1</sup>, Khoury M<sup>1\*</sup>, Chlawit R<sup>2</sup>, Abdelmassih T<sup>2</sup>, Melkane A<sup>3</sup> and Kattan J<sup>1</sup>

<sup>1</sup>Department of Hematology-Oncology, Hôtel Dieu de France University Hospital, Lebanon

<sup>2</sup>Department of Cardiology, Hôtel Dieu de France University Hospital, Lebanon

<sup>3</sup>Department of Head and Neck, Hôtel Dieu de France University Hospital, Lebanon

### Abstract

Cardiac metastasis is a rare finding. When present, it usually arises from melanoma, lung cancer, breast cancer as well as mediastinal tumors and hematologic malignancies. Head and neck tumors rarely metastasize to the heart making the encountering of such a case worth publishing to the medical society. The rarity of this finding also makes it hard for clinicians to recognize, diagnose and treat patients who present with heart metastasis.

**Keywords:** Cardiac metastasis; Head and neck cancer; Squamous cell carcinoma

### Introduction

Cardiac metastasis from head and neck tumors are an extremely rare presentation. Additionally, most cases of cardiac metastasis are diagnosed post-mortem due to the silent manifestation of this presentation [1]. Clinicians should however suspect it whenever patients with head and neck cancer exhibit cardiac signs and symptoms such as chest pain; dyspnea, palpitations, cardiac failure or EKG changes [2], although these symptoms are not specific. Multiple imaging modalities help in the diagnosis of cardiac metastasis and management depends on whether it is the only site of metastasis or a disseminated disease [1,2].

### OPEN ACCESS

#### \*Correspondence:

Makram Khoury, Department of Hematology-Oncology, Hôtel Dieu de France University Hospital, Lebanon, E-mail: makram.m.khoury@gmail.com

Received Date: 13 May 2022

Accepted Date: 07 Jun 2022

Published Date: 28 Jun 2022

#### Citation:

Kattan C, Khoury M, Chlawit R, Abdelmassih T, Melkane A, Kattan J. When a Tongue Causes a Heart-Break: A Case Report of a Single Myocardial Metastasis from a Primary Tongue Squamous Cell Carcinoma. *Ann Clin Case Rep.* 2022; 7: 2235.

ISSN: 2474-1655

Copyright © 2022 Khoury M. This is an open access article distributed under the Creative Commons Attribution License, which permits unrestricted use, distribution, and reproduction in any medium, provided the original work is properly cited.

### Case Presentation

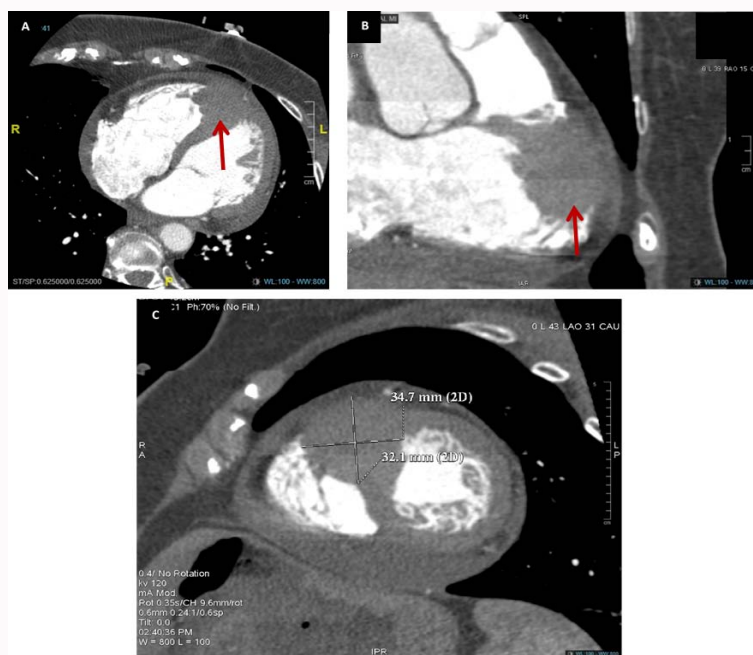
T.K. is a 64-year-old female teacher, never smoker, with a past medical history significant for T2N0M0, left infiltrative ductal breast carcinoma in 2015, for which she underwent conservative breast surgery and adjuvant radiotherapy with six cycles of docetaxel and cyclophosphamide followed by aromatase inhibitors for 5 years.

Three months after the end of adjuvant hormone therapy, she complained from painful ulceration of the left border of her tongue. A biopsy of the lesion was performed and revealed a moderately differentiated squamous cell carcinoma. A partial glossectomy with left cervical lymphadenectomy were performed in May 2021. Histology revealed a 2 cm ulcerative tumor with 15 mm depth infiltration, with lymphatic and neural emboli and vascular invasion, and with 2 positive lymph nodes involvement out of 28 resected.

She received oral and cervical irradiation with 6600 cGy during 33 sessions with concomitant cisplatin 100 mg/m<sup>2</sup> every 3 weeks for three cycles.

A follow-up PET-CT scan performed three months after the end of therapy confirmed the radiologic complete remission of the first primary of the breast as well as the second primary of the tongue. However, it showed an isolated bizarre radioactive uptake of 2.5 cm of diameter with SUV=14.5 at the apex of the right ventricle of the heart.

The cardiac ultrasound showed a hyperechogenic mass (2.4 cm × 2.1 cm) attached to the apical and lateral wall of the right ventricle causing no obstruction with evidence of tissue vascularization on the color flow Doppler. There were signs of localized pericardial invasion as shown by its increased thickness facing the mass. A cardiac angioscan found a 35 mm × 32 mm irregular mass infiltrating the myocardium at the right apex level and protruding through the ventricle cavity and through the pericardium. A multifocal pericardial thickening and thin pericardial effusion was also



**Figure 1:** Cardiac angioscan showing the tumor at the apex of the right ventricle (red arrows in A and B) and its dimensions (C).

identified (Figure 1).

In January the fourth, 2022, an open biopsy was performed *via* minimal thoracotomy. A third primary sarcoma in the field of previous breast radiotherapy was ruled out, and a confirmation of squamous cell localization of the tongue to the myocardium was done. Pericardial biopsy and pericardial liquid cytology were unremarkable.

According to our multidisciplinary team decision, the futility of surgical resection or irradiation was highlighted and the management will be restricted to systemic chemo-immunotherapy.

## Discussion

The incidence of any cardiac metastasis varies greatly between 1.23% to 18.3% [2], with substantially variable incidence depending on the primary site. According to Bussani et al. [3] postmortem cardiac metastasis occurred in 9% of patients, and of which only 5% corresponded to an oral cavity primary cancer, compared to 48.4% secondary to mesothelioma, 27.8% secondary to melanoma, and 21% to lung adenocarcinoma.

Head and neck cancers usually metastasize to the lungs, bones and liver. A cardiac metastasis is highly unusual and rare to find. A total of 34 cases of cardiac metastasis from head and neck squamous cell carcinoma were reported, including 12 cases from a tongue primary, according to the literature review by Dewan et al. [4] between 1985 and 2020.

The mechanisms underlying the occurrence of cardiac metastasis from head neck tumors is not yet fully understood but it is supposed to occur by hematogenous spread through the coronary arteries, lymphatic spread or contiguous spread through invasion of the pulmonary veins or the inferior *vena cava* [5-8].

Patients with cardiac metastasis are often asymptomatic, as the patient presented in this case report. Symptoms due to cardiac metastasis are exceedingly rare and are nonspecific and therefore most patients are diagnosed in postmortem or incidentally on routine

follow-up imaging done as surveillance for other previously diagnosed tumors. If present, symptoms include dyspnea due to pleural effusion, valvular obstruction or cardiac failure. Other symptoms include chest pain, arrhythmias, syncope, sudden death due to myocardial rupture and infarction. Rarely, pulmonary embolus due to cardiac metastasis can happen [1,4,9]. Therefore, in patients with advanced head and neck cancers presenting with new onset cardiovascular symptoms, metastatic cardiac lesion should be suspected and ruled out.

When suspected, diagnoses could be done using several methods. Cardiac echography is the easiest and least invasive procedure used to diagnose cardiac metastasis. The sensitivity of echocardiography is 80% which makes it an appropriate initial imaging method [1,2,10]. The gold standard for the diagnosis of myocardial metastasis remains the cardiac biopsy which was done in our case, however the biopsy is not often safe and doable [11]. Other helpful diagnostic testing may include electrocardiogram showing nonspecific ST-elevation changes or arrhythmias, and other imaging options such as computed tomography, PET-CT scan and magnetic resonance imaging [12]. Cardiac MRI was correspondent to the cardiac histology in 78% of the cases as compared to 51% of concordance with echocardiography. MRI provides excellent resolution and allows evaluation of the surrounding tissue [1]. PET/CT may also help in diagnosing cardiac metastasis with the additional benefit of detecting distant metastasis [8].

Management of cardiac metastasis is limited and remains a clinical challenge. When only one metastasis is present, treatment may be curative. Treatment options include surgical excision, mechanical coil embolization of the arterial supply of the mass, systemic chemotherapy, immunotherapy, chemoembolization, and radiotherapy [2,4,10,13]. In addition, some patients may require specific cardiac tailored therapy depending on the present cardiovascular-related disease, such as medical management of cardiac failure, anti-arrhythmic drugs, pacemaker placement, etc [4]. However, usually the patients are inoperable, the prognosis is fatal especially if the cardiac metastasis is part of a disseminated disease,

and the treatment aims in palliation of symptoms rather than curing the disease [4,14,15].

## Conclusion

Cardiac metastasis from head and neck squamous cell carcinoma is a rare entity and remains a challenging diagnosis. It is often asymptomatic but it should be considered in the differential diagnosis when a patient with a history of head and neck cancer presents with new onset cardiac symptoms. It has a poor prognosis when it occurs and the treatment options are limited. Therefore, it may be reasonable to considering adding routine EKG and/or echocardiography to the annual surveillance regimen for patients who have been treated for head and neck squamous cell carcinoma.

## References

1. Kim JK, Sindhu K, Bakst RL. Cardiac metastasis in a patient with head and neck cancer: A case report and review of the literature. *Case Rep Otolaryngol*. 2019;2019:9581259.
2. Tregubenko P, White S, Zvonarev V, Kumar A. Cardiac metastasis in a living patient with laryngeal squamous cell carcinoma. *Cureus*. 2021;13(7):e16214.
3. Bussani R, De-Giorgio F, Abbate A, Silvestri F. Cardiac metastases. *J Clin Pathol*. 2007;60(1):27-34.
4. Dewan K, Klug T, Ardestani A, Shires CB. Heart breaking diagnosis: Cardiac metastases from mucosal head and neck squamous cell carcinoma. Case report and review of current literature. *Otolaryngol Case Rep*. 2020;17:100248.
5. Onwuchekwa J, Banchs J. Early cardiac metastasis from squamous cell carcinoma of the tongue in 2 patients. *Tex Heart Inst J*. 2012;39(4):565-7.
6. Gullulu S, Ozdemir B, Senturk T, Baran I, Cordan J, Filiz G. Cardiac metastasis in a laryngeal carcinoma and associated electrocardiographic changes. *Otolaryngol Head Neck Surg*. 2006;135(4):645-7.
7. Suda T, Ishii A, Hukuda K, Utahashi H, Ishii M. [Cardiac metastasis by hypopharyngeal carcinoma. Case report]. *Nihon Jibiinkoka Gakkai Kaiho*. 2007;110(6):466-9.
8. Nagata S, Ota K, Nagata M, Shinohara M. Cardiac metastasis of head and neck squamous cell carcinoma. *Int J Oral Maxillofac Surg*. 2012;41(12):1458-62.
9. Malekzadeh S, Platon A, Poletti P-A. Cardiac metastasis of tongue squamous cell carcinoma complicated by pulmonary embolism: A case report. *Medicine (Baltimore)*. 2017;96(28):e7462.
10. Ghosh J, Das J, Ganguly S, Biswas B, Dabkara D. Cardiac metastasis from squamous cell carcinoma of the buccal mucosa: A case report and review of the literature. *Cancer Res Stat Treat*. 2020;3(3):617-9.
11. Pattni N, Rennie A, Hall T, Norman A. Cardiac metastasis of oral squamous cell carcinoma. *BMJ Case Rep*. 2015;2015:bcr2015211275.
12. Mark-Adjeli P, Cirrone J, Gupta R, Nawaz S. Tonsillar carcinoma as a rare cause of cardiac metastases. *J Community Hosp Intern Med Perspect*. 2019;9(6):524-8.
13. Mansour A, Riaz T, Khalaf SA, Doll D. Cardiac metastasis from head and neck carcinoma, a rare and challenging diagnosis. *J Am Coll Cardiol*. 2020;75(11\_Supplement\_1):3410.
14. Rivkin A, Meara JG, Li KK, Potter C, Wenokur R. Squamous cell metastasis from the tongue to the myocardium presenting as pericardial effusion. *Otolaryngol Neck Surg*. 1999;120(4):593-5.
15. Zemann W, Feichtinger M, Kowatsch E, Schanbacher M, Kärcher H. Cardiac metastasis after squamous cell carcinoma of the oral cavity: Case report. *Br J Oral Maxillofac Surg*. 2007;45(5):425-6.