



Unexpected Finding at 18-FDG PET-CT: Abdominal Paraganglioma

Bellamy J^{1*}, Ittah A² and Perez N¹

¹Clinique du Val d'Or, France

²Cliniques Medicales Soissons, France

Abstract

A 72 years old non smoker patient had PET-CT exploration for left lung cancer. It highlighted an unexpected sub diaphragmatic fixation. The abdominal CT scan highlighted a small size formation, hyper vascular, located at the right side of the abdominal aorta, close to the ostium of the inferior mesenteric artery. The diagnosis of paraganglioma of the Zuckerk and I body was suspected and confirmed by resection of the tumor under laparoscopy.

Keywords: Paraganglioma; PET-CT

Introduction

A 72 years old female patient presented with chest pain. She described having long lasting been treated for hypertension controlled by beta blockers and thiazidic diuretics. She had never smoked. At physical examination the patient was normotensive. She reported experiencing peri-umbilical intermittent pain for three months, more and more frequent, but this was not the reason why she had consulted her doctor. Chest and abdominal examination were normal.

The chest x-ray showed two opacities of the left lung: the one apical, paramediastinal; the other next to the hilum. A computed tomography (CT) disclosed the images in the form of two opacities of tissue density, very suggestive of malignancy, located one in the apex of the upper lobe, the other in the lower lobe: (Figure 1). There was no visible hilar or mediastinal lymph node enlargement. The right lung was normal. The bronchial fibroscopy was normal, bronchial biopsies were negative. CT-scan controlled fine-needle aspiration of the inferior lobar lesion disclosed the diagnosis of adenocarcinoma. Routine laboratory findings were normal

Therefore it was concluded the diagnosis of bifocal bronchial carcinoma; surgical treatment was advocated for that tumor classified T4N0, as the patient was in good general condition, with good respiratory tests, authorizing a pneumonectomy. In order to check the extension of the tumoral process, magnetic resonance (MRI) brain imaging was done and was normal; a 18 fluoro-deoxy glucose positron emission (PET-CT) revealed an uptake of both pulmonary opacities; no uptake of the mediastinal lymph nodes. An isolated uptake of tracer at the abdominal level, on the median line, between the aorta and the inferior vena cava, at the level of the spinal disc L3 - L4 (Figure 2-4) was discovered.

Contrast material-enhanced helical CT of the abdomen was performed to document this unexpected uptake of the tracer: it demonstrated a soft-tissue mass 6*10 mm. Despite the small size, intense density enhancement after contrast material injection was unmistakable. The mass was located between the abdominal aorta and inferior vena cava, close to of the ostium of the inferior mesenteric artery, well distinguishable from surrounding tissues, notably the aorta. (Figure 5 and 6). It also demonstrated the presence of biliary cyst in the right liver, normal adrenal glands, an intense contrast enhancement of the anterior pole of the spleen, which had no PET- CT correspondence. No Magnetic resonance imaging of the abdomen was deemed necessary.

Diagnosis

At the end of these investigations, the diagnosis of abdominal lymph node metastasis of lung cancer seemed unwise due to the situation of the process very remote from the lung, the absence of any intermediate abnormal lymph node, intense enhancement after contrast injection proving a highly vascular tissue. A benign tumor was suspected, and between other hypotheses the diagnosis of a paraganglioma was offered, but this diagnosis seemed to lack of evidence, as

OPEN ACCESS

*Correspondence:

Jean Bellamy, Clinique du Val d'Or,
14-16 Rue Pasteur, 92210 Saint-Cloud,
France, Tel: 01 47 11 79 97;
E-mail: j-bellamy@wanadoo.fr

Received Date: 01 Jul 2016

Accepted Date: 02 Aug 2016

Published Date: 07 Aug 2016

Citation:

Bellamy J, Ittah A, Perez N. Unexpected
Finding at 18-FDG PET-CT: Abdominal
Paraganglioma. *Ann Clin Case Rep.*
2016; 1: 1071.

Copyright © 2016 Bellamy J. This is
an open access article distributed under
the Creative Commons Attribution
License, which permits unrestricted
use, distribution, and reproduction in
any medium, provided the original work
is properly cited.

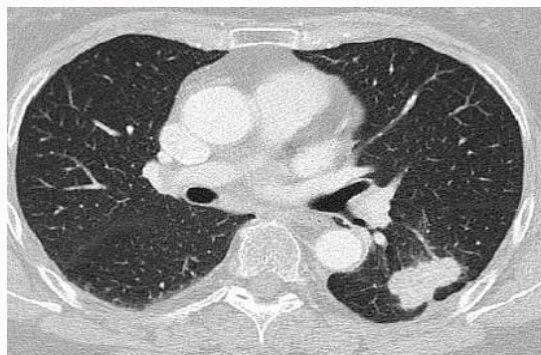

Figure 1: CT scan of the lung: tumoral mass of the lower lobe of the left lung.

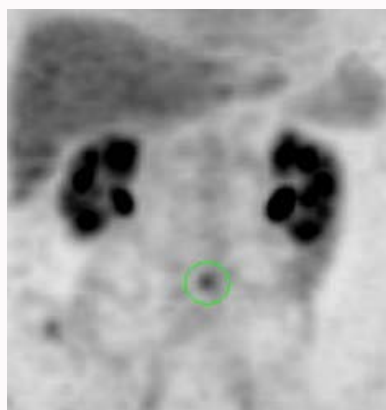


Figure 2: PET-FDG: abdominal uptake of the tracer.

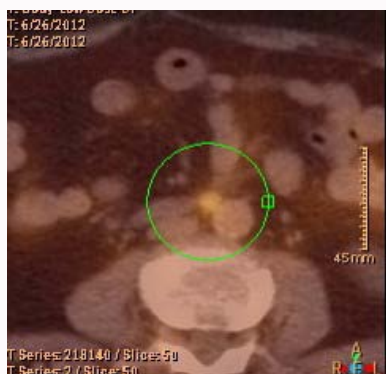

Figure 3: Abdominal uptake is located between aorta and vena cava.



Figure 4: abdominal uptake is just upper the aorta bifurcation.

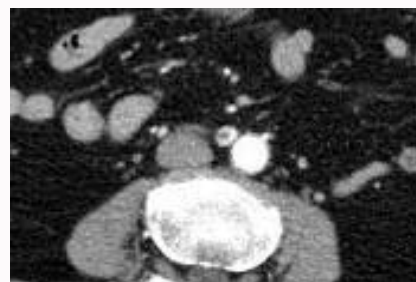


Figure 5: The abdominal mass is well defined, has no adhesion, and is located at the level of the ostium of the inferior mesenteric artery. Intense enhancement of density after contrast injection.

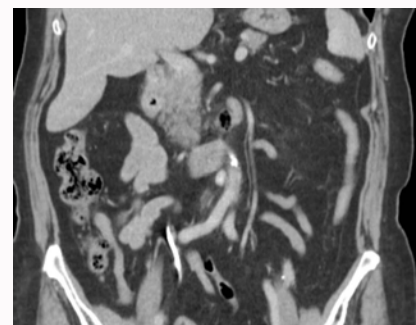


Figure 6: The abdominal mass is located at the right side of the aorta.

abdominal paragangliomas are very rare, and so no blood or urinary metabolites of catecholamine assay were done. In order to document the nature of the mass, a histological control was proposed and the patient underwent surgery by laparoscopy: lymphadenectomy of the inter aorto-caval area was performed. A small nodular formation was easily seen and easily removed.

Microscopic examination disclosed a 8mm formation with endocrine structure, with thick sheets and trabeculae separated by fibrous septa. Cells had a granular and eosinophilic cytoplasm, a pleomorphic nucleus with numerous nucleoles and few mitoses. Peripheric to the nodules were found sustentacular cells. There was no focus of necrosis. The capsules of the tumor were thick and no embolus was noted. Immunoperoxidase stains were strongly positive for chromogranin on tumoral cells, while sustentacular cells were

positive with protein S 100. These findings substantiated the diagnosis of paraganglioma. No particular elevation or drop of arterial pressure was noted during or after the operation.

The recovery from this intervention was uneventful. The patient reported the disappearance of abdominal pain that she previously experienced. The diagnosis of metastatic lymphadenopathy being set aside, lung surgery was considered and the patient was operated two weeks later and had left pneumonectomy with mediastinal lymphadenectomy; one mediastinal node was metastatic. As the tumor was now classified Grade III B (T4N2), adjuvant platinum-based chemotherapy was offered. The prognosis of the bronchial tumor itself seemed poor, so the risk of tumoral recurrence of the paraganglioma was not considered and no specific supervision was proposed neither genetic study for the patient or her family. The patient died two years later of tumoral progression of the bronchial carcinoma.

Discussion

It therefore was a paraganglioma of the corpuscle of Zuckerkandl.

Paragangliomas are rare neuroendocrine tumours (approximately 1 case on 1 000 000) similar to the pheochromocytomas of the adrenal glands. They are developed from extra adrenal paraganglionic cells of the chromaffin tissue, which explains their locations at the level of the normal locations of chromaffin tissue. Head and neck paragangliomas are of parasympathetic type, and non-secreting: they are found near the carotid bifurcation, where is the carotid body; near the temporal bone and at the level of the larynx and rarely upper trachea [1].

In the mediastinum the aorto-pulmonary window paragangliomas are developed at the expense of the aortic body. They are sympathetic type paragangliomas, as are abdominal paragangliomas. These include the paragangliomas of Zuckerkandl body, infradiaphragmatic paraaortic other than from the Zuckerkandl body, and paragangliomas of the bladder.

Histological examination proves the diagnosis of paraganglioma: microscopic examination reveals sheets and trabeculae of polygonal cells with abundant granular, eosinophilic cytoplasm. The tumor shows prominent vascularity. Neoplastic cells are positive for CD 56, synaptophysin and chromogranin, and there are focal S-100 protein positivity in sustentacular cells. Histology does not predict benignity or malignancy: malignancy can be proved only by the initial discovery or the subsequent occurrence of distant metastases, as malignant paragangliomas lack histological or molecular markers that distinguish them from benign ones. Tumor size does not seem neither to be a prognostic factor. Ayala-Ramirez [2] reports 66% of metastatic evolution. The genetic study done on the patients highlights in 10-50 % of cases inactivating germline mutations of the B and D subunits of the mitochondrial succinate dehydrogenase [3]. This is a mutation of autosomal dominant character but incomplete penetrance, which explains that the absence of other cases in the family does not eliminate the familial nature of the disease. Ayala-Ramirez [2] claims that there is a strong correlation between the presence of mutation and malignancy. Other familial diseases can be associated: Multiple Endocrine Neoplasia (MEN type 2); Von Hippel-Lindau disease; Neurofibromatosis; hereditary pheochromocytoma.

Location

The corpuscle of Zuckerkandl, described by Zuckerkandl in 1901, is located at the right edge of the abdominal aorta, between the origin of the inferior mesenteric artery and the aortic bifurcation. It is present in the fetus and remnants can be found in the para aortic plexus in the adult. It is a site of development of paragangliomas: Lodish [4] in 2010 listed 135 cases.

Diagnosis

The clinical signs of Zuckerkandl body paraganglioma are on the one hand, if the tumor is secretant, signs which are common to secreting paragangliomas and are related to excess catecholamine secretion: discomfort with bouts of pallor and tachycardia, headache, paroxysmal hypertension; on the other hand intermittent abdominal pain. As most abdominal and thoracic paragangliomas hypersecrete epinephrine and/or dopamine, biological tests that allow the positive diagnosis of paraganglioma are measurements of plasma and/or urine concentrations of epinephrine and norepinephrine, and their metabolites metanephrine and normetanephrine. However, a large number of paragangliomas are non-secretant. Imaging studies confirm the presence of an abnormal formation located anterior to the abdominal aorta, between the inferior mesenteric artery ostium and the aortic bifurcation. On CT scan there is a strong enhancement

of the lesion after injection of iodine proving the highly vascular nature of the lesion. In MRI there is a hyper-intense signal in T2. CT scan and MRI will also allow checking the local extent of the tumor, which can include invasion of local blood vessels and surrounding tissues [5].

Angiography is rarely requested except in order to achieve a procedure of preoperative embolization. Functional imaging allows localizing the tumor each time the biochemical diagnosis has been established, by using agents that specifically target the catecholamine metabolism. It includes scintigraphy with MIBG (octreoscan), which specifically targets the catecholamine synthesis, but has about 10% false-negative rate. PET-CT may be performed with 18-Fluorodihydroxyphenylalanine and 18-Fluorodopamine. Actually, PET CT with 18 - Fluorodeoxyglucose allows locating the tumor and possible metastases and seems to be the most efficient functional imaging technique [3]. As this imaging is now widely used, much more than MIBG, it is much easier to implement.

Treatment

Treatment involves surgical excision as often as possible: eventually by laparoscopy [6] as we did but usually by laparotomy because these are most often large tumors, which may have developed hyper vascularized adhesions to the aorta, vena cava or other surrounding tissues which can even be invaded, leading to major vascular resections.

Monitoring and prognosis

Only the initial finding of metastases or their subsequent occurrence proves malignancy. Evolution is slow and eventual metastases may be accessible to surgical resection, which justifies long-lasting monitoring, preferably by annual plasma or urine measurement of metanephrines and MRI of the abdomen. A genetic study is desirable for all patients, to search a mutation in the gene of the SDH. Given the possibility of somatic mutations with variable penetrance, the interest of family screening is controversial.

Peculiarities of this case

The tumour was discovered fortuitously during a PET-CT aimed to exploration of a bifocal bronchial cancer. Kahraman [7] claims that up to 10% of paragangliomas and pheochromocytomas are discovered incidentally.

Of course an abdominal lymph node metastasis was suspected but this diagnosis seemed unlikely, given its unusual location, and the absence of any other node location. The scanner noted the well limited nature of the lesion and the intensity of enhancement after injection of iodine which indicated a hypervascularization very unusual among lymph node metastases. We know for a long time that other tissues than malignant tumors capture 18-Fluorodeoxyglucose and those false positives of PET-CT are common: this includes infectious (tuberculosis in particular) and inflammatory (post-radiation pneumonitis) processes. Sarcoidosis, granulomatous processes like silicosis give mediastinal nodes images too frequently interpreted as metastatic. Some benign tumors as schwannomas are also the cause of false positive images. In the present case, and as it has been said, we cannot confidently speak of a benign tumor but anyway it was not a metastasis of the lung cancer.

Before surgery the diagnosis of paraganglioma had only been mentioned; one did not dare set it with certainty due to the exceptional nature of this pathology; and for this reason no bioassay had been

achieved which can be regreated. However and retrospectively, one can say that, given the intense vascularization of the lesion and its metabolic activity, its anatomical location in the exact spot where anatomists describe the corpuscle of Zuckerkandl, that no other diagnosis was possible. One often hesitates to make an exceptional diagnosis on clinical and radiological data only: the case that we have described proves that one should not hesitate if there are serious reasons to do so.

Conclusion

PET-CT examinations required for evaluation of a cancer or for monitoring of evolution often reveal outbreaks of fixation of the tracer without relation to the tumor, whether physiological or pathological. Therefore any fixation of the tracer of unexpected setting, whose existence and location are inconsistent with the tumoral extension, should be interpreted keeping in mind this possibility.

References

1. Bellamy J, Jean T, Bendjaballah F. [A further case of tracheal paraganglioma]. *Rev Mal Respir*. 1999; 16: 1143-1146.
2. Ayala-Ramirez M, Feng L, Johnson MM, Ejaz Sh, Habra MA, Rich T, et al. Clinical risk factors for malignancy and overall survival in patients with pheochromocytomas and sympathetic paragangliomas: primary tumor size and primary tumor location as prognostic indicators. *J Clin Endocrinol Metab*. 2011; 96: 717-725.
3. Timmers HJ, Gimenez-Roqueplo AP, Mannelli M, Pacak K. Clinical aspects of SDHx-related pheochromocytoma and paraganglioma. *Endocr Relat Cancer*. 2009; 16: 391-400.
4. Lodish MB, Adams KT, Huynh TT, Prodanov T, Ling A, Chen C, et al. Succinate dehydrogenase gene mutations are strongly associated with paraganglioma of the organ of Zuckerkandl. *Endocr Relat Cancer*. 2010; 17: 581-588.
5. Blin V, Picquet J, Enon B, Rohmer V. [Secreting paraganglioma of the organ of Zuckerkandl. A case report]. *J Mal Vasc*. 2002; 27: 239-242.
6. Thapar PM, Dalvi AN, Kamble RS, Vijaykumar V, Shah NS, Menon PS. Laparoscopic transmesocolic excision of paraganglioma in the organ of Zuckerkandl. *J Laparoendosc Adv Surg Tech A*. 2006; 16: 620-622.
7. Kahraman D, Goretzki PE, Szangolies M, Schade H, Schmidt M, Kobe C. Extra-adrenal pheochromocytoma in the organ of Zuckerkandl: diagnosis and treatment strategies. *Exp Clin Endocrinol Diabetes*. 2011; 119: 436-439.