



Triple Anterior Chamber after Deep Anterior Lamellar Keratoplasty

Banu Torun Acar* and Suphi Acar

Department of Ophthalmology, Bati Göz Hospital, Turkey

Abstract

Aim: To report a case of triple anterior chamber (TAC) development and treatment after deep anterior lamellar keratoplasty (DALK).

Case Reports: A 30-year-old male with granular dystrophy underwent DALK using lamellar dissection in his right eye. Microperforation occurred during surgery. Viscoelastic was injected into the anterior chamber to create sufficient tonus. Air was injected into the anterior chamber at the end of the operation. Post-operative day one, TAC was observed by biomicroscopy and OCT. We suspected a viscoelastic leftover at the interface. Then, sutures were removed, the space between the graft and recipient bed washed, and re-sutured. The detachment was resolved, and a relieved Descemet's membrane was demonstrated by OCT.

Conclusions: Triple anterior chamber treatment due to the leakage of viscoelastic through micro perforation cannot be taken in control with air/gas injection. The surgical intervention is unconditionally necessary because the viscoelastic must be completely removed by irrigating.

Keywords: Deep anterior lamellar keratoplasty; Descemet's membrane; Optical coherence tomography; Triple anterior chamber

Introduction

Over the last few years, deep anterior lamellar keratoplasty (DALK) has been highly preferable in cornea pathologies where the endothelium is healthy [1]. It has several advantages when compared to penetrating keratoplasty (PK). Since DALK is an extraocular surgery, the risk of intraocular complications such as endophthalmitis, iris/lens damage, and expulsive hemorrhage are quite low [2]. The loss of endothelial cells during DALK is minimized, and endothelial rejection is eliminated [1,3]. Nevertheless, DALK is a technique that the learning process is longer and more difficult to be performed, moreover it is technically more challenging compared to PK [2,3]. One of the most common complications in DALK is Descemet's membrane perforation. Due to the extra space between the graft and the recipient bed, which is a result of Descemet's membrane perforation, a double anterior chamber may develop [1]. Although a double anterior chamber is generally stated that it is withdrawn spontaneously, the anterior chamber occasionally requires the injection of air [1]. Nevertheless, there could be some cases in which the residual of stroma on recipient bed can be observed and the microperforation upsurges as result of failing in the occurrence of big bubble. In other words, in failure of big bubble developing circumstances, the big bubble cannot contact to the Descemet's membrane and it causes two additional spaces which are called as "Triple Anterior Chamber". In practice, those spaces can be explicitly determined by using Optical Coherence Tomography (OCT).

In 2002, Anwar and Teichmann [4] defined the "big bubble technique", which is generated by injecting air into the corneal stroma after partial trepanation. This technique enables the separation of Descemet's membrane from the stroma with low level risk of perforation.

We report a patient having a developed triple anterior chamber following Descemet's membrane perforation after deep anterior lamellar keratoplasty.

Case Presentation

A 30-year-old male had bilateral granular dystrophy. The best corrected visual acuity (BCVA) of him was 20/200 in the right eye and 20/100 in the left eye. DALK was performed on his right eye under sub-Tenon's anesthesia (by B.T.A). The trephination was performed by including 60-80 % of the corneal thickness to reach the deep lamellar tissue by using a Hessburg-Barron vacuum trephine

OPEN ACCESS

*Correspondence:

Banu Torun Acar, Department of Ophthalmology, Bati Göz Hospital, Kavaklı sok. Menekşe ap. N0.22 D.14 Caddebostan/Istanbul, Turkey, Tel: +90 532 4815516;

E-mail: torunbanu@yahoo.com

Received Date: 04 Aug 2016

Accepted Date: 19 Aug 2016

Published Date: 25 Aug 2016

Citation:

Acar BT, Acar S. Triple Anterior Chamber after Deep Anterior Lamellar Keratoplasty. *Ann Clin Case Rep.* 2016; 1: 1103.

Copyright © 2016 Acar BT. This is an open access article distributed under the Creative Commons Attribution License, which permits unrestricted use, distribution, and reproduction in any medium, provided the original work is properly cited.



Figure 1: Postoperative first day slit lamp biomicroscopy findings, edema in the graft and extra spaces separated with membranous tissue forming triple anterior chamber.

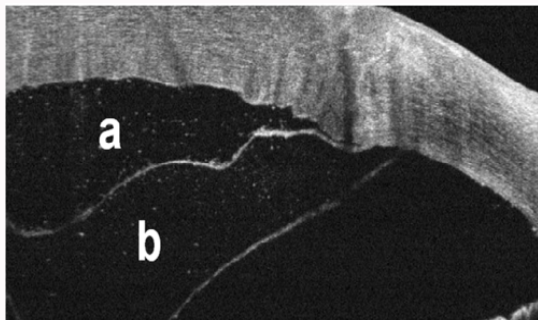


Figure 2: Postoperative first day OCT documentation of the extra spaces forming a triple anterior chamber.

A: First extra space (viscoelastic between the graft and the recipient bed).
B: Second extra space (humor aqueous between the recipient bed and Descemet's membrane).

(Jedmed Instrument Co., England). A 30 G needle was connected to a 5-ml plastic syringe filled with air, and advanced 3-4 mm from the site of incision to the center of the corneal stroma. Assuming a posterior position of that Descemet's membrane, air was injected to create a big bubble. The operation continued with lamellar dissection, as we were unable to form the bubble. The stromal tissue was dissected from the Descemet's membrane by using a blunt iris spatula. Some of the stroma left on the recipient bed. The detached stroma was cut by using blunt-tipped Vanna's scissors, however a Descemet's membrane perforation was observed at the inferior. Viscoelastic (Healon, Pharmacia and Upjohn, Peapack, N.J., USA) was injected from the site of paracentesis into the anterior chamber in order to create sufficient tonus thereby the remaining tissue was completely removed. Descemet's membrane and the endothelium of the donor cornea were removed by using a fine-tipped tying forceps; thereafter by using a Baron vacuum donor punch (Katena Products Inc., USA) trephination was performed to achieve a graft 0.5 mm larger than the recipient bed and it was sutured the cornea to the recipient bed using 10-0 nylon sutures. Viscoelastic was drained from the site of paracentesis, and the operation was completed by injecting air into the anterior chamber.

On the first post-operative day, slit-lamp biomicroscopy revealed an edematous graft and extra spaces separated by membranous tissue, which formed a triple anterior chamber (Figure 1). An extra space was observed between the graft and the host tissue; a membranous tissue formed another extra space posterior to the recipient bed. The extra spaces were examined in detail using optical coherence tomography (OCT) (Optovue, Inc., Fremont, CA, USA) (Figure 2).

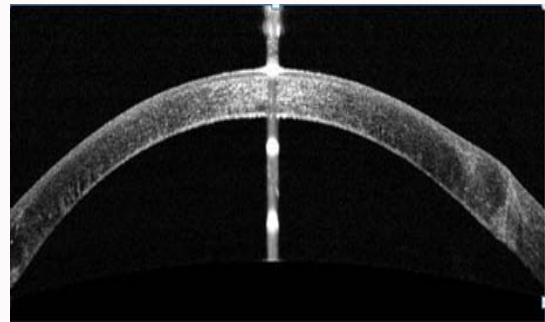


Figure 3: OCT documentation after treatment, extra spaces have been resolved.

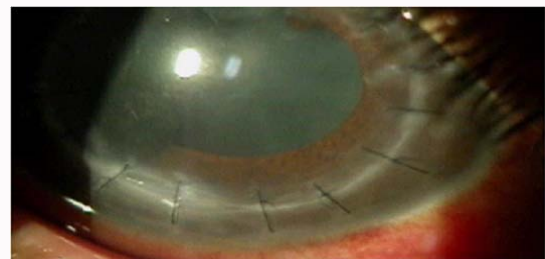


Figure 4: Slit lamp biomicroscopic image of right eye six months after surgery.

It was assumed that the viscoelastic given to the anterior chamber during the operation accumulated in the area between the graft and the recipient residual stroma due to microperforation, which in turn caused the formation of the first extra space (Figure 2). On the other hand, it was believed that the second space formed between the residual stroma on recipient bed and the Descemet's membrane of the recipient was a result of Descemet's membrane detachment (Figure 2). A period of time was given for the extra spaces to resolve spontaneously before proceeding with surgical intervention. It was thought that, the air in the anterior chamber could resolve the triple anterior chamber. However, there was no improvement until post-operative day seven; therefore, an additional operation was scheduled accordingly. Five sutures between the 10 o'clock and 2 o'clock position were removed. The interface between the graft and the recipient were irrigated with a sufficient volume of liquid, and the viscoelastic displacement was observed. Five single sutures were replaced. The anterior chamber was formed and an air tamponade was performed to fill the anterior chamber completely. Although air was observed in the upper anterior chamber on 24th hour post-operatively, the extra spaces were not visible in slit-lamp biomicroscopy. The air was fully absorbed on post-operative day three, and by using OCT, we observed that all spaces were lost, and the apposition between the graft and the recipient bed was maintained (Figure 3). A decrease in the corneal edema was observed in the follow-ups. The graft was completely clear on the third month after DALK meanwhile the patient's CVA increased to 20/40. Six months after the operation, the patient had 2592 cells/mm². The slit lamp biomicroscopy image at post-operative month six is presented in (Figure 4).

Discussion

DALK is a highly reliable and effective technique in cornea pathologies where the endothelium is healthy. DALK has a number of advantages compared to PK some of which are earlier patient rehabilitation, minimum risk of graft rejection, and less intraoperative

and postoperative complications [1-4].

Although various surgical techniques are practiced for DALK, one of the most frequent complications is Descemet's membrane perforation that occurs during deep stromal layer dissection [1,4]. Descemet's membrane detachment following perforation results in a double anterior chamber in the postoperative period. Some patients are prone to Descemet's membrane detachment due to weak adhesion between the stroma and the Descemet's membrane [5]. It was stated that weak adhesion resulted from mutated TGF-B1 gene dysfunction [6]. In addition, it was reported that during surgery with the viscodissection technique, which is one of the DALK techniques, viscoelastic was sequestered among non-dissected layers of the receptive cornea or between Descemet's membrane and the stroma [7]. Sugita et al. [1] clarified that during surgery, microperforation developed due to stromal opacification in 47 eyes out of 120 in which DALK was performed; Descemet's membrane detachment or double anterior chamber occurred only in 14 of those cases. These cases were treated by injecting air into the anterior chamber or draining the aqueous space.

In our case, the surgery was started to perform big bubble technique however continued with lamellar dissection. Descemet's membrane perforation occurred during the surgery and continued by injecting viscoelastic into the anterior chamber. Why did a triple anterior chamber occur in this case, while a double anterior chamber is generally observed in cases where microperforation develops? The reason is that the viscoelastic which was injected into the anterior chamber leaked from the perforation site and spread to the space between the graft and the recipient residual stroma and the first extra space is achieved accordingly. An additional space occurred between the recipient residual stroma and Descemet's membrane of the recipient as a result of microperforation.

In the literature, it is stated that Descemet's membrane detachment usually regresses spontaneously [8-10]. Hirano et al. [6] reported that in their case that Descemet's membrane detachment recovered spontaneously during the first week, and the extra space between the graft and the recipient bed recovered spontaneously on the third week.

On the other hand, repairing Descemet's membrane detachment in the early stage is claimed to provide a better reposition [10,11]. The practice of different methods to relieve Descemet's membrane detachment is still debated. A rolled Descemet's membrane can be opened by injecting viscoelastic, thereafter saline replacement follows, and finally the gas injection process is applied [12]. Ellis and Cohen [13] used intracameral SF₆ to resolve the Descemet's membrane detachment, while Mannan et al. [14] used intracameral C₃F₈ gas, due to its long-lasting effect.

In our case, we believed that we would be unable to resolve the Descemet's membrane detachment with only intracameral gas injection, due to the presence of the viscoelastic between the graft and the recipient bed. Thus, the interface was irrigated at first, and then injected with intracameral air. During postoperative follow-ups, we observed that the extra spaces disappeared thoroughly and the air inside the anterior chamber was resorbed. Bhojvani et al. [7]

stated that in complications following DALK with the viscodissection technique, viscoelastic inside the interface would not be resolved spontaneously and irrigation is necessary for treatment.

Despite the complication, the patient's BCVA increased to 20/40 in the post-operative sixth month, and there was no significant decrease in the number of endothelium. DALK is a successful technique that yields good results, as long as the complications that occur during the operation are treated accordingly. In conclusion, there is a need for an urgent second surgical intervention instead of waiting for the spontaneous resolution of Descemet's membrane detachment.

References

1. Sugita J, Kondo J. Deep anterior lamellar keratoplasty with complete removal of pathological stroma for vision improvement. *Br J Ophthalmol.* 1997; 81: 184-188.
2. Panda A, Singh BLM, Ray M, Singh JP, Kumar A. Deep lamellar keratoplasty versus penetrating keratoplasty for corneal lesions. *Cornea.* 1999; 18: 172-175.
3. Shimazaki J, Shimmura S, Ishioka M, Tsubota K. Randomized clinical trial of deep anterior lamellar keratoplasty versus penetrating keratoplasty. *Am J Ophthalmol.* 2002; 134: 159-165.
4. Anwar M, Teichmann KD. Big-bubble technique to bare Descemet's membrane in anterior lamellar keratoplasty. *J Cataract Refract Surg.* 2002; 28: 398-403.
5. Kansal S, Sugar J. Consecutive Descemet's membrane detachment after successive phacoemulsification. *Cornea.* 2001; 20: 670-671.
6. Hirano K, Kojima T, Nakamura M, Hotta Y. Triple anterior chamber after full-thickness lamellar keratoplasty for lattice corneal dystrophy. *Cornea.* 2001; 20: 530-533.
7. Bhojwani RD, Noble B, Chakrabarty AK, Aruna K, FRC Path, Stewart et al. Sequestered viscoelastic after deep lamellar keratoplasty using viscodissection. *Cornea.* 2003; 22: 371-373.
8. Assia EI, Levkovich-Verbin H, Blumenthal M. Management of Descemet's membrane detachment. *J Cataract Refract Surg.* 1995; 21: 714-717.
9. Minkovitz JB, Schrenk LC, Pepose JS. Spontaneous resolution of an extensive detachment of Descemet's membrane following phacoemulsification. *Arch Ophthalmol.* 1994; 112: 551-552.
10. Iradier MT, Moreno E, Aranguiz C, Cuevas J, García Feijoo J, Garcia Sanchez J. Late spontaneous resolution of a massive detachment of Descemet's membrane after phacoemulsification. *J Cataract Refract Surg.* 2002; 28: 1071-1073.
11. Walland MJ, Stevens JD, Steele AD. Repair of Descemet's membrane detachment after intraocular surgery. *J Cataract Refract Surg.* 1995; 21: 250-253.
12. Kremer I, Stiebel H, Yassur Y, Weinberger D. Sulfur hexafluoride injection for Descemet's membrane detachment in cataract surgery. *J Cataract Refract Surg.* 1997; 23: 1449-1453.
13. Ellis DR, Cohen KL. Sulfur hexafluoride gas in the repair of Descemet's membrane detachment. *Cornea.* 1995; 14: 436-437.
14. Mannan R, Jhanji V, Sharma N, Titiyal Jeewan S, Vajpayee Rasik B. Intracameral C₃F₈ injection for Descemet membrane detachment after phacoemulsification in deep anterior lamellar keratoplasty. *Cornea.* 2007; 26: 636-638.