



Thyroid Abscess

Alaqeab E, Elghobashy M*, Matin A and Almanassra A

Department of ENT and Head and Neck, University Hospital Limerick, co. limerick, Ireland

Abstract

The thyroid gland is inherently resistant to infection due to its abundant lymphatic drainage, dual blood supply, encapsulation and high iodine concentration.

Suppurative thyroiditis is an uncommon type of thyroiditis, including thyroid abscess, accounts for only 0.7% to 1% of all thyroid diseases.

Staphylococcus aureus is the most frequently isolated organism. Streptococcus, pneumococcus, salmonella, klebsiella and rarely mycobacterium, are examples of bacteria that are involved in many AST.

A 42-year-old healthy female with 3 days history of fever and painful anterior neck swelling associated with odynophagia with no history of neck trauma.

Examination showed anterior neck swelling in thyroid region, firm and tender and erythema over the overlying skin. No clinical lymphadenopathy was detected. Throat examination with fiberscope was normal. White blood cell count was high with neutrophilia, increased erythrocyte sedimentation rate (ESR) and C-reactive protein (CRP).

Ultrasonography thyroid showed enlarged right thyroid lobe with 2cm hypoechoic nodule. Antibiotics (ceftriaxone, flucloxacillin intravenous and clindamycin tablets), propranolol tablets, recommended by endocrinologist, dexamethasone intravenous.

By day 10 after improvement on antibiotics, unexpectedly the patient became febrile clinically ill, with rapid progression of a growing mass on the right side of her neck and high WBCs and high CRP. The computed tomography with contrast showed a notable enlargement of the right thyroid lobe with abscess formation.

Under general anaesthesia, 30 ml of pus was drained. Streptococcus constellatus (milleri) was isolated that showed resistance to clindamycin and sensitivity to penicillin. Meropenem intravenous was applied according to microbiologist consultation for two weeks. 6 weeks follow up showed Interval ultrasonic resolution of the right thyroid abscess, no pathological nodule was detected, with normal thyroid function test.

OPEN ACCESS

*Correspondence:

Mohamed Elghobashy, Department of ENT and Head and Neck, University Hospital Limerick, co. limerick, Ireland, Tel: 0894927885;

E-mail: drghobashy1990@gmail.com

Received Date: 01 Sep 2025

Accepted Date: 16 Sep 2025

Published Date: 17 Sep 2025

Citation:

Alaqeab E, Elghobashy M, Matin A, Almanassra A. Thyroid Abscess. Ann Clin Case Rep. 2025; 10: 2770.

ISSN: 2474-1655.

Copyright © 2025 Mohamed

Elghobashy. This is an open access article distributed under the Creative Commons Attribution License, which permits unrestricted use, distribution, and reproduction in any medium, provided the original work is properly cited.

Introduction

- The thyroid gland is inherently resistant to infection due to its abundant lymphatic drainage, dual blood supply, encapsulation and high iodine concentration.
- Suppurative thyroiditis is an uncommon type of thyroiditis. Suppurative thyroiditis, including thyroid abscess, accounts for only 0.7% to 1% of all thyroid diseases.
- Staphylococcus aureus is the most frequently isolated organism. Streptococcus, pneumococcus, salmonella, klebsiella and rarely mycobacterium, are examples of bacteria that are involved in many AST.
- Symptoms of acute thyroiditis can typically include fever, pain in the neck, and painful neck lump.
- Combination of clinical findings and diagnostic imaging is used to confirm the diagnosis and the ultrasound is the first diagnostic investigation of choice.
- Mortality rate of acute suppurative thyroiditis is 3.7%-9%
- AST management includes antibiotics, needle aspiration, incision and drainage partial or total thyroidectomy.
- AST could be complicated with thyroid abscess, sepsis, mediastinitis, airway compression

and thyroid dysfunction.

Case Presentation

- A 42-year-old healthy female with 3 days history of fever and painful anterior neck swelling associated with odynophagia.
- No history of neck trauma.
- There were no signs or symptoms of airway compression.
- Clinically she was febrile with temperature (38.7°C), BP (120/70 mmHg), PR (90) beat /min and o₂ saturation (98) % on room air.
- Anterior neck swelling in thyroid region, firm and tender and erythema over the overlying skin.
- No clinical lymphadenopathy was detected
- Throat examination with fiberscope was normal.
- White blood cell (WBC) counts 18 with neutrophilia, increased erythrocyte sedimentation rate (ESR) 55, and C-reactive protein (CRP)120.
- Ultrasonography thyroid showed enlarged thyroid lobe with 2cm hypoechoic nodule mimics AST.
- Antibiotics (ceftriaxone 2g every 12 hours, flucloxacillin intravenous 2g every 6 hours and clindamycin 600mg po every 6hours), a. tablet propranolol 10mg, recommended by endocrinologist, 12 hourly, dexamethasone 8mg mg IV 8 hourly Figure 1.
- By day **10 after** improvement on antibiotics, unexpectedly the patient became febrile clinically ill, with rapid progression of a growing mass on the right side of her neck and high WBC and high CRP,
- The computed tomography with contrast showed a notable enlargement of the right thyroid lobe with abscess (5,6 cm*5 cm*6.9 cm).
- Under general anaesthesia. **30 ml** of pus was drained **streptococcus constellatus** (milleri) was isolated that showed resistance to clindamycin and sensitivity to penicillin.
- Meropenem 2g iv 12 hourly according to microbiologist consultation **for two weeks.**
- **6 weeks follow up showed Interval ultrasonic resolution of the right thyroid abscess, no pathological nodule was detected, with normal thyroid function test Figure 2A and B.**

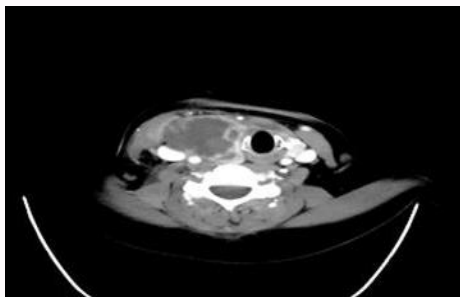


Figure 1: CT neck with contrast with enlarged right thyroid lobe and 5 cm abscess.

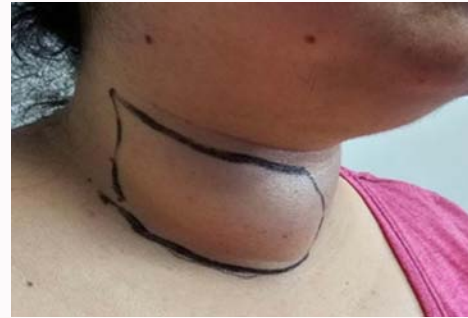

Figure 2A: Day 3, of presentation.

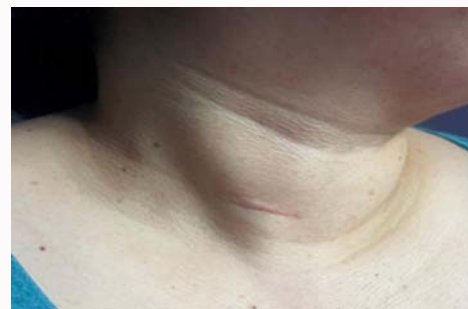

Figure 2B: Week 8, post incision and drainage.

Discussion

- Acute suppurative thyroiditis (AST) is a rare and fatal emergency thyroid disease that can lead to abscess formation as a secondary disease.
- Very unlikely in immunocompetent.
- The majority of affected patients are under 40 years old, with a slight predominance of women. The age of the index patient is the same as the usual age of presentation of this condition.
- Pre-existing thyroid diseases such as Hashimoto's thyroiditis or thyroid malignancy.
- Pyriform sinus fistula is at increased risk of acquiring AST.
- Pyriform fistula is very unlikely in this reported case for which is commonly in left side and no history of recurrence.
- The reported case is considered as de novo thyroiditis.
- Most cases involve the left thyroid lobe.
- Staphylococcus aureus is the predominant cause.
- As in the index case, most patients are euthyroid.
- USG serves as first-line imaging modality. Heterogeneous parenchymal echotexture, surrounding fluid collection, and hypoechoic nodules are commonly observed USG findings in patients of AST.
- Radiologically guided aspiration drainage for thyroid abscess currently more recommended [1-10].

Conclusion

- Acute suppurative thyroiditis is a rare thyroid disease in adult.
- The mainstay treatment is antibiotic therapy if fails incision

and drainage can be necessary.

- Severe cases with airway compression hemithyroidectomy or total thyroidectomy if not responding to antibiotics and drainage.
- Immunocompetent patients and absence of underlying pyriform fistula have a favourable prognosis.

References

1. Begum A, Bari M, Ayaz K, Yasmin R, Rajib N, Rashid M, et al. Thyroiditis –A review. *J Med.* 2006;7.
2. Paes JE, Burman KD, Cohen J. Acute bacterial suppurative thyroiditis: a clinical review and expert opinion. *Thyroid.* 2010;20(3):247–55.
3. Chaudhary N, Gupta A, Motwani G, Kumar S. Fistula of the fourth branchial pouch. *Am J Otolaryngol.* 2003;24(4):250–2.
4. Nicoucar K, Giger R, Pope HG Jr, Jaecklin T, Dulguerov P. Management of congenital fourth branchial arch anomalies: a review and analysis of published cases. *J Pediatr Surg.* 2009;44(7):1432–9.
5. Yamada H, Fujita K, Tokuriki T, Ishida R. Nine cases of piriform sinus fistula with acute suppurative thyroiditis. *Auris Nasus Larynx.* 2002;29(4):361–5.
6. Berger SA, Zonszein J, Villamena P, Mittman N. Infectious diseases of the thyroid gland. *Rev Infect Dis.* 1983;5(1):108-22.
7. Yu EH, Ko WC, Chuang YC, Wu TJ. Suppurative *Acinetobacter baumannii* thyroiditis with bacteremic pneumonia: case report and review. *Clin Infect Dis.* 1998;27(5):1286-90.
8. Nishihara E, Miyauchi A, Matsuzuka F, Sasaki I, Ohye H, Kubota S, et al. Acute suppurative thyroiditis after fine-needle aspiration causing thyrotoxicosis. *Thyroid.* 2005;15:1183-7.
9. Ghaemi N, Sayedi J, Bagheri S. Acute suppurative thyroiditis with thyroid abscess: a case report and review of literature. *Iran J Otorhinolaryngol.* 2014; 26:51-55.
10. Shah SS, Baum SG. Diagnosis and management of infectious thyroiditis. *Curr Infect Dis Rep.* 2000; 2:147-53.