



## The Rupturing of Multiple Extracranial Mycotic Aneurysms as the Initial Symptom of Infective Endocarditis: A Case Report

Yuji Takahashi<sup>1\*</sup>, Hideki Hashimoto<sup>1</sup>, Natsumi Tomisawa<sup>1</sup> and Kensuke Nakamura<sup>1</sup>

Department of Emergency and Critical Care Medicine, Hitachi General Hospital, Japan

### Abstract

Infective Endocarditis (IE) presents with various systemic symptoms. It is widely recognized that its comorbidities include Mycotic Aneurysms (MA). We describe the case of a patient with IE whose initial symptom was a ruptured hepatic pseudoaneurysm. This led to a delayed diagnosis and the rupturing of a deep femoral pseudoaneurysm. Visceral aneurysmal rupture of unknown etiology should be suspected of being related to IE. In addition to examining for intracranial MA, examinations for extracranial MA may also be considered in left-sided IE with diagnostic delay. Clinicians must be aware that multiple MA can occur simultaneously in patients with IE.

**Keywords:** Mycotic aneurysm; Infective endocarditis; CT; CRP

### Introduction

Infective Endocarditis (IE) presents with various systemic symptoms, including fever, which is seen in almost all patients with the condition. The comorbidities of IE include Mycotic Aneurysms (MA), which often affect the intracranial arteries. Therefore, the current guidelines recommend that examinations for Intracranial MA (ICMA) should be routinely performed in all patients with left-sided IE [1]. However, there is limited evidence about screening for Extracranial MAs (ECMAs) associated with IE. We report a case of an afebrile IE patient without elevated inflammatory marker levels, who's initial symptom was a ruptured hepatic MA. The patient subsequently suffered the delayed rupture of a femoral MA.

### Case Presentation

The patient was a 48-year-old male without any relevant medical history other than gout. He had felt general fatigue and had a slight nocturnal fever for two weeks before admission, which was diagnosed as a gout attack. Although no antibiotics had been prescribed, he had occasionally taken antipyretics. Although he had a dental cavity, he had not undergone any dental or acupuncture treatment before the onset of his condition. He also stated that he was not abusing intravenous drugs. On the day of admission, he suddenly felt abdominal pain when he was driving a car and stopped to call an ambulance. On examination, his vital signs were as follows: blood pressure: 199/102 mmHg, pulse rate: 79 bpm, respiratory rate: 30/min, SpO<sub>2</sub>: 98% in room air, body temperature: 36.2°C, and Glasgow Coma Scale: E3V5M6. He was experiencing a cold sweat and complained of severe pain. Bedside echography revealed swirling blood flow in the liver, and contrast-enhanced Computed Tomography (CT) showed hepatic hemorrhaging with extravasation (Figure 1). No abnormalities were detected in blood tests: C-Reactive Protein (CRP): 1.12 mg/dL, procalcitonin: 0.09 ng/mL, and white blood cell count: 12200/μL. Since the patient presented with non-responsive hemorrhagic shock right after the CT examination, we conducted Resuscitative Endovascular Balloon Occlusion of the Aorta (REBOA) and emergent surgery. After stabilization, transarterial embolization was performed for extravasation from the middle hepatic artery, which was considered to have caused the hemorrhaging (Figure 2). The patient was admitted to the Intensive Care Unit (ICU). Cefazolin was only prescribed for two days in the perioperative period.

Although the patient was febrile, and his CRP level increased after surgery, such findings are frequently encountered after invasive operations; therefore, blood cultures were taken, but no antibiotic therapy was administered. The patient was moved out of the ICU on the 8<sup>th</sup> day. Treatment with piperacillin/tazobactam was started on the 9<sup>th</sup> day because the patient's CRP level was elevated, which was considered to have been caused by a urinary tract infection, and the regimen was

### OPEN ACCESS

#### \*Correspondence:

Yuji Takahashi, Department of  
Emergency and Critical Care Medicine,  
Hitachi General Hospital, 2-1-1, Jonan-  
cho, Hitachi, Ibaraki, 317-0077, Japan,  
Tel: 81294231111; Fax: 81294238317;  
E-mail: yuji.takahashi.ax@hitachi.com

**Received Date:** 09 Mar 2019

**Accepted Date:** 05 Apr 2019

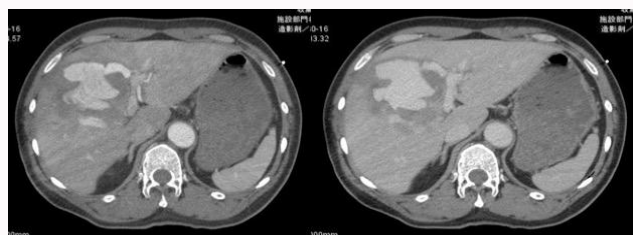
**Published Date:** 09 Apr 2019

#### Citation:

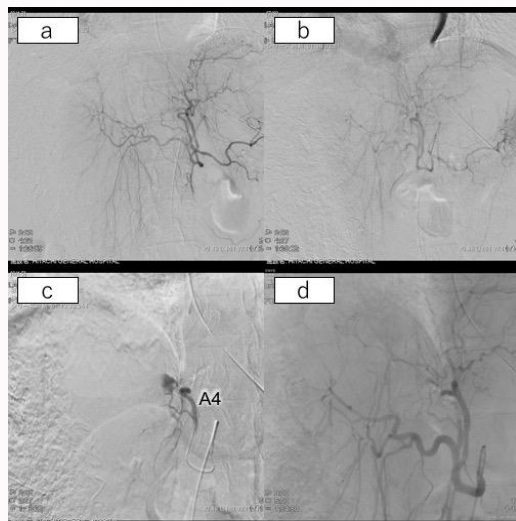
Takahashi Y, Hashimoto H, Tomisawa  
N, Nakamura K. The Rupturing  
of Multiple Extracranial Mycotic  
Aneurysms as the Initial Symptom of  
Infective Endocarditis: A Case Report.  
*Ann Clin Case Rep.* 2019; 4: 1644.

**ISSN: 2474-1655**

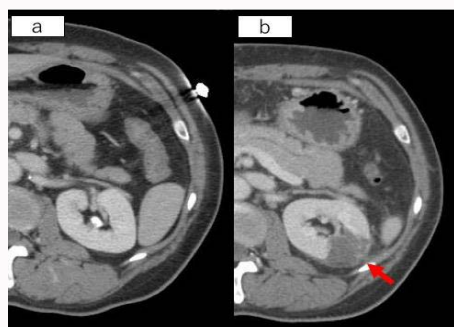
**Copyright** © 2019 Yuji Takahashi. This  
is an open access article distributed  
under the Creative Commons Attribution  
License, which permits unrestricted  
use, distribution, and reproduction in  
any medium, provided the original work  
is properly cited.



**Figure 1:** A contrast-enhanced CT scan obtained on arrival revealed an intrahepatic hematoma and extravasation. The initial diagnosis was a ruptured hepatic pseudoaneurysm.

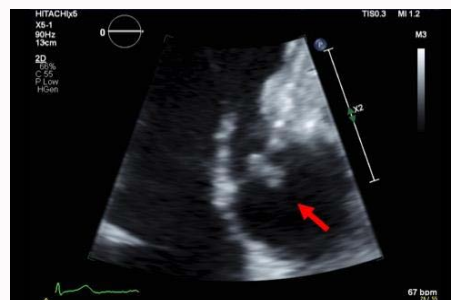

**Figure 2:** (a, b) No obvious extravasation was found on celiac arteriography. Also, no arteriovenous shunt was detected. (c) Selective arteriography of the middle hepatic artery showed extravasation from the A4 branch. (d) Celiac arteriography revealed that the extravasation disappeared after the embolization procedure.

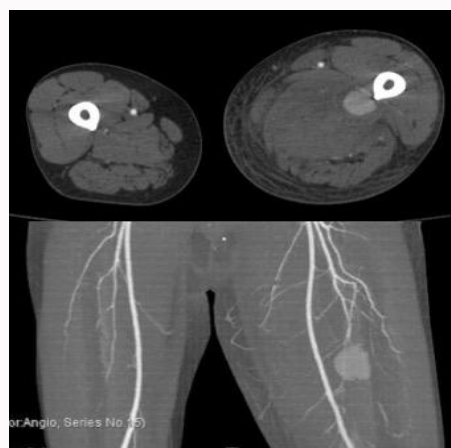

**Figure 3:** A renal infarction was found incidentally. This finding was a key clue to the final diagnosis.

changed to ampicillin/sulbactam on the 22<sup>nd</sup> day. A CT scan, which was performed to follow-up the hepatic hemorrhaging, revealed a left-sided renal infarction, which was the first time the patient was suspected of having IE (Figure 3). Transthoracic Echocardiography (TTE) showed a tricuspid aortic valve with a hyperechoic lesion on its uncrowned leaflet, which was considered to be a vegetative lesion (Figure 4). Thus, we diagnosed the patient with possible IE based on the presence of one each of the major and minor modified Duke criteria. Cranial MRI was performed, and no emboli or MA were found. However, the patient suddenly complained of severe pain and swelling of his left leg on the 27<sup>th</sup> day. He was newly diagnosed



**Figure 4:** Transthoracic echocardiography performed on the 24<sup>th</sup> day revealed a high-echoic mass on the uncrowned leaflet of the tricuspid aortic valve.



**Figure 5:** Delayed rupturing of a mycotic aneurysm of the left deep femoral artery was detected on the 27<sup>th</sup> day.

with a ruptured left deep femoral artery aneurysm and was treated with interventional radiology (Figure 5). Additional exploration by CT angiography of the whole body revealed no additional MA. The patient was discharged on the 64<sup>th</sup> day after the completion of 6 weeks' antibiotic treatment with ampicillin/sulbactam. Although multiple blood cultures were taken during the patient's clinical course, no microorganisms were found.

## Discussion

Two important lessons can be addressed from the present case. First, IE should be considered when visceral aneurysms of unknown origin are found, especially for the ruptured cases, and blood cultures should be taken before the administration of antibiotics in such cases. Second, examinations for both ICMA and extracranial MA (ECMA) may be considered in cases of left-sided IE with diagnostic delay.

IE should be considered when visceral aneurysms of unknown origin are found, especially for the ruptured cases, and blood cultures should be taken before the administration of antibiotics in such cases. It is widely known that MA can occur as a vascular phenomenon of IE. Whereas ICMA, which are found in 1.2% to 5% of IE cases, are said to be the predominant form of MA found in IE [2-6], ECMA are relatively rare. A retrospective study including 922 cases of definitively diagnosed IE reported that peripheral MA was observed in 18 (1.9%) cases. Of these, 12 (66%) involved ICMA, and 6 (34%) involved ECMA [7]. However, the incidence of MA accompanied by IE might be underestimated because it sometimes presents with no obvious symptoms or diminishes after antibiotic

therapy is started; this is why we should take into account the possibility of IE as an etiology of a visceral aneurysm. On the other hand, from the perspective of visceral aneurysm, the Hepatic Artery Aneurysms (HAA) was considered to be closely related to IE before the antibiotics era. Recently; however, the number of HAA caused by IE has decreased, and atherosclerosis has become the main cause of HAA [8,9]. A retrospective chart review of 306 patients with visceral aneurysms reported that 36 (12%) of the 306 aneurysms were HAA, whereas only one (0.3%) of them was a MA [10]. Besides the low incidence of the HAA accompanied with IE, the patient in our case did not show any signs of IE, such as fever or inflammatory responses during laboratory tests at presentation; therefore, no blood cultures were taken in the emergency department, and initial TTE was performed very late. Several blood cultures obtained after surgery revealed negative results. It might be due to the influence of cefazolin, which was administered perioperatively. The detection of positive blood cultures or the earlier TTE might have resulted in the early diagnosis and treatment of IE. Notably, the previous study also revealed that all 5 ruptured HAA were finally diagnosed as having non-atherosclerotic etiologies, including fibromuscular dysplasia, polyarteritis nodosa, and MA [10]. Even though the incidence of MA is decreasing, if the origin of visceral aneurysms is unknown it is truly important to exclude the possibility of IE-related MAs, especially for the ruptured cases.

Examinations for both ICMA and ECMA may be considered in cases of left-sided IE with diagnostic delay. Although IE-associated MA is rare, the mortality rate of IE patients with ICMA is extremely high. The overall mortality rate of IE-related ICMA is 60%. The mortality rate of unruptured ICMA is 30%, while it reaches 80% in cases of ruptured ICMA [2,11]. Therefore, the current AHA (American Heart Association) guidelines recommend that all left-sided IE patients should undergo imaging examinations to exclude ICMA, even if they are asymptomatic (Class 2b; level of evidence C) [1]. On the contrary, there are no descriptions about the necessity of examinations for ECMA. This case report showed multiple ECMAs. Although there have been a few case reports about cases addressing multiple MA in a patient with IE [12,13], the frequency of these cases has not been determined. A previous study stated that multiple ICMA were seen in 20% of left-sided IE patients [5], whereas another study found that only one of 922 IE patients (0.1%) had multiple ICMA [7]. The same study also found those diagnostic-delay  $\geq 30$  days was statistically significant to the presence of MA [7]. In patients with left-sided IE that are not treated properly, multiple MA might occur more frequently. Considering the high mortality and morbidity rates of ruptured MA, clinicians should not disregard the potential danger of these lesions and should make an effort to detect them earlier. The vessel walls of MA have become fragile because of inflammation; thus, the risk of rupture is higher regardless of the size of the aneurysm. In contrast, the risk of atherosclerotic aneurysms rupturing depends on the size of the aneurysm. In our case, we did not take account of the possibility of the presence of multiple MA, and we only performed cranial screening for ICMA. As a result, the patient experienced two ruptured MA. To avoid such situations, patients with left-sided IE may undergo examinations for both ICMA and ECMA, especially when the diagnosis was delayed. As screening modalities, the AHA guidelines recommend that CT angiography, magnetic resonance angiography, or digital subtraction angiography should be performed to detect ICMA (Class 2a; level of evidence B), and contrast-enhanced

CT or CT angiography with 3D reconstruction (Class 1; level of evidence B) should be used to search for ECMA [1].

IE should be considered when visceral aneurysms of unknown origin are found, especially for the ruptured cases. Examinations for both ICMA and ECMA may be considered in patients of left-sided IE with diagnostic delay. Although our patient was eventually saved, the detection of the underlying IE occurred very late because of the lack of typical symptoms and history. If blood cultures had been taken at an appropriate time, IE could have been diagnosed earlier, which might have led to the early initiation of appropriate antibiotics and the prevention of the delayed rupturing of the femoral MA. Since IE patients with diagnostic delay may be classified as being at high risk of developing MA and subsequently experiencing a ruptured MA, they may undergo examinations for both ICMA and ECMA.

## Conclusion

Patients suffering from ruptured visceral aneurysms present with sudden and severe abdominal pain. The rupturing of such aneurysms can be the initial symptom of IE, since MA is considered to be more vulnerable and to be ruptured more easily than aneurysms caused by atherosclerosis. Clinicians should consider IE in these situations. Patients of left-sided IE with diagnostic delay may be examined for both ICMA and ECMA. Clinicians must be aware that multiple MA can occur simultaneously in patients with IE.

## References

1. Baddour LM, Wilson WR, Bayer AS, Fowler VG Jr, Tleyjeh IM, Rybak MJ, et al. Infective endocarditis in adults: diagnosis, antimicrobial therapy, and management of complications: a scientific statement for healthcare professionals from the American Heart Association. *Circulation*. 2015;132(15):1435-86.
2. Wilson WR, Giuliani ER, Danielson GK, Geraci JE. Management of complications of infective endocarditis. *Mayo Clin Proc*. 1982;57(3):162-70.
3. Camarata PJ, Latchaw RE, Rüfenacht DA, Heros RC. Intracranial aneurysms. *Invest Radiol*. 1993;28(4):373-82.
4. Lerner PI. Neurologic complications of infective endocarditis. *Med Clin North Am*. 1985;69(2):385-98.
5. Clare CE, Barrow DL. Infectious intracranial aneurysms. *Neurosurg Clin N Am*. 1992;3(3):551-66.
6. Moskowitz MA, Rosenbaum AE, Tyler HR. Angiographically monitored resolution of cerebral mycotic aneurysms. *Neurology*. 1974;24(12):1103-8.
7. González I, Sarriá C, López J, Vilacosta I, San Román A, Olmos C, et al. Symptomatic peripheral mycotic aneurysms due to infective endocarditis: a contemporary profile. *Medicine (Baltimore)*. 2014;93(1):42-52.
8. Jordan M, Razvi S, Worthington M. Mycotic hepatic artery aneurysm complicating *Staphylococcus aureus* endocarditis: successful diagnosis and treatment. *Clin Infect Dis*. 2004;39(5):756-7.
9. Hulsberg P, Garza-Jordan Jde L, Jordan R, Matusz P, Tubbs RS, Loukas M. Hepatic aneurysm: a review. *Am Surg*. 2011;77(5):586-91.
10. Abbas MA, Fowl RJ, Stone WM, Panneton JM, Oldenburg WA, Bower TC, et al. Hepatic artery aneurysm: factors that predict complications. *J Vasc Surg*. 2003;38(1):41-5.
11. Bohmfalk GL, Story JL, Wissinger JP, Brown WE Jr. Bacterial intracranial aneurysm. *J Neurosurg*. 1978;48(3):369-82.
12. Ilic N, Banzic I, Stekovic J, Koncar I, Davidovic L, Fatic N. Multiple visceral artery aneurysms. *Ann Vasc Surg*. 2015;29(6):1318.

13. Park JH, Jang HR, Lee JE, Huh W, Kim DJ, Oh HY, et al. Infective endocarditis with multiple mycotic aneurysms mimicking vasculitis: A case report. *Can J Infect Dis Med Microbiol.* 2012;23(3):e67-8.
14. Hsu RB, Chen RJ, Wang SS, Chu SH. Infected aortic aneurysms: clinical outcome and risk factor analysis. *J Vasc Surg.* 2004;40(1):30-5.