Annals of Clinical Case Reports

Case Report
Published: 09 Jan, 2023

Spontaneous Whitish Hyphema in Diabetic Hyperlipidemia: A Case Report

Huang Y[1], Chen Q[1] and Li X[1,2]*

[1]Xiamen Eye Centre, Xiamen University, China

[2]Department of Ophthalmology, Peking University People's Hospital, Beijing, China

Abstract

Background: We described a rare case of whitish hyphema, resulted from spontaneous chylaemia of anterior chamber in uncontrolled diabetic hyperlipidemia.

Case Report: A 45-year-old man presented acute blurred vision and whitish left eye for 2 days, without any pain or discomfort, no ocular trauma and surgery history. The visual acuity was hand-movement and Intraocular Pressure (IOP) was 37.1 mmHg. The visual acuity and IOP restored in several days with spontaneous resolution of the milky fluid. Biochemistry tests proved the milky fluid was chylaemia of anterior chamber. A fluorescein angiography and irrigation operation was performed, which revealed it came from rupture of iris capillary.

Conclusion: Milky fluid in anterior chamber probably imply a special type of hyphema resulted from uncontrolled diabetic retinopathy and hyperlipidemia.

Keywords: Hyphema; Chylaemia; Spontaneous; Diabetic hyperlipidemia

Background

The aqueous humor is a colorless, transparent fluid that fills the anterior chamber of the eye. It plays an important role in maintaining the intraocular pressure and providing nourishment to the lens and cornea [1]. The aqueous humor begins to be murky only when the blood-aqueous barrier is damaged, it usually becomes opaque or whitish while lens rupture or endophthalmitis containing many inflammatory cells or proteins [2,3].

Hyphema means bleeding into anterior chamber, it usually appears as a reddish tinge, small pool of blood at the bottom of the anterior chamber near the iris and cornea. It is frequently caused by ocular trauma or intraocular surgery. Most uncomplicated hyphema resolve within 5 to 6 days [4]. We reported a spontaneous, special "whitish hyphema" caused by uncontrolled diabetic hyperlipidemia.

Case Presentation

A 45-year-old man presented with acute blurred vision and diffuse white coloration to the entire anterior chamber in his left eye for 2 days at Xiamen Eye Centre affiliated to Xiamen University, without pain and other discomfort. He denied ocular trauma and surgery history on repeated queries. He reported a history of diabetes and hypertension for 4 years, but ignoring regular treatment. His visual acuity was hand-movement and intraocular pressure was 37.1 mmHg. Slit-lamp examination revealed moderate conjunctival hyperemia and diffuse white coloration to the entire anterior chamber (Figure 1), no distinct abnormality in corneal confocal microscopy nor ocular B-ultrasound.

Routine laboratory tests revealed grossly creamy plasma, there was dense chylomicron floating on the top layer, it was significantly different from normal serum (left sample in Figure 2). his serum triglyceride was 27.06 mmol/L (normal, up to 1.8 mmol/L), total cholesterol was 17.24 mmol/L (normal, up to 6.2 mmol/L), and blood glucose was 21.8 mmol/L (normal, up to 6.1 mmol/L), heart rate was 136 per minute, but blood pressure was normal. Hypolipidemic and hypoglycemic agents were used immediately for controlling of blood-lipid and blood-sugar, besides, intraocular pressure lowering medication and topical antibiotic were used for symptomatic treatment and preoperative preparation. 48 h later, the thick milky fluid was diminished, and gradually absorbed, thus we found the crystalline lens was visible and normal (Figure 3), iris neovascularization was absent, his visual

OPEN ACCESS

***Correspondence:**
Yanming Huang, Xiamen Eye Centre affiliated to Xiamen University, No.336 XiaHe Road, Siming District, Xiamen, Fujian, China,
E-mail: fuxead@126.com

Received Date: *15 Dec 2022*
Accepted Date*: 05 Jan 2023*
Published Date*: 09 Jan 2023*

Citation:
Huang Y, Chen Q, Li X. Spontaneous Whitish Hyphema in Diabetic Hyperlipidemia: A Case Report. Ann Clin Case Rep. 2023; 8: 2377.
***ISSN: 2474-1655**.*

Figure 1: Conjunctival hyperemia and diffuse milky fluid in the entire anterior chamber detected by slit lamp examination.

Figure 2: Compare the milky serum of patient (left) with a normal serum (right).

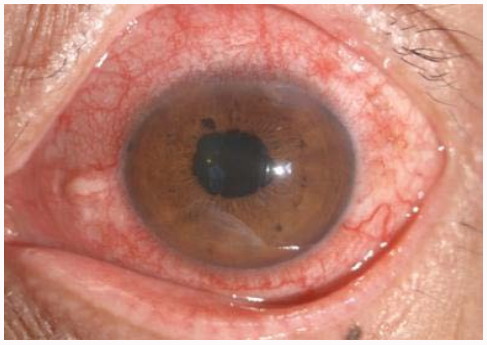

Figure 3: After irrigation, anterior chamber was clear and the crystalline lens was intact.

acuity was improved significantly to 20/20, and IOP was declined to be normal progressively.

The clinical manifestation of this case was similar to hyphema, furthermore, considering on his milky serum sample appearance, we suspected the milky fluid in anterior chamber was very likely to be hyphema. Therefore, after written informed consent was obtained from the patient for surgery, anterior chamber irrigation was performed, we observed there was a tiny active bleeding spot



Figure 4: Biopsy specimen showed erythrocytes (red circles) in aqueous humor by optical microscope (x400).

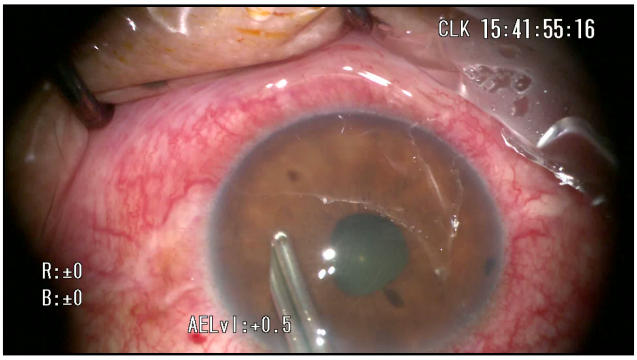

Video: A surgical video of active bleeding spot on inferior iris during irrigation.

on inferior iris when the pressure was fluctuating during irrigation procedure (Additional file 1: Video). A few erythrocytes were found in aqueous humor biopsy specimen under optical microscope (Figure 4). He was diagnosed non-proliferative diabetic retinopathy, without lipemia retinalis by Fundus Fluorescein Angiography (FFA) (Figure 5) and fundus photography (Figure 6). During 3 years following-up, both of his eyes showed to be stable since he had got reasonable diabetic therapy, and his diabetes and hyperlipoidemia were well controlled too.

Discussion and Conclusion

Chylaemia was a characteristic representation of severe hyperlipoidemia, which caused by the chylomicrons accompanying extremely high triglyceride and total cholesterol in serum [5]. Patients with chylaemia usually related to history of diabetes mellitus or disturbance in the lipid metabolism. Various ocular abnormities had been related to hyperlipoidemia, such as lipemia retinalis, arcus senilis [6]. Our patient demonstrated neither of them despite extreme hyperlipoidemia, the final diagnosis of chylaemia of anterior chamber and hyperlipoidemia was made by irrigation surgery and biochemistry examination.

Hyphema could present with a diffuse white look in patients with hyperlipoidemia during or following ocular trauma or operation. In 1972, af Ursin and Alho et al. [7] had reported a 41-year-old man was found corneal erosion and 3 mm hyphema in the bottom, while the white opaque milky fluid was filled with in upper anterior chamber after his eye was hit by a stone. The thick milky fluid disappeared

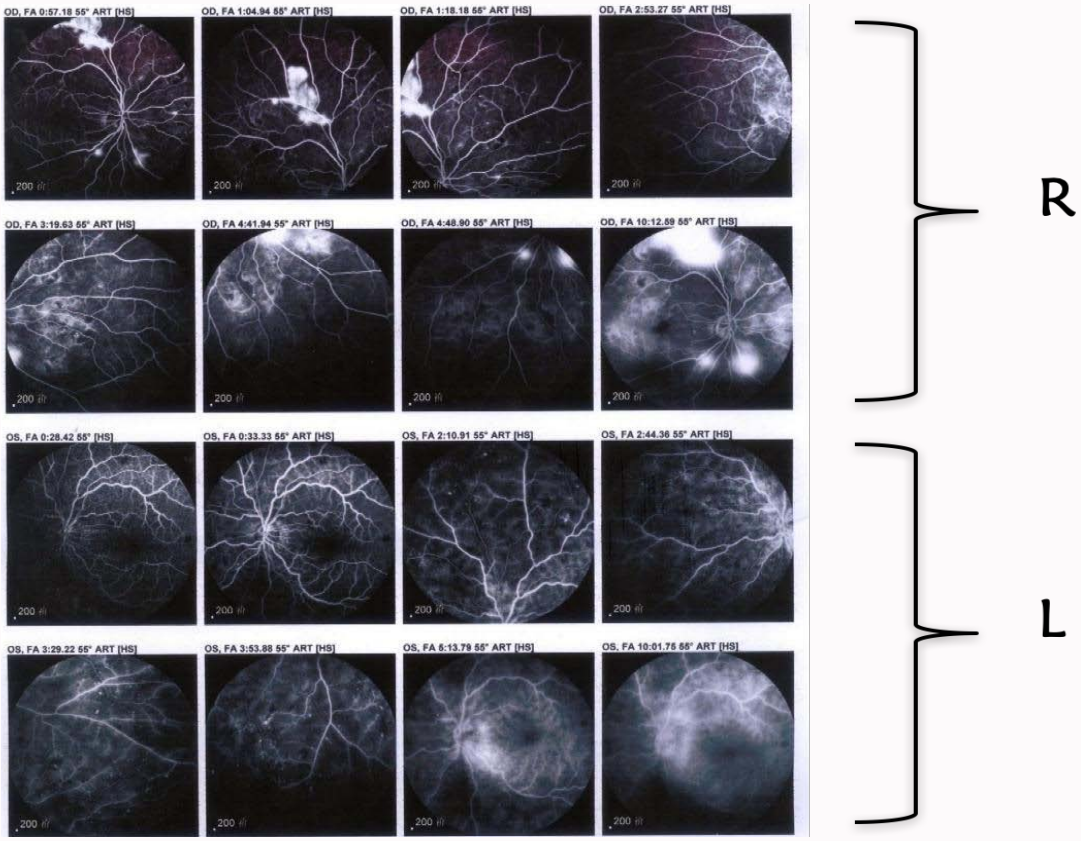

Figure 5: Fluorescein angiography of both eyes (FFA).

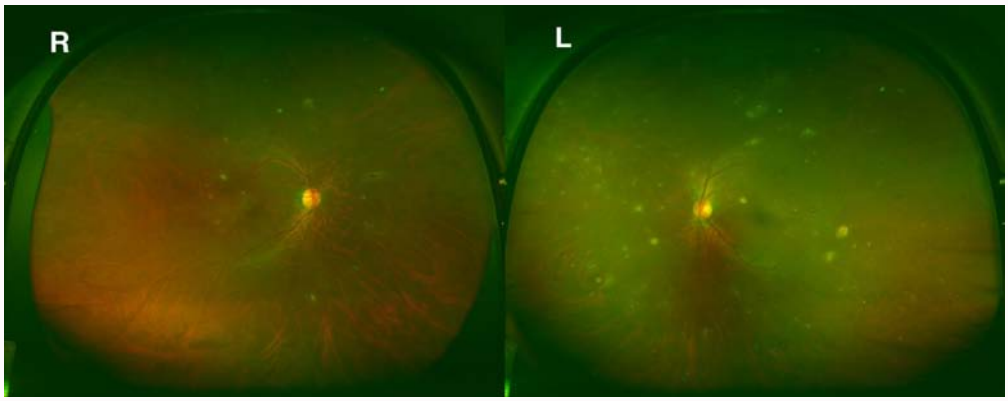

Figure 6: Fundus image of both eyes.

next morning quickly, 2 weeks later his eye restored health. Hirst, Hazzard [8] observed a 58-year-old man with hypertension, obesity and insulin-dependent diabetes initial red coloration of hyphema had turned to be whitish, fibrinous clot within seconds during suture in cataract surgery. Subsequently, diffuse white fluid occupied entire anterior chamber, but it disappeared within 24 h.

Unlike these previously reported cases, our patient was a chef with high-fat diet, without any ocular trauma or surgery history. He had not taken his diabetes seriously, which resulted in severe lipids metabolism abnormity. It was difficult to recognize what the milky fluid in anterior chamber was at first glance of slit lamp examination without detail systemic disease history and examination. Lens rupture or endophthalmitis were excluded because of lacking relevant history and appearance. Furthermore, the biochemistry testing revealed disturbance in the lipid and sugar metabolism. Considering on his milky serum and the milky fluid in anterior chamber progressively spontaneous assimilation, we suspected it might be chylaemia, finally, erythrocytes in aqueous humor biopsy testified it was true. After iris neovascularization was excluded and non-proliferative diabetic retinopathy were diagnosed by FFA and fundus photography, irrigation surgery revealed the bleeding spot probably originated from rupture of iris capillary.

In a word, we reported a rare whitish hyphema case, it actually was chylaemia of anterior chamber. Milky fluid in anterior chamber probably implies a special type of hyphema resulted from uncontrolled diabetic retinopathy and hyperlipidemia.

Authors' Contribution

YM Huang and QZ Chen contributed to the conception and design, collected and analyzed the data and images, drafted the manuscript, XX Li revised it and gave many important advices. All authors have given final approval of the version to be published.

Acknowledgement

Thanks staffs in clinic lab of Xiamen Eye Centre affiliated to Xiamen University.

References

1. Johson M, Mclaren JW, Overby DR. Unconventional aqueous humor outflow: A review. Exp Eye Res. 2017;158(9):94-111.
2. Taylor A. A review of the influence of aqueous humor on immunity. Ocul Immunol Inflamm. 2003;11(4):231-41.
3. Goel M, Piccian RG, Lee RK, Bhattacharya SK, et al. Aqueous humor dynamics: A review. Open Ophthalmol J. 2010;4:52-9.
4. SooHoo JR, Davies BW, Braverman RS, Enzenauer RW, McCourt EA. Pediatric traumatic hyphema: A review of 138 consecutive cases. JAAPOS. 2013;17(6):565-7.
5. Hinkle JW, Relhan N, Flynn HW. Lipemia retinalis, macular edema, and vision loss in a diabetic patient with a history of type IV hypertriglyceridemia and pancreatitis. Case Rep Ophthalmol. 2018;9(3):425-30.
6. Chaum E. Detection of lipemia retinalis during telemedical diabetic retinopathy screening. Ophthalmology. 2020;127(7):900.
7. af Ursin KV, Alho M, Bjorklund A. Ocular contusion and hyperlipidaemia. Br J Ophthalmol. 1972;56(9):706-8.
8. Hirst LW, Hazzard WR. Hyperlipidemia and cataract extraction. Arch Ophthalmol. 1984;102(3):358.