



## Reversible Cytotoxic Cortex Oedema Associated with Levofloxacin-Induced Seizures. A Case Report

Roberto Padrini<sup>1\*</sup>, Marco Panfili M<sup>2</sup>, Marta Martin<sup>2</sup>, Mariagiulia Anglani<sup>3</sup>

<sup>1</sup>Department of Cardiological, Department of Medicine, University of Padova, Italy

<sup>2</sup>Department of Cardiological, Thoracic and Vascular Sciences, University of Padova, Italy

<sup>3</sup>Department of Cardiological, Department of Neurosciences, University of Padova, Italy

### Abstract

**Aim:** To describe a case of levofloxacin-induced seizures associated with reversible magnetic resonance (MR) brain alterations.

**Methods:** A 95-year-old white woman had three convulsive episodes two days after starting levofloxacin therapy (500mg qd). After drug withdrawal, seizures subsided and a diagnostic path was instituted.

**Results:** Acute cerebrovascular events were excluded. MR images obtained 7 days after the onset of seizures showed bilateral alterations in the medial prefrontal cortex, compatible with cytotoxic oedema. Thirty-seven days later, such alterations had disappeared.

**Conclusions:** Cytotoxic oedema may have been produced by massive glutamate release during epileptic episodes. However, a glutamatergic effect of fluoroquinolones cannot be excluded and deserves further study.

### Case Report

A 95-year-old white woman was admitted for severe asthenia and shortness of breath. She had a clinical history of hypertension and chronic constipation. Blood laboratory data revealed severe anaemia associated with iron deficiency, which was treated with blood transfusion and administration of iron i.v. Since potassium serum levels were below the lower normal limit (2.8 mmol/L), oral therapy with a K-sparing diuretic was instituted (canrenone 50mg qd). Haematochemical indexes of liver and renal function were within normal ranges; in particular, eGFR was 82 mL/min/1.73m<sup>2</sup> (CKD-EPI formula). After suspected occult intestinal bleeding, endoscopic examinations revealed colon diverticulosis, particularly severe in the distal tract. After the above treatments, haemoglobin rose to 11.5mg/dL, potassium to 3.5 mmol/L, and respiratory symptoms disappeared.

On the last day of hospitalisation, the patient developed cystitis, so that oral treatment with levofloxacin 500mg qd was started in hospital and continued at home. Other drugs prescribed at discharge were: esomeprazole 20mg qd (8 a.m.), rifaximin 400mg bd (8 a.m. /4 p.m. for 7 days), canrenone 50 mg qd (2 p.m.), furosemide 25mg qd (8 a.m.), allopurinol 300mg qd (8 a.m.), amlodipine 10mg qd (8 a.m.), doxazosin 1mg qd (8 a.m.) and triazolam 0.25mg qd (10 p.m.).

Two days after discharge, the patient had two episodes of loss of consciousness, followed by tonic contraction of the limbs lasting a few minutes, with residual, transient mental confusion. A CT scan at the hospital emergency room excluded acute ischaemic or hemorrhagic events. The patient refused an EEG. A third seizure occurred at night and was treated with i.v. diazepam. A further brain CT excluded new acute events. As levofloxacin was suspected of playing a causal role in the seizures, it was withdrawn. Therapy with phenytoin was instituted (100mg i.v. tid) but three days later had to be stopped due to onset of muscular dyskinesia, and was replaced by levetiracetam (500mg bd). One week after the last epileptic episode, cerebral magnetic resonance (MR) demonstrated moderate cerebral atrophy, diffuse hypodensity of white matter, and bilateral alterations in the medial prefrontal cortex, compatible with cytotoxic oedema (Figure 1A). No significant cerebral vessel stenosis were shown by angio-MR; nor did EEG show abnormal electrical activity. The patient was discharged on levetiracetam (500mg bd) and re-evaluated 37 days later. On follow-up, she remained seizure-free and MR showed complete regression of the morphological alterations

### OPEN ACCESS

#### \*Correspondence:

Roberto Padrini, Department of Medicine, University of Padova, Via Giustiniani 2, 35128 Padova, Italy, Tel: +39-049-8218332; Fax: +39-049-8212827;

E-mail: roberto.padrini@unipd.it

Received Date: 07 Jul 2016

Accepted Date: 19 Aug 2016

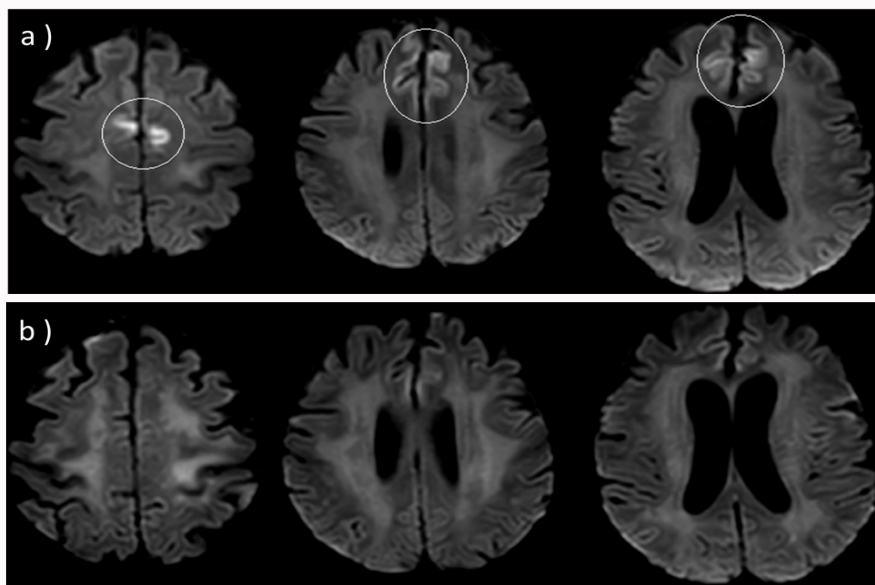
Published Date: 23 Aug 2016

#### Citation:

Padrini R, Marco Panfili M, Martin M, Anglani M. Reversible Cytotoxic Cortex Oedema Associated with Levofloxacin-Induced Seizures. A Case Report. *Ann Clin Case Rep.* 2016; 1: 1091.

Copyright © 2016 Roberto Padrini.

This is an open access article distributed under the Creative Commons Attribution License, which permits unrestricted use, distribution, and reproduction in any medium, provided the original work is properly cited.



**Figure 1:** Axial Diffusion Weighted Imaging (DWI): a) small symmetrical hyperintense areas in medial region of superior frontal circumvolution, corresponding to medial prefrontal cortex area. Lesions show low values on Apparent Diffusion Coefficient (ADC) map, characteristic of cytotoxic oedema; b) follow-up MR images 37 days later, showing complete resolution of cytotoxic cortical lesions and regular homogeneous intensity of DWI signal along cortical layer in medial prefrontal cortex on both sides.

previously appearing in the medial prefrontal cortex (Figure 1B).

To our knowledge, this finding has never been reported before and needs to be briefly discussed. The changes seen in MR may have been the consequence of the repeated epileptic attacks. Transient focal CT and MR changes have been reported to occur after generalized tonic-clonic seizures or status epilepticus, and attributed to local increases in vascular perfusion and permeability and to massive release of cytotoxic mediators, such as glutamate [1]. However, the direct causal role of levofloxacin cannot be excluded. Fluoroquinolones are known to produce excitatory CNS effects, which may result in adverse psychiatric and neurologic reactions. Within this class of drugs, levofloxacin has demonstrated a low epileptogenic potential [2]. In addition, a literature review published in 2009 reported only six cases of seizures associated with levofloxacin [3] and only three more have been published since then [4-6]. Old age is a recognised risk factor for fluoroquinolone-induced seizures. Our patient was very old (95), but apparently she did not have any other predisposing conditions, such as electrolyte imbalance, renal dysfunction, interacting drugs (e.g., NSAIDs, theophylline) or pre-existing seizure disorders.

Mechanisms proposed to explain fluoroquinolone neurotoxicity include antagonism at the inhibitory GABAA receptor and synergism at the excitatory NMDA receptor. The “GABA hypothesis” is weakened by the evidence that fluoroquinolones have low affinity for GABAA receptors. In particular, it has been estimated that levofloxacin at concentrations expected in the human brain after therapeutic doses occupies 1.1% of GABAA receptors, so that can hardly exert clinically significant inhibition [7]. Instead, enhancement of the excitatory glutamate effect produced by fluoroquinolones in rat hippocampus slices [8] occurred at concentrations (0.5-1  $\mu\text{M}$ ) compatible with levofloxacin-free concentrations expected in the human brain (0.065  $\mu\text{M}$ ) [7]. In addition, quinolones reduced the threshold for seizures by electroshock induced in a murine model and their proconvulsive activity was completely blocked by an NMDA receptor antagonist (MK-801) [9]. With this background, it seems

reasonable to suggest that fluoroquinolones can induce neurotoxicity mainly through a glutamatergic effect. If this is so, the MR cytotoxic alterations seen in our patient after repeated seizures may have been due to a combination of excessive neuronal discharge and the direct glutamatergic effect of levofloxacin. Further studies are needed to clarify the relative contribution of the two mechanisms.

## Results

Acute cerebrovascular events were excluded. MR images obtained 7 days after the onset of seizures showed bilateral alterations in the medial prefrontal cortex, compatible with cytotoxic oedema. Thirty-seven days later, such alterations had disappeared.

## Conclusions

Cytotoxic oedema may have been produced by massive glutamate release during epileptic episodes. However, a glutamatergic effect of fluoroquinolones cannot be excluded and deserves further study.

## References

- Kim JA, Chung JJ, Yoon PH, Kim DI, Chung TS, Kim EJ, et al. Transient MR signal changes in patients with generalized tonicoclonic seizures or status epilepticus: periictal diffusion-weighted imaging. *Am J Neuroradiol.* 2001; 22: 1149-1160.
- Tome AM, Filipe A. Quinolones. Review of psychiatric and neurological adverse reactions. *Drug Saf.* 2011; 34: 465-488.
- Bellon A, Perez-Garcia G, Coverdale JH, Chacko RC. Seizures associated with levofloxacin: case presentation and literature review. *Eur J Clin Pharmacol.* 2009; 65: 959-962.
- Mazzei D, Accardo J, Ferrari A, Primavera A. Levofloxacin neurotoxicity and non-convulsive status epilepticus (NCSE): a case report. *Clin Neurol Neurosurg.* 2012; 114: 1371-1373.
- Gervasoni C, Cattaneo D, Falvella FS, Vitiello P, Cheli S, Milazzo L, et al. Levofloxacin-induced seizures in a patient without predisposing risk factors: the impact of pharmacogenetics. *Eur J Clin Pharmacol.* 2013; 69: 1611-1613.

6. Famularo G, Pizzicannella M, Gasbarrone L. Levofloxacin and seizure: what risk for elderly adults? *JAGS*. 2014; 62: 2018-2019.
7. Kim J, Ohtani H, Tsujimoto M, Sawada Y. Quantitative comparison of convulsive activity of combination of twelve fluoroquinolones with five nonsteroidal antiinflammatory agents. *Drug Metab Pharmacokinet*. 2009; 24: 167-174.
8. Schmuck G, Schürmann A, Schlüter G. Determination of the excitatory potencies of fluoroquinolones in the central nervous system by an in vitro model. *Antimicrob Agents Chemother*. 1998; 42: 1831-1836.
9. Williams PD, Helton DR. The proconvulsive activity of quinolone antibiotics in an animal model. *Toxicol Lett*. 1991; 58: 23-28.