



Reduction of the Corpus Callosum in First-Episode, Drug Naive Schizophrenia Patients is Worsened in the Absence of Depression Symptoms: Evidence for Depression-Type Schizophrenia

Jiaen Ye^{1#}, Feng J^{2#}, Wei Liu^{3#}, Gongying L², Zhiyuan Xun⁴, Hongjun Tian⁴, Xiaoyan Ma⁴, Chuanjun Zhuo^{1,2,4*} and Haoran Chen^{1*}

¹Department of Psychiatric-Neuroimaging-Genetics Laboratory, Wenzhou Seventh People's Hospital, China

²Department of Psychiatry, School of Mental Health, Jining Medical University, China

³Department of Psychiatry, The First Affiliated Hospital of Harbin Medical University, China

⁴Department of Psychiatric-Neuroimaging-Genetics and Comorbidity Laboratory (PNGC-lab), Tianjin Medical University, China

*These authors are equally contributed

OPEN ACCESS

*Correspondence:

Chuanjun Zhuo, Department of Psychiatric-Neuroimaging-Genetics and Comorbidity Laboratory (PNGC-lab), Tianjin Mental Health Centre, Mental Health Teaching Hospital of Tianjin Medical University, Tianjin Aiding Hospital, Tianjin, 300222, China, E-mail: chuanjunzhuo@163.com

Haoran Chen, Department of Psychiatric-Neuroimaging-Genetics Laboratory, Wenzhou Seventh People's Hospital, China, E-mail: chgdwzm7yuan@163.com

Received Date: 15 Feb 2019

Accepted Date: 06 Mar 2019

Published Date: 08 Mar 2019

Citation:

Ye J, Ji F, Liu W, Li G, Xun Z, Tian H, et al. Reduction of the Corpus Callosum in First-Episode, Drug Naive Schizophrenia Patients is Worsened in the Absence of Depression Symptoms: Evidence for Depression-Type Schizophrenia. *Ann Clin Case Rep*. 2019; 4: 1618.

ISSN: 2474-1655

Copyright © 2019 Chuanjun Zhuo and Haoran Chen. This is an open access article distributed under the Creative Commons Attribution License, which permits unrestricted use, distribution, and reproduction in any medium, provided the original work is properly cited.

Opinion

The Corpus Callosum (CC) has been reported to be reduced in patients with schizophrenia in whom a reduced CC has been described as a distinct pathological feature but increased in patients with major depression [1-3]. Some researchers have proposed that CC reduction is a marker of schizophrenia and that CC alterations could be used for identifying schizophrenia and major depression [1-4]. The prevalence of depression symptoms in patients with schizophrenia has been reported to be 60% to 70% overall [5], and >50% in even first-episode schizophrenia patients [1]. The pathological features of schizophrenic patients with depression symptoms, however, have not been clarified. To the best of our knowledge, the CC has not been applied as an identifying index of schizophrenia in first-episode, drug-naïve schizophrenic patients with depression symptoms.

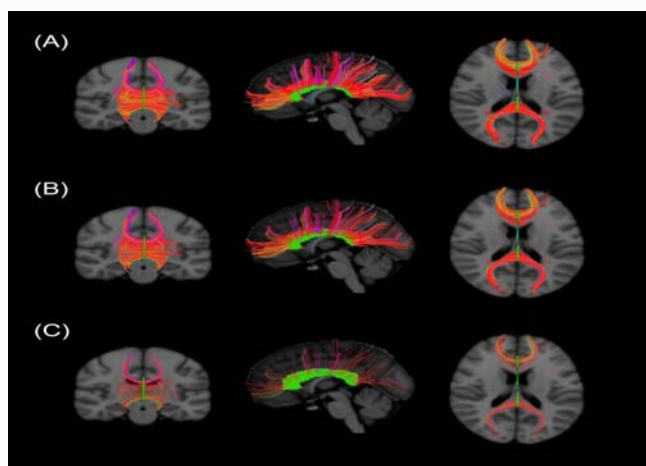
We conducted a pilot study from January 1st to October 1st of 2018 with the aim of exploring CC status in schizophrenic patients with depression symptoms to investigate whether it may be a pathological feature of this patient category. In the 10-month study period, we enrolled 18 first-episode, male drug naïve schizophrenia patients with depressive symptoms (FE-SCZ-D group) and 19 first-episode, male drug-naïve schizophrenia patients without depressive symptoms (FE-SCZ-nD group) matched for age, family history, and psychotic symptom severity. Ultimately, due to poor compliance, data from 13 patients were excluded, leaving 12 patients in the FE-SCZ-D group and 12 patients in the FE-SCZ-nD group in the final analysis. We enrolled age, gender, and family history matched Healthy Control (HC) samples to serve as a reference group. The social-demographic characteristics of each group are summarized in Table 1. All participants volunteered to participate in the study and written informed consent was acquired from the patients and their guardians. The Tianjin Mental Health Center provide ethics approval.

Tract-based spatial statistics of Magnetic Resonance Imaging (MRI) data showed that CC connections with the cerebral cortex in patients with schizophrenia were all reduced compared to healthy controls, with more extensive reductions being observed in the FE-SCZ-D group than in the FE-SCZ-nD group (Figure 1A-1C). Our finding that CC reductions in schizophrenics were more severe in the absence of depressive symptoms than in their presence contrary to the general logistic postulation. This counterintuitive phenomenon indicated us that major depressive symptoms, may be a protective factor of the CC reduction in schizophrenia patients. Hence, we hypothesize, based on multiple lines of evidence [5], that schizophrenia with depressive symptoms may be a special endophenotype of schizophrenia in which there is a characteristic alteration of CC reduction compared to the first episode drug naïve schizophrenia patients without depressive symptoms.

Many features of depression-type schizophrenia distinguish it from schizophrenia without depressive symptoms and from major depression. First, both longitudinal follow-up and cross-sectional findings have shown that depressive symptoms are highly prevalent amongst patients

Table 1: Social and demographic characteristics of the study groups.

Character	FE-SCZ-D	FE-SCZ-nD	HC	F/x ²	p
Age, years	25.1 ± 4.5	23.8 ± 2.3	24.5 ± 1.8	0.514	0.625
Gender males/females	12/0	12/0	12/0	NA	1
Illness duration months	2.5 ± 1.8	2.0 ± 1.2		0.462	0.66
Family history	None	None	None		
Positive and Negative Syndrome Scale score	83.5 ± 17.8	80.0 ± 12.4		0.323	0.758
Calgary Depression Scale for Schizophrenia score	14.5 ± 3.5	0			

**Figure 1:** Visual comparison of CC connections across groups based on tract-based spatial statistics of MRI data. (A) Healthy controls, (B) FE-SCZ-D, (C) FE-SCZ-nD.

with schizophrenia and are more pronounced during the early stages of schizophrenia. Second, the main symptoms of depression in people with schizophrenia are manifested as “shame, shyness, a difficulty in regaining confidence after recovery from paranoia, guilt, suicidal ideation, and a lack of motivation”. Third, the addition of antidepressant therapy to an antipsychotic regimen is only effective in a small portion of patients. Finally, structural and functional alterations have been described in schizophrenic patients with depressive symptoms that are not seen in schizophrenia patients without depressive symptoms or patients diagnosed with major depression [5]. The present results provide new evidence consistent with the existence of depression-type schizophrenia. In light of the available evidence, it is our supposition that depression-type schizophrenia is a subtype of schizophrenia, wherein schizophrenia is the core pathology.

This study had several limitations. First, the sample size was small. First-episode, drug-naïve schizophrenia patients are very difficult to find, and most of those we did find declined to participate in this research. All of the included patients were mandatory inpatients due to behavioral risks (e.g. due to imperative auditory hallucination) who did not accept any antipsychotic treatment before they were hospitalized. Second, because compliance is required for neuroimaging, the completeness of our MRI data was compromised. Third, our MRI scans were of limited scope and quality, producing only a rough view of the CC. Ideally, these limitations could be overcome in a multi-center study with more subtle neuroimaging data.

Acknowledgment

This work was supported by grants from the Tianjin Health Bureau Foundation (2014KR02 to C.Z.), National Natural Science Foundation of China (81871052 to C.Z.), and the Key Projects of the Natural Science Foundation of Tianjin, China (17JCZDJC35700 to C.Z.).

References

- David AS, Wacharasindhu A, Lishman WA. Severe psychiatric disturbance and abnormalities of the corpus callosum: review and case series. *J Neurol Neurosurg Psychiatry*. 1993;56(1):85-93.
- Sun J, Maller JJ, Daskalakis ZJ, Furtado CC, Fitzgerald PB. Morphology of the corpus callosum in treatment-resistant schizophrenia and major depression. *Acta Psychiatr Scand*. 2009;120(4):265-73.
- Williams MR, Sharma P, Fung KL, Pearce RK, Hirsch SR, Maier M. Axonal myelin increase in the callosal genu in depression but not schizophrenia. *Psychol Med*. 2015;45(10):2145-55.
- McCarthy-Jones S, Oestreich LKL, Lyall AE, Kikinis Z, Newell DT, Savadjiev P, et al. Childhood adversity associated with white matter alteration in the corpus callosum, corona radiata, and uncinate fasciculus of psychiatrically healthy adults. *Brain Imaging Behav*. 2018;12(2):449-58.
- Zhuo C, Song X, Li Y, Jing R, Tian H, Wang L, et al. Does depressive type Schizophrenia exist? How do we prove it? -An updated review and overview. *J Nerv Ment Dis*. 2019;207(5).