



## Primary Squamous Carcinoma of the Conjunctiva – Own Case Report

Justyna Izdebska<sup>1</sup>, Anna Siniarska<sup>1\*</sup>, Bożena Romanowska-Dixon<sup>2</sup> and Jacek P Szaflik<sup>1</sup>

<sup>1</sup>Department of Ophthalmology, Warsaw Medical University, Poland

<sup>2</sup>Department of Ophthalmology and Ocular Oncology, Jagiellonian University, Poland

### Abstract

We report a case of a patient with the primary squamous carcinoma of the conjunctiva. The lesion was covering the cornea and although it was not fully excised, after the surgery the cornea healed completely with no signs of carcinoma. There was performed surgical excision and histopathological examination of the material.

**Keywords:** Squamous carcinoma; Conjunctiva; Cornea

### Introduction

Primary squamous cell carcinoma of the conjunctiva is the most common ocular malignancy. Factors connected with higher rate of developing the lesion include UV light exposure, vitamin A deficiency, and chronic dust irritation with dust, chemical carcinogens and infection with Human Papilloma Viruses. It is a slow growing carcinoma that rarely results in distant metastases but it can cause local intraocular extension. Macroscopically it can appear as a leukoplakic, gelatinous, papilliform or nodular form. Treatment typically includes surgical resection with additional cryotherapy, and if necessary enucleation [1]. This report documents a case of a patient with squamous carcinoma of conjunctiva with very good postoperative result even though not fully excised.

### Case Presentation

In 2009, a 78-year old patient, with the diagnosis of corneal dystrophy of his right eye, was admitted to Ophthalmic University Hospital in Warsaw. Only myopia was previously diagnosed. The Best Corrected Visual Acuity (BCVA) of the right eye was 0.02, while BCVA of the left eye was 0.2. Examination of the right eye revealed reduced transparency of the cornea, irregular surface and superficial blood vessels in the superior-temporal quadrant. The left eye was within normal limits. Confocal microscopy showed altered morphology of the epithelium. The corneal morphology superiorly was not available for examination because of hyper-reflective tissue. Centrally the hyper-reflective tissue was limited to stroma; the endothelium was visible in some areas and had normal morphology. The endothelial cells density was 2,300/mm<sup>2</sup>. Inferiorly the cornea was within normal limits (Figure 1 and 2).

The patient was referred for further investigations and consultations but he did not come until May 2015. On this occasion he was referred because of a palpebral lesion of his right eye. The patient admitted that the vision of his right eye has been poor for a long time and he had noticed the

### OPEN ACCESS

#### \*Correspondence:

Anna Siniarska, Department of  
Ophthalmology, Warsaw Medical  
University, Sierakowskiego 13, 03-709  
Warsaw, Poland,  
E-mail: annabielecka84@gmail.com

Received Date: 04 Mar 2019

Accepted Date: 26 Mar 2019

Published Date: 01 Apr 2019

#### Citation:

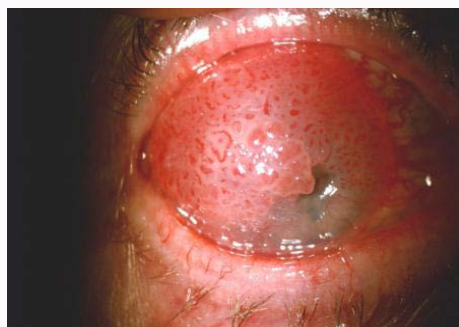Izdebska J, Siniarska A, Romanowska-Dixon B, Szaflik JP. Primary Squamous Carcinoma of the Conjunctiva – Own Case Report. *Ann Clin Case Rep*. 2019; 4: 1633.

ISSN: 2474-1655

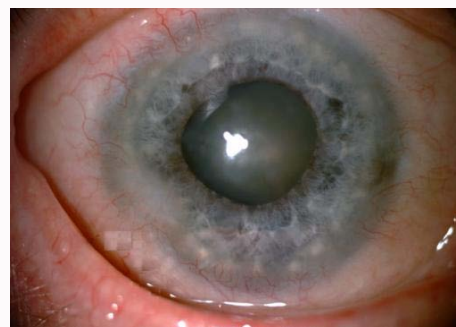Copyright © 2019 Anna Siniarska. This is an open access article distributed under the Creative Commons Attribution License, which permits unrestricted use, distribution, and reproduction in any medium, provided the original work is properly cited.




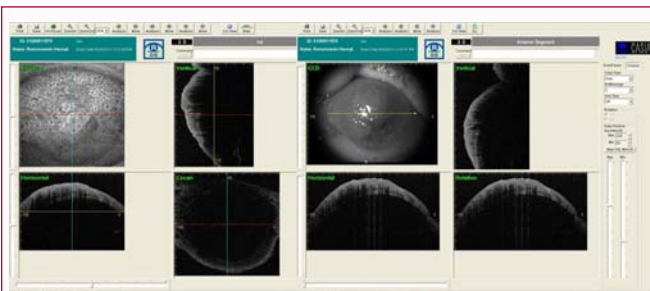
Figure 1 and 2: Confocal microscopy image.



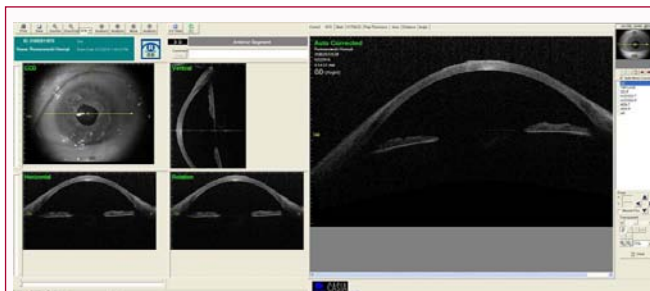
**Figure 3:** Photography of the right eye before the surgery (19.05.2015).



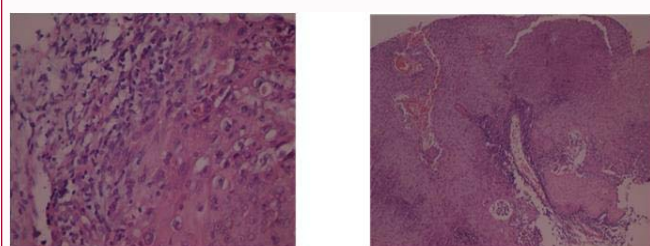
**Figure 7:** Photography of the right eye after the surgery (2.05.2016).



**Figure 4:** AS-OCT image (CASIA 1).



**Figure 8:** AS-OCT image (CASIA 1).



**Figure 5 and 6:** Microscopic examination of squamous carcinoma.

lesion on his right eye approximately 4 years ago. The vision of the right eye was light perception; the vision acuity of the left eye was 0.03. Examination of the right eye showed superficial hyperaemia, with mucosal discharge, anterior segment examination revealed a conjunctival papillary tumour covering the cornea almost entirely (Figure 3). Normal corneal morphology was only seen in a small area inferiorly. The eye had full motility. A cataract was diagnosed in the left eye. The fundus was within normal limits apart from myopic changes.

Patient was sent for further investigations. Ultrasonography of the eyes showed staphylomata of both eye balls without any other abnormalities. Anterior Segment Optical Coherent Tomography (AS-OCT CASIA 1) could not visualize the depth of penetration of the lesion. We were not able to assess if the carcinoma was only superficially covering the cornea or if intracorneal invasion was present (Figure 4).

A biopsy was taken and the diagnosis of planar epithelium with signs of dysplasia was made. Squamous carcinoma could not be excluded.

Patient was qualified for surgical excision of the lesion with application of mitomycin C and amniotic membrane transplantation. The surgery took place on 9.10.2015. Excised tissues were sent

for histopathologic examination. The surgeon excised as much pathological tissue as was possible. Because of the extensive nature of the lesion there was suspicion that some pathological tissue could remain in the cornea.

During follow-up visits we observed proper healing; however the cornea remained hazy with an irregular surface. Histopathologic examination of the surgical specimen gave the diagnosis of squamous carcinoma. There was present infiltration of inflammatory cells specially lymphocytes (Figure 5 and 6).

In February 2016 the patient was re-admitted to the hospital for cataract extraction of the left eye. On clinical examination the cornea of the right eye treated for carcinoma was clear with only slight superficial blood vessels on the periphery. There were no signs of carcinomatous tissue (Figure 7). The visual acuity remained low at the level of 0.01 due to cataract and myopic changes of the fundus. Anterior segment optical coherent tomography revealed normal morphology of the cornea; pachymetry was within normal limits without any abnormal changes in the cornea (Figure 8). Up to May 2016 (7 months post-operatively) cornea remained clear without signs of recurrence.

## Discussion

This case seemed interesting because the carcinoma was not fully excised during surgical procedure. Such a good postoperative result with clear and transparent cornea was not expected. We could consider that in this case some immunological reactions may be involved. It has been accepted that the immune system plays an important role in cancer development because tumour cells evade immune surveillance by exploiting inhibitory checkpoint pathways that suppress anti-tumour T-cell responses [2,3]. As a result of these conclusions immune-based therapies have emerged as the treatment for cancer. The immune system can identify and eliminate tumour cells based on their expression of Tumour-Associated Antigens

(TAA) through process called immune surveillance [2]. Many cytokines and immune cells are involved in recognizing and fighting against cancer cells. Among them, cytotoxic CD8+ cells are actively engaged in attacking tumour cells. Head and Neck Squamous Cell Carcinoma (HNSCC), which includes our patient's cancer, are considered an immunosuppressive disease. Immunosuppressive individuals are prone to develop HNSCC [2]. New evidence suggests that the host immune system has the ability to recognize a specific subpopulation of tumour cells - Cancer Stem Cells (CSCs) that are responsible for expanding a tumor. The immune system initiates an immune response, including Natural Killers (NK) cells that may target CSCs [2,4]. Is that kind of immune reaction happening in the case of our patient? The answer to this question remains unclear. We can only assume that the immune system could have played role in eliminating cancer that was not completely surgically excised.

## References

1. Coroi MC, Rosca E, Mutiu G, Coroi T. Squamous carcinoma of the conjunctiva. *Rom J Morphol Embryol*. 2011;52(Suppl 1):513-5.
2. Economopoulou P, Perisanidis C, Giotakis EI, Psyrris A. The emerging role of immunotherapy in head and neck squamous cell carcinoma (HNSCC): anti-tumor immunity and clinical applications. *Ann Transl Med*. 2016;4(9):173.
3. Zou W, Chen L. Inhibitory B7-family molecules in the tumour microenvironment. *Nat Rev Immunol*. 2008;8:467-77.
4. Jewett A, Tseng HC, Arasteh A, Saadat S, Christensen RE, Cacalano NA. Natural killer cells preferentially target cancer stem cells; role of monocytes in protection against NK cell mediated lysis of cancer stem cells. *Curr Drug Deliv*. 2012;9(1):5-16.