



## Primary Malignancy of Breast, Ovary & Skin - An Unusual Association

Mamta Rath Datta\* and Mousumi Das Ghosh

Department of Obstetrics & Gynecology, Tata Main Hospital, Jamshedpur, India

### Abstract

Association of three primary malignancies - breast carcinoma followed by ovarian Endometrioid adenocarcinoma and basal cell carcinoma is an unusual association. We report a case where a 76-year-old female developed ovarian Endometrioid adenocarcinoma and basal cell carcinoma of skin, eight years after the surgery for breast carcinoma (*in situ*).

**Keywords:** Cancer; Breast; Ovary; Skin

### Introduction

The association between breast, ovarian and skin malignancy is not reported. There are very few studies, which state that there is an association between epithelial ovarian and skin malignancy. However, association of three primary malignancies- breast, ovarian and skin in a patient with no family history of malignancies is not reported. We report a case of three primary malignancies in a 76-year-old Indian woman.

### Case History/Examination

Mrs. PM, 76-year-old woman attended OPD on April 16<sup>th</sup>, 2017 with abdominal distension and loss of appetite for 1 year. She had history of three previous vaginal deliveries. She used Copper T for contraception and attained menopause at the age of 49 years. She was diabetic and her blood sugar levels were controlled with Tab Metformin 500. She had Mastectomy (right) breast for ductal carcinoma in situ eight years back (at the age of 68 years). She was on regular follow up for the same. The patient had no history of malignancy in first or second-degree relatives. On examination, there was a large pelvic mass of 15 cm × 13 cm, irregular, firm in consistency with restricted mobility. On speculum examination- cervix and vagina was healthy. There was an ulcer in right hypochondrium- 2 cm × 2 cm. Skin biopsy was done and this showed superficially invasive basal cell carcinoma.

### Investigation and Treatment

**Investigation:** Ultrasound abdomen & pelvis showed large heterogeneous lesion 15.8 cm × 12 cm with cystic areas and significant vascularity within. Uterus and ovaries could not be visualized separately. CT abdomen & pelvis showed large solid cystic pelvic mass 16.5 cm × 12 cm × 12 cm with mild bilateral hydronephrosis. There was no lymphadenopathy or ascites. Tumor markers were as follows- Serum cancer antigen (CA-125) was elevated (191.5 U/ml), Alpha Feto Protein (AFP) was on higher side of normal (4.46) and Carcinoembryonic Antigen (CEA) was normal (1.98). Complete blood count and other routine investigations were normal. Chest X-ray & KUB was normal. These findings suggested possibility of malignant ovarian neoplasm.

### Treatment

After preoperative anesthesia clearance, laparotomy with total abdominal hysterectomy with bilateral salpingo-oophorectomy and comprehensive surgical staging was done. And basal cell carcinoma excision was done under general anesthesia. Uterus was 10 weeks' size with right sided bosselated irregular fleshy vascular mass extending up to lateral pelvic wall (Figure 1). Wide local excision of ulcerated lesion over anterior abdominal wall was done - 2.5 cm × 2 cm (Figure 1). She received packed cell transfusion- 2 units for anemia. Postoperative recovery was good.

Grossly, uterus was attached with left tube and ovary and measured 12.5 cm × 7 cm × 5 cm. Right ovarian mass was cream and yellow colored and had congested surface with multiple smooth cystic and solid nodular projections. Left ovary measured 4 cm × 1 cm × 0.5 cm. Cut section showed multiple cysts in endocervix and a myometrial fibroid in the fundus measuring 4.6 cm × 3.7 cm

### OPEN ACCESS

#### \*Correspondence:

Mamta Rath Datta, Department of  
Obstetrics & Gynecology, Tata Main  
Hospital, Jamshedpur, Jharkhand,  
831001, India,  
E-mail: drmamtadatta@gmail.com

**Received Date:** 16 Nov 2020

**Accepted Date:** 22 Dec 2020

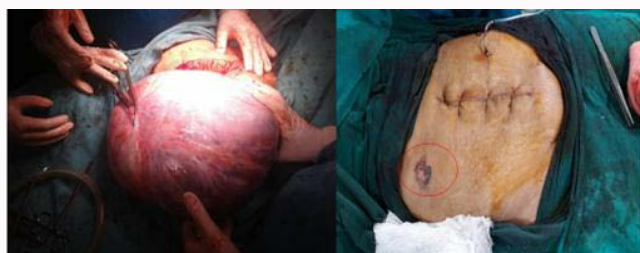**Published Date:** 28 Dec 2020

#### Citation:

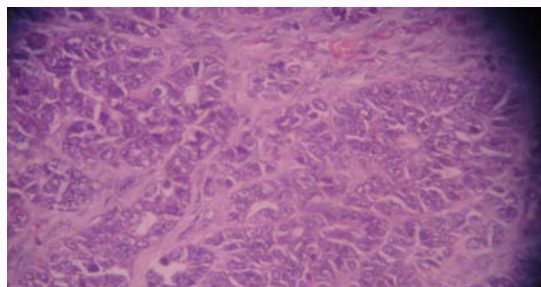
Datta MR, Ghosh MD. Primary  
Malignancy of Breast, Ovary & Skin -  
An Unusual Association. *Ann Clin Case  
Rep.* 2020; 5: 1901.

**ISSN: 2474-1655**

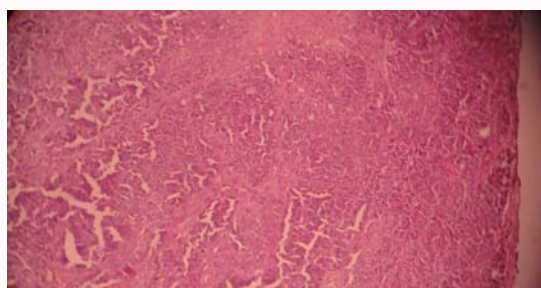
**Copyright** © 2020 Mamta Rath  
Datta. This is an open access article  
distributed under the Creative  
Commons Attribution License, which  
permits unrestricted use, distribution,  
and reproduction in any medium,  
provided the original work is properly  
cited.



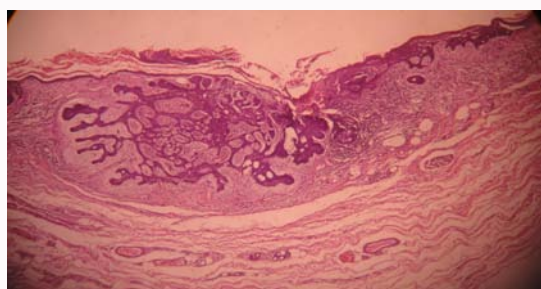
**Figure 1:** Ovarian tumor and Skin lesion.



**Figure 2:** Ovarian mass shows cellular tumor comprised of pleomorphic epithelial cells arranged in complex glandular & solid sheet pattern (H&E x100).

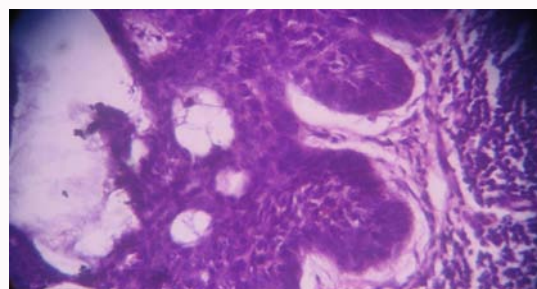


**Figure 3:** Ovarian mass shows irregular glands lined by hyperchromatic, enlarged nuclei, clumped chromatin, prominent nucleoli, scanty cytoplasm (H&E x400).



**Figure 4:** Skin lesion, shows squamous epithelial lining with sub epithelial nodular proliferation of basaloid cells (H&E x100).

× 5 cm cream colored with whorled appearance. The tumor had multiple cystic areas, few hemorrhagic, few mucinous and solid areas with small necrotic focus. The fibro fatty tissue covered with skin on one surface measured 5 cm × 4.5 cm × 2 cm. Skin showed area of ulceration measuring 2.5 cm × 1.5 cm. Histopathology report showed poorly differentiated Endometrioid adenocarcinoma of the ovary with large areas of solid growth (>50%), abundant mitotic figures (4-7/HPF) and large areas of ischemic necrosis. Capsule was intact



**Figure 5:** Skin lesion, shows nests of uniform basaloid epithelial cells with focal nuclear overcrowding, mild nuclear atypia & artificial cleft retraction (H&E x400).

(Figure 2,3). Omental tissue was not involved by the tumor. The right tube showed presence of mild intraepithelial atypia with no tumor involvement. The other ovary and tube showed normal histology. Uterus showed non secretory glands with simple cystic hyperplasia and a benign leiomyoma. The lymph nodes were free of tumor. The skin biopsy report was superficially spreading Invasive basal cell carcinoma. Depth of invasion was 0.3 mm (only superficial dermis). The margins were free and no lymphovascular emboli was found (Figure 4,5). She received six cycles of Chemotherapy (Carboplatin, Paclitaxel). CT abdomen & pelvis was normal. She was on regular follow up for 2 years but was lost to follow up after that.

## Discussion

The probability of second primary cancer after primary breast cancer diagnosis was studied in Israeli women from 1992 to 2006. Barbara G Silverman concluded that the probability of second malignancy was 3.6% within 5 years, 8.2% within 10 years and 13.9% within 15 years [1]. Women younger than 50 years of age at initial diagnosis were at greater risk than those above 50. Significantly increased risks of colorectal, uterine, lung, ovarian, thyroid cancers were noted along with leukemia [1].

In our case, the patient was 68 yrs old during breast cancer diagnosis. Though her probability for second primary cancer was low, she had both ovarian and skin cancers. Ovarian endometrial adenocarcinoma coexists with endometriosis in 15% cases and may have synchronous endometrial hyperplasia or carcinoma. In our case there was no endometrial involvement. One-sided ovary was involved and there was no ascites. The cancer was stage 1 A according to FIGO staging classification 2014. After debulking surgery, she received chemotherapy. There was a skin lesion showing superficially spreading basal cell carcinoma. The association between ovarian and skin is not well understood. Catharina C van Niekerk et al. [2] using the Dutch nationwide pathology database concluded that patients with epithelial ovarian malignancies showed an increased risk of skin cancer. There are studies which show that there is a risk of subsequent cancer after diagnosis of basal cell carcinoma. Patients with basal cell carcinoma have an increased risk for non-cutaneous cancer like breast cancer, non-Hodgkin's lymphoma and testicular cancer. [3]. Also increase in cancers of salivary gland, lip, small intestine, nose and pharynx was observed in Finland study [4]. Breast cancer survivors tend to be more intensive users of medical services than other women their age. Specialist and primary care providers must take advantage of this continued contact to educate patients about their risk for second cancers and implement appropriate preventive and screening procedures tailored to their patients' individual risks. Association with breast carcinoma in situ followed by ovarian

endometrial adenocarcinoma and basal cell carcinoma is an unusual association and is not reported.

## Synopsis

Association of three primary malignancies - breast carcinoma followed by ovarian Endometrioid adenocarcinoma and basal cell carcinoma is an unusual association.

## References

1. Barbara Silverman G, Irena L, Keinan-Boker L. Second primary cancers after primary breast cancer diagnosis in Israeli women, 1992 to 2006. *J Glob Oncol.* 2016;3(2):135-42.
2. Catharina van Niekerk C, Johan Bulten, André Verbeek LM. Epithelial ovarian cancer and the occurrence of skin cancer in the Netherlands: Histological type connotations. *ISRN Obstet Gynecol.* 2011;2011:617082.
3. Frisch Hjalgrim H, Olsen JH, Melbye M. Risk for subsequent cancer after diagnosis of basal-cell carcinoma. *Ann Intern Med.* 1996;125(10):815-21.
4. Mil'an T, Pukkala E, Verkasalo PK, Kaprio J, Jansén CT, Koskenvuo M, et al. Subsequent primary cancers after basal-cell carcinoma: A nationwide study in Finland from 1953 to 1995. *Int J Cancer.* 2000;87(2):283-8.