



## Neuro-anatomical Approach to the Humano-Murian Brain Based on Cerebral Imaging Studies

Sérend Hipe\*

IFPEA, Rue des Saint-Pères, 75 006 Paris, France

### Abstract

We present the case of a humano-murian victim of a left stroke who presented with impaired motor skills on the left side of his body. Brain imaging studies (Scan, Pet Scan) have shown that the brain is functionally separated into two parts. The white corners and the corpus callosum are calcified and leave almost no possibility for inter-hemispheric communication as is the case for us. Basically, the entire anatomical substrate that allows our human brain to communicate between the two hemispheres is completely inactivated in humano-murians. It is among the latter that the term diencephalon takes on its full meaning.

**Keywords:** Human brain; Scan studies; Humano-murian; Motor skills; Corpus callosum

### Introduction

We present a case study of anatomical pathology by medical imaging after having been able to study a case of humano-murian hospitalized after a stroke with loss of sensitization of the right hemi-body, associated motor disorders (hemiplegia) and anosognosia that will give way after a few days. The patient was 78 years old, male and in possession of all means prior to the stroke.

### Methodology

Our recent research has shown that humano-murians have two brains. Understand that they do not have two brains in the skull, but that their brains are functionally separated into two parts.

The white corners and the corpus callosum are calcified (Figures 1 and 2) and leave almost no possibility for interhemispheric communication as is the case for us. Basically, the entire anatomical substrate that allows our human brain to communicate between the two hemispheres is totally inactivated in humano-murians. It is in the latter that the term diencephalon takes on its full meaning.

This has considerable consequences on their brain and sensory capacities. Indeed, on the motor level, there is no longer any lateral predominance, so all humano-murians are completely ambidextrous. Their movements sometimes seem wider to us while, paradoxically, they are 3 permanently parasitized by a slight tremor that we had mistakenly taken for one of the effects of the polar cold that reigns on the Wall. These tremors are similar to Parkinson's movements. As a result, there is no pyramidal decussation (Figures 3 and 4), so motor skills are controlled by the homolateral cerebral hemisphere, which is not the case in humans (in whom the right hemibody is controlled by the motor cortex of the left cerebral hemisphere). The human-murian has developed frightening motor qualities by being able to dissociate the left hemibody and the right hemibody, which can carry out two different motor activities. to Ramón y Cajal, pyramidal decussation was related to that of sensory pathways: in the optic chiasma we also observe the decussation of a

### OPEN ACCESS

#### \*Correspondence:

Sérend Hipe, U-48/Laboratoire de l'IFPEA, IFPEA, Rue des Saint-Pères, 75 006 Paris, France, E-mail: hipe.ifpea@gmail.com

Received Date: 29 Jan 2025

Accepted Date: 13 Feb 2025

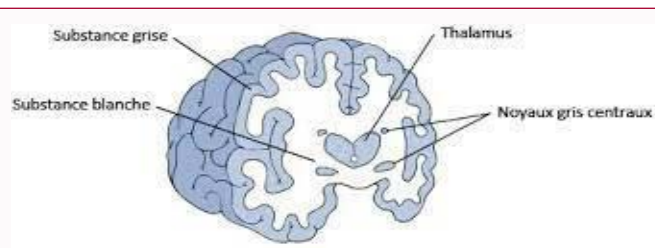
Published Date: 17 Feb 2025

#### Citation:

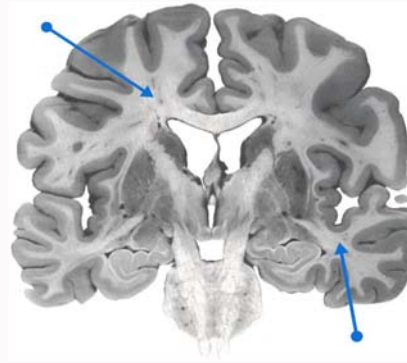
Sérend Hipe. Neuro-anatomical Approach to the Humano-Murian Brain Based on Cerebral Imaging Studies. *Ann Clin Case Rep.* 2025; 10: 2721.

ISSN: 2474-1655.

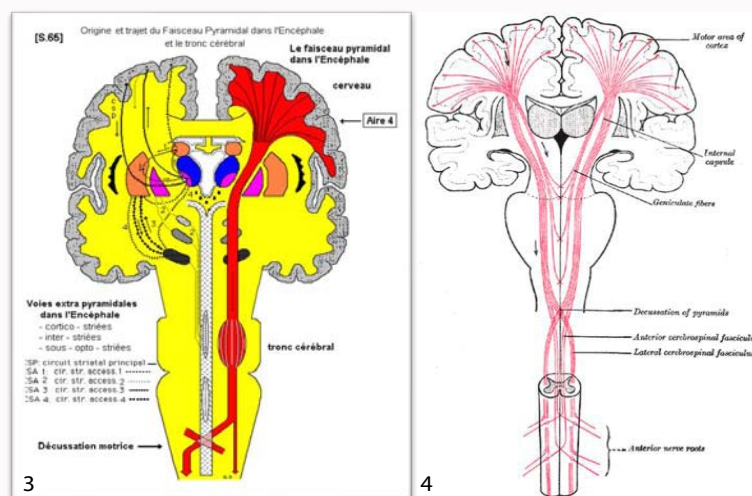
Copyright © 2025 Sérend Hipe. This is an open access article distributed under the Creative Commons Attribution License, which permits unrestricted use, distribution, and reproduction in any medium, provided the original work is properly cited.



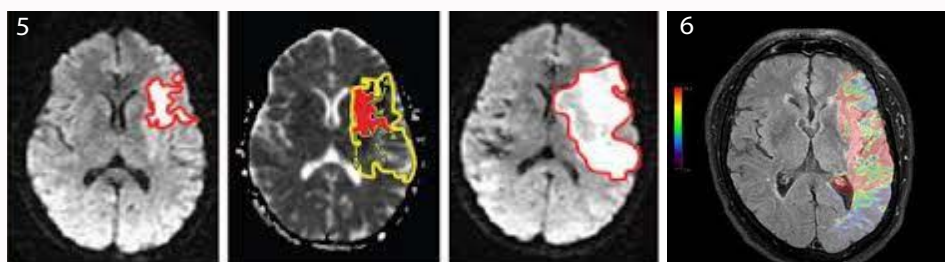
**Figure 1:** The white matter allows the communication of the two cerebral hemispheres. It is totally calcified in Humano-Murians.



**Figure 2:** White matter makes up a large proportion of the brain. Its difference in mineral composition between that of humans and human-murians makes it a unique cerebral constitution.



**Figure 3 and 4:** Pyramidal decussation.



**Figures 5 and 6:** MRI images after stroke: significant initial temporo-parieto-occipital involvement, the last images (top) show a very rapid resorption.

large part of the optic nerve fibers, 4 which adapts to perception by allowing both hemispheres to have complete information about what both eyes perceive and can generate complete images that can be located in space. In this sense, the displacement necessary to react to a possible threat would be that of muscle groups, unlike the part of the brain that perceives them. If there is no pyramidal discussion, the information would first go to the other hemisphere, then process and react, which would be slower. This explains the particularity of the motor reactions of humano-murians, which we had initially taken as an almost constitutional nonchalance.

**Results**

Each left and right "brain" has thus developed its own potential independently. If humano-murians use a very particular type of

communication that we have described previously (message 15), it is now certain that it stems from this anatomophysiological difference. Human-Murian communication is a mixture of a powerful process of empathy that transmits intentions, images, and emotions to the interlocutor, before verbal language expresses the thought formulated in words. A communication by double channel, a verbal channel coupled with a cognitive channel, knowing that on the latter we humans are very good receivers to our Murian friends but are unable to activate it ourselves. The impression we have is to hear in a way within ourselves what the lips of humano-murians will pronounce with a slight delay. This seems to us to function as a preform of telepathy and allows almost any human to understand very quickly the humano-murian language and its multiple dialects all around the Wall. This mode of communication uses both a very organic substrate

and follows primitive phylogenetic pathways (use of pheromone cloud as we have previously demonstrated) and very elaborate thought processes, similar to the secondarized psychic processes of the human psyche.

The patient who allowed us to discover these anatomical and physiological elements is in a way our "patient 1" whose portrait we are sending you (Figures 5 and 6). This humano-murian had indeed been the victim of a left stroke and had a motor impairment on the left side of his body (left hemiplegia, facial paralysis and oculomotor muscles of the left orbit) which seemed impossible to us. His name, Solpinan, will forever be associated with this discovery.

## Conclusion

This is a case study of a human-murian who suffered a left stroke and had a motor impairment on the left side of his body. Brain imaging examinations (Scan, Pet Scan) have shown that the brain is functionally separated into two parts. The white matter and corpus callosum are calcified and leave almost no possibility of inter-hemispheric communication as is the case in the human brain. Basically, the entire anatomical substrate that allows our human brain to communicate between the two hemispheres is totally inactivated in humano-murians. It is among the latter that the term diencephalon takes on its full meaning.