



Medullary Compression by Solitary Bone Plasmacytoma

Ivan Cadena Vélez*, Sara Nicolau, Marta Valentim, Manuela Grego and Luis Siopa

Department of Internal Medicine, Hospital Distrital de Santarém, Portugal

Abstract

Bone solitary plasmacytomas are rare tumors. About 2/3 of patients with solitary bone plasmacytoma will develop multiple myeloma at some point in life. Solitary spinal plasmacytomas are usually found in the thoracic and lumbar spines, more rarely at cervical levels. Like other vertebral masses, solitary plasmacytomas give rise to spinal cord compression, which causes irritative symptoms and deficits. With this case, our objective was to report a rare case of solitary plasmacytoma intraosseous with neurological manifestations neurological for medullary compression.

Keywords: Plasmacytoma; Monoclonal gammopathy; Medullary compression

Introduction

Plasma cell neoplasia may present as an isolated lesion (plasmacytoma) or multiple lesions (multiple myeloma) and is characterized by irreversible proliferation of a plasmocyte clone producing a monoclonal immunoglobulin [1]. Solitary plasmacytoma is a relatively uncommon tumor that, unlike multiple myeloma, has a single proliferative clone of monoclonal plasma cells. It may be extraosseous or intraosseous. Extramedullary plasmacytoma can be found in the airways, oral cavity, gastroenterology, lymphatic system, spleen, vagina, pancreas, parotid gland, thyroid, testis, or breast. The most common site of solitary plasmacytoma is in the spine (50% of cases) [2]. We report here a case of solitary spinal plasmacytoma with disabling neurological manifestations in which the diagnosis was made with blood electrophoresis correlated with bone biopsy and imaging.

Case Presentation

A 65-year-old woman admitted to the inpatient care facility for 4 months with sudden onset low back pain after physical exertion, with worsening low back pain from right lower limb radiating pain accompanied by paresthesia and disabling gait that improves with the supine position. On neurological examination, she was sensitive, attentive, oriented in time and space. Grade 4 muscle strength in the lower limbs and normal in the upper limbs. Deep and normal upper limb reflexes in lower limbs. Deep hypoesthesia with S1 level. Impaired balance and motor coordination in upper limbs, normal motor coordination in upper limbs, and cranial nerve semiology, including fundus without abnormalities. No stiff neck or other signs of meningeal irritation. During the course of the exams, he underwent a sacred lumbar spine CT scan that revealed “an aggressive behavioral lesion occupying soft tissue space eroding S1s body, extending to the left, with 71 mm × 44 mm largest lateral by longitudinal diameter 40 mm larger anterior-posterior diameter, extending to the anterior epidural space, with compression of the sacred roots in the sacred canal associated with partial collapse of the vertebral body S1, related to said osteolytic lesion” (Figure 1). By presenting signs of spinal cord compression due to aggressive single behavior injury, he initiates therapy with dexamethasone 12 mg IV at an initial dose, followed by 4 mg 8/8 h.

There were no abnormalities to be highlighted in the laboratory; notably, anemia and changes in renal or ionic function were absent. In the course of inpatient analysis, protein electrophoresis revealed an IgG Kappa monoclonal gammopathy (Kappa Chains 906.2 mg/L) confirmed by immunofixation. The patient underwent bone biopsy and a myelogram that confirmed the presence of solid, reticular pattern neoplasia consisting of CD138 and CD56 positive monotonic small cells. In the study of immunoglobulin light chains, the restriction of kappa chains resulted in morphological findings compatible with plasmacytoma. In view of this result, he initiated antalgic radiotherapy (8 sessions of 50 cGy) to improve the motor and sensory deficit due to spinal cord compression associated with bortezomib 2.1 mg SC. A regular two-year follow-up showed the constant absence of neurological signs and symptoms and a laboratory response.

Discussion

A solitary bone plasmacytoma is rare tumor, representing 3% to 7% of myelomas. Its differential

OPEN ACCESS

*Correspondence:

Ivan Cadena Vélez, Department of Internal Medicine, Hospital Distrital de Santarém, Av. Bernardo Santareno 3737B, 2005-177, Santarem, Portugal, Tel: 914040788;

E-mail: icadenavelez@gmail.com

Received Date: 10 Jan 2020

Accepted Date: 04 Feb 2020

Published Date: 08 Feb 2020

Citation:

Vélez IC, Nicolau S, Valentim M, Grego M, Siopa L. Medullary Compression by Solitary Bone Plasmacytoma. *Ann Clin Case Rep.* 2020; 5: 1796.

ISSN: 2474-1655

Copyright © 2020 Ivan Cadena

Vélez. This is an open access article distributed under the Creative Commons Attribution License, which permits unrestricted use, distribution, and reproduction in any medium, provided the original work is properly cited.

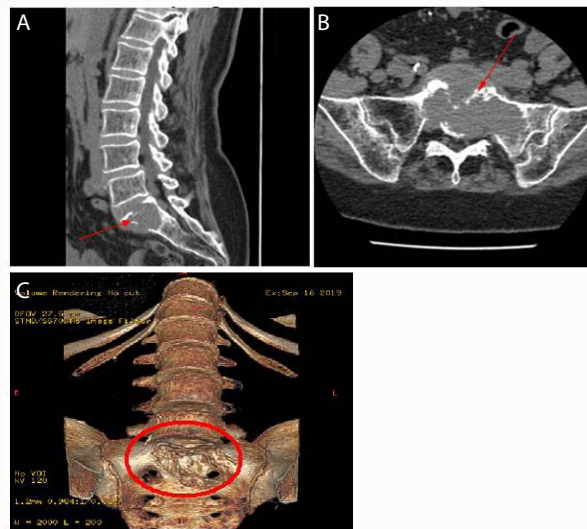


Figure 1: Lesion occupying soft tissue space eroding S1s body, extending to the left, with 71 mm x 44 mm largest lateral by longitudinal diameter 40 mm larger anterior-posterior diameter, extending to the anterior epidural space (A/B), with compression of the sacral roots in the sacral canal associated with partial collapse of the vertebral body S1, related to said osteolytic lesion (C).

diagnosis is mainly made with non-Hodgkin's lymphoma [3,4]. No more than 5% of patients with plasmacytoma have a solitary bone plasmacytoma. This diagnosis requires criteria ranging from a single area of bone destruction by a plasma cell clone, such as bone marrow with no evidence of plasma cell proliferation, normal findings of other bone sites, the absence of anemia, hypercalcemia, or renal dysfunction attributed to myeloma [5]. About 2/3 of patients with solitary bone plasmacytoma will develop multiple myeloma at some point in life, at different times of progression, and may occur even long after plasmacytoma treatment [6].

The initial age ranges from 33 to 70 years, with an average of 46, lower than that of multiple myeloma (59 years). According to published evidence, 2% to 10% of multiple myeloma cases show the typical clinical signs and symptoms of solitary plasmacytoma [7,8], and some authors believe that solitary myeloma is simply the first location of a progressing plasma cellular neoplasm, natural for the spread, and then for multiple myeloma. Although the clinical course of multiple myeloma is usually rapid and fatal, patients with plasmacytoma may have a 10-year survival rate of 68%, despite possible disease progression [1]. The following criteria must be met for the diagnosis of solitary plasmacytoma:

1. Presence of a solitary bone tumor.
 2. Biopsy showing plasma cell histology.
 3. Absence of myeloma cells on bone marrow examination.
 4. Absence of anemia, hypercalcemia or renal impairment.
 5. Absence of monoclonal component or low monoclonal component in serum electrophoresis, and
 6. Normal immunoglobulin levels after surgical or radiotherapy treatment [9].
- The diagnosis of solitary myeloma cannot be made with absolute certainty, as it must be distinguished from multiple occult myelomas and must be confirmed by follow-up. Solitary spinal plasmacytomas are usually found in the thoracic and lumbar spines and, more rarely, at cervical levels. Like other vertebral masses, solitary plasmacytomas give rise to spinal cord compression,

which causes irritative symptoms and deficits. Irritative symptoms are pain (root, if nuclear and vertebral) and paresthesias; deficits are motor (due to a peripheral neuron or pyramidal tract injury) and, more rarely, sensory.

The clinical case presented here begins with symptoms of a relapsing-remitting course that worsened with a disabling neurological symptom progression associated with somatic pain. It manifested by low back pain that was refractory to medical treatment, perhaps due to the slow growth of the neoplastic mass and compensatory characteristics of the spinal cord at the lumbar level. The most important part of this case is to define fundamental aspects that characterize the solitary bone plasmacytoma, a rare but well-known entity, considering its evolution in most cases to multiple myeloma, a prognostically dark disease. Serum protein electrophoresis and immunoelectrophoresis are essential for the diagnosis, as these laboratory parameters are the only ones that can be altered they are also reliable tools for disease monitoring and prognosis. The correct interdisciplinary approach, in this case, based on a clinical, radiological, and immunological examination, allowed operation with a suspected diagnosis of plasmacytoma.

Conclusion

Solitary plasmacytoma, although rare, should be remembered as a differential diagnosis of other conditions so that the correct treatment can be instituted, with the aim being early disease control and a better survival rate.

References

1. Jaffe ES, Harris NL, Stein H. World Health Organization Classification of Tumours. Pathology and genetics of tumours of haematopoietic and lymphoid tissues. Lyon: ARC Press France. 2001.
2. Kirshenbaum G, Rhone P. Solitary extra-medullary plasmacytoma of the breast with serum monoclonal protein: a case report and review of the literature. *Am J Clin Pathol.* 1985;83(2):230-2.
3. Segas J, Skoulakis H, Katrinakis G, Tzardis M. Solitary extramedullary plasmacytoma of the oropharynx: A rare location. *Ear Nose Throat J.* 1993;72(11):743-5.

4. Maniglia A, Xue JW. Plasmacytoma of the larynx. *Laryngoscope*. 1983;93(6):741-4.
5. De Filippo M, Pogliacomì F, Albisinni U, Quinto S, Bocchi C, Sverzellati N, et al. Occult large epiphyseal solitary plasmacytoma at multidetector row computer tomography detected by magnetic resonance imaging. *Acta Biomed*. 2008;79(3):240-5.
6. Knobel D, Zouhair A, Tsang RW, Poortmans P, Belkacémi Y, Bolla M, et al. Prognostic factors in solitary plasmacytoma of the bone: a multicenter Rare Cancer Network study. *BMC Cancer*. 2006;6:118.
7. Meyer Y, Schulz D. Solitary myeloma of bone: A review of 12 cases. *Cancer*. 1974;34(2):438-40.
8. Sheehan T, Sinclair D, Tansev P, O'donnell JR. The potential value of immuno-isoelectric focusing in the diagnosis and management of solitary plasmacytoma. *Clin Lab Haematol*. 1985;7(4):375-7.
9. Kyle RA, Rajkumar SV. Criteria for diagnosis, staging, risk stratification and response assessment of multiple myeloma. *Leukemia*. 2009;23(1):3-9.