



## Isolated Hypoglossal Nerve Palsy in a Patient with Non-Small Cell Lung Carcinoma: A Rare Paraneoplastic Neurological Syndrome

Himanshu Juneja<sup>1\*</sup>, Surekha Dabla<sup>2</sup>, Manoj Yadav<sup>1</sup>, Isha Pahuja<sup>1</sup>, Surender Kumar<sup>1</sup> and Pradyumna Kumar Singh<sup>1</sup>

<sup>1</sup>Department of General Medicine, Pandit Bhagwat Dayal Sharma Post Graduate Institute of Medical Sciences, India

<sup>2</sup>Department of Neurology, Pandit Bhagwat Dayal Sharma Post Graduate Institute of Medical Sciences, India

### Abstract

Paraneoplastic neurologic syndrome is a group of disorders resulting from damage to the nervous system in carcinoma, remote from primary site and not due to metastasis, infection, or metabolic complication associated with cancer. Patient with small cell lung cancer sometimes shows various paraneoplastic neurological syndromes, but patient with non-small cell lung cancer rarely shows paraneoplastic neurologic syndromes. Here we wish to report a case of 65-year-old female presented to our clinic with isolated right sided hypoglossal nerve palsy and poorly differentiated adenocarcinoma of lung.

**Keywords:** Paraneoplastic; Non-small cell lung carcinoma; Hypoglossal nerve

### Introduction

Hypoglossal nerve palsy is not an uncommon in neurological diseases but if it present as isolated cranial nerve palsy it is a diagnostic challenge. Isolated involvement is less common due to proximity of twelfth nerve to other cranial nerves and vessels. The causes of isolated hypoglossal nerve palsy are nasopharyngeal carcinoma, metastasis to the base of skull, carcinomatous meningitis, trauma, dolichoectasia of the vertebral artery, dissection of extracranial internal carotid artery, hypoglossal schwannoma, Epstein Barr virus infection, post vaccination cranial neuritis etc [1]. Paraneoplastic syndromes occur due to immune cross-reactivity between tumour cells and components of the nervous system. We diagnosed a case presenting with isolated hypoglossal nerve palsy as a paraneoplastic manifestation of poorly differentiated adenocarcinoma of lung.

### Case Presentation

A 65-year-old female presented with complaints of decreased appetite and loss of weight for 2 years and since last 1 month she started complaining of difficulty in speaking with abnormal deviation of tongue towards right side. There was no history of cough, haemoptysis, chest pain, and dyspnoea, hoarseness of voice, nasal regurgitation, facial deviation, numbness and weakness. General physical examination of patient was unremarkable except thin built and pallor. On central nervous system examination, higher mental functions of patient were within normal limits. Tongue was abnormally deviated towards right (Figure 1) with unilateral right sided atrophy and fasciculations at rest suggestive of right sided hypoglossal nerve palsy. Rest of the cranial nerves were intact. On motor examination bulk was reduced in all four limbs with power of 4/5 in all four limbs and deep tendon reflexes were 2+ in all limbs. Gait of patient was normal. Plantar response was flexor bilateral and there was no fasciculation in any limb. Sensory, cerebellar and extrapyramidal system examination with in normal limits. Rest of the systemic examination of patient was also normal.

Laboratory investigations revealed mild microcytic hypochromic anaemia with an Hb 9.2 gm/dl and raised erythrocyte sedimentation rate (ESR) of 60 mm in first hour. Renal function test of patient including blood urea, serum creatinine, serum calcium and phosphate were within normal limits. Liver function test of patient show raised level of alkaline phosphatase enzyme (ALP) 575 U/L with normal level of SGOT, SGPT and serum bilirubin. Chest x-ray of patient shows a lesion in upper lobe of right lung with mediastinal widening and bilateral hilar prominence (Figure 2).

### OPEN ACCESS

#### \*Correspondence:

Himanshu Juneja, Department of General Medicine, Pandit Bhagwat Dayal Sharma Post Graduate Institute of Medical Sciences, Haryana, India, Tel: +919728208283; E-mail: himanshu\_talkin@planetmail.net

Received Date: 21 Aug 2017

Accepted Date: 20 Oct 2017

Published Date: 24 Oct 2017

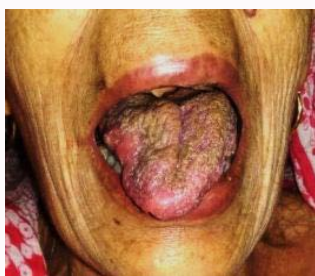#### Citation:

Juneja H, Dabla S, Yadav M, Pahuja I, Kumar S, Singh PK. Isolated Hypoglossal Nerve Palsy in a Patient with Non-Small Cell Lung Carcinoma: A Rare Paraneoplastic Neurological Syndrome. *Ann Clin Case Rep.* 2017; 2: 1454.

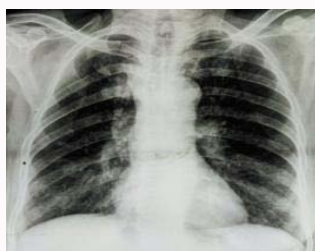ISSN: 2474-1655

Copyright © 2017 Himanshu

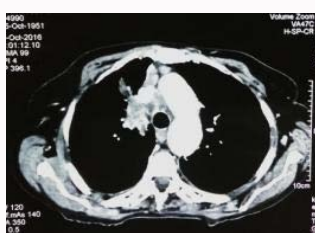
Juneja. This is an open access article distributed under the Creative Commons Attribution License, which permits unrestricted use, distribution, and reproduction in any medium, provided the original work is properly cited.



**Figure 1:** Showing abnormal deviation atrophy.



**Figure 2:** Chest X-Ray showing lesion in right side of Lung with mediastinal widening.



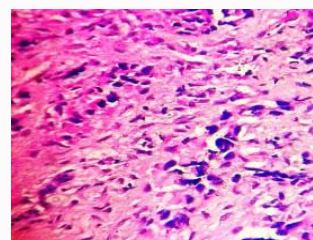
**Figure 3:** CECT Chest Showing mass lesion in right lung.

Contrast enhanced CT scan of chest and abdomen was done which revealed a heterogeneously enhancing lesion in upper lobe of right lung (Figure 3) with mediastinal lymphadenopathy and left adrenal mass.

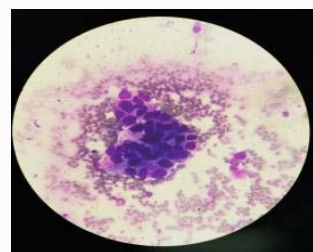
MRI brain and CECT neck with skull base revealed no brain, neck metastasis or bone erosions that could explain local hypoglossal nerve involvement. Patient underwent fibre optic bronchoscopy and endobronchial lung biopsy taken along with transbronchial FNAC (fine needle aspiration cytology). Histopathology and cytology report revealed poorly differentiated adenocarcinoma of lung (Figure 4). CSF fluid was acellular, no malignant cells were seen. Serum angiotensin converting enzymes (ACE) levels were within normal limits. To rule out paraneoplastic neurological syndrome, serum antineuronal antibody profile (anti-Hu, anti collapsin response mediating protein (CRMP)-5, anti-VGCC antibodies) was done (Figure 5). Anti-Hu antibodies was found positive. Patient was started on Erlotinib which is epidermal growth factor receptor inhibitor. After one month of treatment appetite of patient improved and patient also gain some weight but there was no improvement in hypoglossal nerve palsy.

## Discussion

Non-small cell lung carcinoma is the most common type of bronchogenic carcinoma in non-smokers, this type of carcinoma is slowly growing and usually peripheral in location. Non-small cell lung carcinoma tends to remain localized longer and have a slightly better prognosis than do the undifferentiated carcinoma of lung. The



**Figure 4:** Histopathological slide showing dysplastic cell suggestive of adenocarcinoma.



**Figure 5:** Transbronchial FNAC from Subcarinal Lymph Node showing groups of large dysplastic cells s/o carcinoma, non-small cell type.

incidence of paraneoplastic neurological syndrome in lung cancer is around 10% [2]. Paraneoplastic neurological syndromes are the neurological disorders caused by the remote effects of cancer. In response to the development of a tumour, some antineuronal antibodies form by the body against the neoplastic cells. These antibodies commonly known as onconeural antibodies. These antibodies and the T lymphocytes which are generated against onconeural antigen inadvertently attack both the tumour cells and normal nervous tissue. Isolated hypoglossal nerve palsy is a rare clinical finding and an ominous sign. Therefore, timely diagnosis of primary aetiology is of major importance. The hypoglossal nerve is a pure motor nerve that innervates the muscles of the tongue. It could be divided into 5 segments based on location: medullary (nuclear), cisternal (extramedullary intracranial), skull base (the segment which passes through the hypoglossal nerve canal), nasopharyngeal, oropharyngeal and carotid (in close vicinity to the glossopharyngeal and vagus nerve as well as to the internal carotid artery), and sublingual space (where its branches terminate innervating lingual muscles). The nerve can be involved anywhere along its course. Hence localization of site of lesion is very important. Occurrence of hypoglossal nerve palsy along with other cranial nerve involvement and pyramidal tract signs is not an uncommon finding. In a retrospective analysis of 100 hypoglossal nerve palsy cases, Keane J et al. [3] found that predominantly malignant tumours were the most common cause of hypoglossal nerve palsy (49 cases), whereas other causes were trauma, medullary infarctions, multiple sclerosis, Guillain-Barre neuropathy and infection. However, isolated hypoglossal nerve has been described in a few case reports and small case series but till date there is no such case report of paraneoplastic isolated hypoglossal nerve palsy in non-small cell lung carcinoma in the literature. Combarros et al. [4] reported 9 patients with isolated hypoglossal nerve palsy caused by tumours, Chiari malformation and dural arteriovenous fistula, whereas, in 4 patients, who had an excellent outcome, no cause was found. In maximum cases, the neurological disorder develops before the primary neoplasm becomes clinically evident, and the patient consults a neurologist for the same as in this case.

## Conclusion

Isolated hypoglossal nerve palsy is a rare clinical finding and an ominous sign which requires an intensive work-up to find out underlying aetiology. In our case the cause of hypoglossal nerve palsy seems to be anti-onconeural antibodies (anti-Hu antibodies) though, there is no such case report in literature.

## References

1. Boban M, Brinar VV, Habek M, Rados M. Isolated hypoglossal nerve palsy: a diagnostic challenge. *Eur Neurol*. 2007; 58: 177-1781.
2. Spiro SG, Gould MK, Colice GL. Initial evaluation of the patient with lung cancer: symptoms, signs, laboratory tests, and paraneoplastic syndromes: ACCP evidenced-based clinical practice guidelines (2nd edition). *Chest*. 2007; 132: 149-160.
3. Keane JR. Twelfth-nerve palsy. Analysis of 100 cases. *Arch Neurol*. 1996; 53: 561-566.
4. Combarros O, Alvarez de Arcaya A, Berciano J. Isolated unilateral hypoglossal nerve palsy: nine cases. *J Neurol*. 1998; 245: 98-100.