



Interventional Management of Chronic Low Back Pain Associated with Bertolotti's Syndrome: Report of Case Series

Rui Zhang* and Jianguo Cheng

Department of Pain Management, Anesthesiology Institute, Cleveland Clinic, Ohio, USA

Abstract

Background: Bertolotti's syndrome is a congenital variant with an enlarged transverse process of the L5 lumbar vertebra (lumbosacral transitional vertebra, LSTV), which articulates or fuses with the sacrum or ilium. It's believed that the presence of an LSTV increases the incidence of chronic low back pain and the severity of the pain. Its association with chronic low back pain is multifactorial, including biomechanical changes resulting from asymmetrical motion between the LSTV and the sacrum. The conventional conservative management that consists of physical therapy, activity modification, and medication may not be sufficient to provide satisfactory pain control due to the underlying congenital anatomical variance. Here we report 5 cases that were managed with interventional procedures for chronic low back pain associated with Bertolotti's syndrome.

Case Report: All the cases have failed to respond to conventional conservative management and were found to have Bertolotti's syndrome through radiographs. The pain generating mechanism varied among these five patients, which led to diverse clinic presentations and applications of various interventional procedures including epidural steroid injections, lumbar facet medial branch block and neurotomy, and sacroiliac joint injection and neurotomy.

Conclusion: In light of the diversity of clinical presentations, management of patients with Bertolotti's syndrome has to be highly individualized. Multimodal care, including interventional approaches, is often required based on clinical data, imaging, and diagnostic blocks.

OPEN ACCESS

*Correspondence:

Rui Zhang, Departments of Pain Management, Anesthesiology Institute, Cleveland Clinic, 9500 Euclid Avenue/ C25, Cleveland, Ohio 44195, USA, E-mail: Zhangr@ccf.org

Received Date: 10 Jan 2017

Accepted Date: 02 May 2017

Published Date: 04 May 2017

Citation:

Zhang R, Cheng J. Interventional Management of Chronic Low Back Pain Associated with Bertolotti's Syndrome: Report of Case Series. *Ann Clin Case Rep.* 2017; 2: 1348.

ISSN: 2474-1655

Copyright © 2017 Rui Zhang. This is an open access article distributed under the Creative Commons Attribution License, which permits unrestricted use, distribution, and reproduction in any medium, provided the original work is properly cited.

Introduction

Bertolotti's syndrome refers to a congenital variant with an enlarged transverse process of the L5 lumbar vertebra (lumbosacral transitional vertebra, LSTV), which articulates or fuses with the sacrum or ilium. Its correlation with low back pain was first described in 1917 by the Italian physician Mario Bertolotti. The prevalence of Bertolotti's syndrome was estimated ranging from 4.6 -15.8% in the general population but increases up to 35.6% in those seeking care for low back pain [1-5]. It's also believed that LSTV increases the severity of patient's clinical presentation and pain [6]. Unilateral LSTV is more common than bilateral LSTV (9% vs. 3%) [4]. Men are more likely to be affected than women (28.1% vs. 11.1%) [7]. Bertolotti syndrome is usually diagnosed based on imaging studies, such as lumbosacral plain x-rays, Computed Tomographic (CT) scans, and Magnetic Resonance Imaging (MRI). Its presence on the imaging study does not predict the symptoms of low back pain. However, the presence of an LSTV often leads to increased incidence of low back pain due to reduced and asymmetrical motions between the LSTV and the sacrum. The asymmetrical motion can result in early arthritic changes or nerve root compression at the pseudoarticulation. The restricted motion between the LSTV and the sacrum can lead to compensatory hypermobility of the adjacent segments, causing facet pain or irritation of the nerve roots at that level, or sacroiliac dysfunction [8,9]. Due to its biomechanical and pathophysiological changes, the pain generators can be distinct in the patients who presented with low back pain associated with Bertolotti's syndrome, which imposes a challenge for successful management of these patients.

The conventional conservative management that consists of physical therapy, activity modification, medication such as NSAIDs, muscle relaxants, anticonvulsants, and antidepressants may not be sufficient to provide satisfactory pain relief. There is a dearth of literature regarding interventional approaches to the management of patients with low back pain associated with Bertolotti's syndrome [8,10]. In this report, we describe five patients with Bertolotti's syndrome who

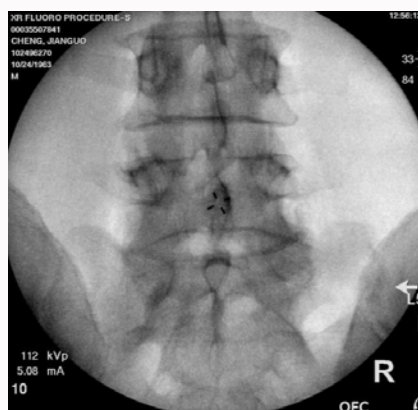


Figure 1: Anteroposterior radiograph of case 1 demonstrates bilateral pseudoarthrosis and/or fusion between the enlarged L5 transverse processes and the ilium and sacrum.

presented to a tertiary pain center with low back pain and/or radicular leg pain after having failed conventional conservative management. The pain generating mechanisms varied among these five patients, which led to diverse clinic presentations. Different interventional procedures were applied to achieve therapeutic effects.

Case Presentation

Case 1

A 52 year-old man presents with chronic low back pain for over 3 years. The pain was described as deep, dull and radiating to the gluteal areas. The pain was exacerbated by walking and mitigated by heat, physical therapy, massage and a TENS unit. There were no significant neurological findings on physical exam. Radiographs demonstrate bilateral pseudoarthrosis and/or fusion between the L5 transverse process and the ilium (Figure 1). A bilateral L3-L5 lumbar facet medial branch radiofrequency neurotomy did not provide adequate pain relief or functional improvement. But a L4-L5 interlaminar epidural steroid injection using a mixture of lidocaine 1% and corticosteroids provided 50% pain reduction for about 2.5 months. The pain likely originated from nerve root irritation by the enlarged transverse processes or pseudoarthrosis. This patient currently gets L4-L5 interlaminar epidural steroid injections every 3 months with adequate pain control and functional improvement.

Case 2

A 57 year-old man presents with chronic right leg pain radiating to the right dorsal foot for four years. The pain was described as a constant burning sensation associated with numbness and tingling. The pain was exacerbated by standing and getting up from a sitting position and alleviated by lying down. The straight leg raise test was positive on the right side and the tactile sensation was decreased on the L5 distribution on physical exam. The lumbar spine MRI shows evidence of a protruding disc at L4-L5, compressing and effacing the L5 nerve root on the right side. Radiographs demonstrate fusion between the left L5 transverse process with the ilium. Right L4 and L5 diagnostic and therapeutic transforaminal epidural steroid injection using a mixture of lidocaine 1% and corticosteroids provided 60% of immediate pain reduction after the procedure (Figure 2). Further follow-up of outcomes is pending. His right lower leg and foot pain could result from the lumbar radiculopathy caused by L4-L5 disc herniation, which is common in patients with Bertolotti's syndrome in compensation to the limited range of motion around the L5-S1

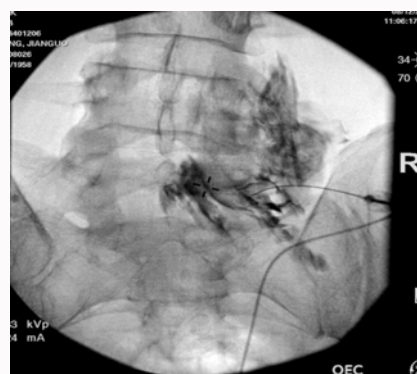


Figure 2: Anteroposterior radiograph of case 2 demonstrates fusion between the enlarged left L5 transverse process with the ilium and sacrum. L5 transforaminal epidural steroid injection was performed after confirmation of contrast spreads in the epidural space and along the right L4 and L5 nerve roots.

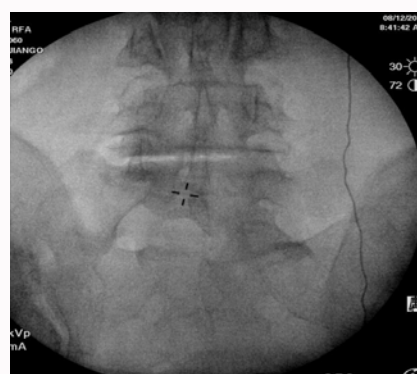


Figure 3: Anteroposterior radiograph of case 3 shows fusion of the enlarged left L5 transverse process with the sacrum and ilium.

intervertebral disc.

Case 3

A 65 year-old man presents with predominantly axial low back pain and pain in the left posterior thigh for over 5 years. The pain was described as aching and worse when getting up out of a sitting position. Physical exam showed tenderness on deep palpation over the bilateral facet joints, left worse than right, with the negative straight leg raising test. Radiographs showed fusion of the left transverse process of L5 with the sacrum or ilium (Figure 3). Lumbar spine MRI showed multilevel degenerative changes, transitional S1 with moderate left lateral recess narrowing at L5-S1 and likely chronic impingement of the left S1 nerve root. Left lumbar facet medial branch radiofrequency neurotomy at 80 degrees for 90 seconds after two previous positive diagnostic blocks provided greater than 60% pain reduction. In this case, the lumbar facet arthropathy in the segments above the sacrum likely contributed to his back pain. This is probably from the hypermobility of these segments secondary to the restricted motion between the L5 and the sacrum. Unfortunately, this patient was injured in a motor vehicle accident a few weeks after the procedure and we have not been able to further follow up his outcomes of the procedure.

Case 4

A 47 year old man presents with left low back pain radiating to the posterior aspect of the left lower extremity down to the level of the knee for 6 years. The pain was described as sharp and stabbing without

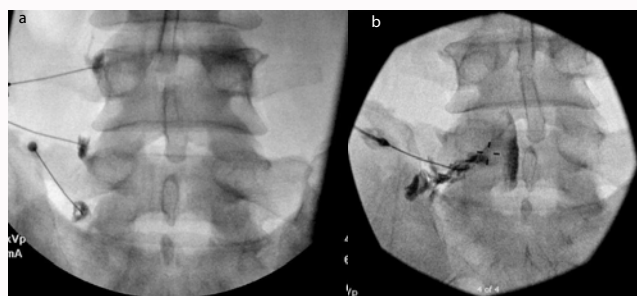


Figure 4: (a) Lumbar spine radiograph of case 4 (from a previous left medial branch block procedure) shows asymmetric enlargement of L5 transverse processes fused or articulate with the sacrum and/or ilium. The pseudoarticulation between the left transverse process and the ilium appears more mobile than the one on the right side. (b) L5 transforaminal epidural steroid injection was performed after confirmation of contrast spreads in the epidural space and along the right L5 nerve root.

numbness or tingling. Physical exam was positive for the straight leg raise on the left side. He completed a course of physical therapy and underwent bilateral lumbar medial branch blocks without significant benefit. Lumbar spine radiographies showed asymmetric enlargement of L5 transverse processes fused or articulate with the sacrum. The pseudoarticulation between the left transverse process and the ilium appeared more mobile than the one on the right side (Figure 4A). He had 75-90% of pain reduction for duration of 2-7 months to each left L5 transforaminal epidural steroid injection using a mixture of lidocaine and corticosteroid (Figure 4B).

Case 5

A 62 year old man presents with right low back pain radiating to the right gluteal area for 5 years. The pain was described as aching and worse with walking. The Patrick test was positive on the right side. Lumbar spine radiographs demonstrated asymmetrical pseudoarticulation and/or fusion between the L5 transverse processes and the iliums (Figure 5A). This patient had excellent responses to right sacroiliac joint injections with a mixture of corticosteroid and local anesthetics (Figure 5B). Subsequently, denervation of the right sacroiliac joint sensation via L5 dorsal ramus, S1 and S2 lateral branch radiofrequency neurotomy provided 70-80% of pain reduction for four months and he is still benefiting from the procedure (Figure 5C). The restricted motion between the LSTV and the sacrum may have led to relative hypermobility and dysfunction of the adjacent segments, including the sacroiliac joint in his case.

Discussion

We describe five patients with Bertolotti's syndrome who presented to a tertiary pain center with low back pain and/or radicular pain after having failed conservative treatments. Their clinical presentations and primary pain generators were different as discussed above in each individual case presentation. The interventional procedures that provided greater than 50% pain reduction in our study include L4-L5 interlaminar epidural steroid injection, L4 and L5 transforaminal epidural steroid injection, lumbar facet medial branch blocks and radiofrequency neurotomy, sacroiliac joint injections and subsequent L5 dorsal ramus, S1 and S2 lateral branch radiofrequency neurotomy.

Management of chronic low back pain associated with Bertolotti's syndrome should be initiated with a comprehensive conservative approach consisting of activity modification, physical therapy and home exercise, psychosocial support, and medications such as

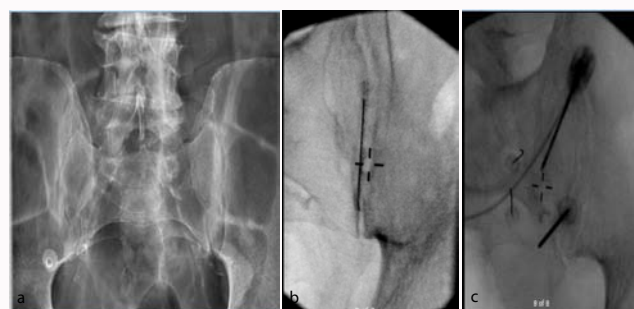

Figure 5: a) Lumbar spine radiograph of case 5 demonstrates asymmetrical pseudoarticulation and/or fusion between the L5 transverse processes and the iliums. b) Right sacroiliac joint injection. c) L5 dorsal ramus, S1 and S2 lateral branch radiofrequency neurotomy.

NSAIDs, muscle relaxants, anticonvulsants, and antidepressants. Interventional approaches can be beneficial in cases refractory to conventional conservative management. For those who presented with lumbosacral radiculopathy or radiculitis symptoms due to the direct compression or irritation of the nerve root by an enlarged transverse process or pseudoarticulation, a transforaminal or interlaminar epidural steroid injection maybe considered. A diagnostic lumbar facet medial branch block can be performed for those with clinical evidence of lumbar facet pain due to the reduced motion between the LSTV and the sacrum. Radiofrequency neurotomy of the target medial branches may provide longer-term pain relief if the patient has greater than 50% pain reduction from the diagnostic medial branch block. For those suspected of sacroiliac dysfunction due to increased load to the sacroiliac joint with restricted motion between the LSTV and the sacrum, a diagnostic sacroiliac joint injection maybe attempted. If the patient has greater than 50% pain reduction, radiofrequency neurotomy of the L5 dorsal ramus, S1 and S2 lateral branches may provide longer-term pain relief.

A few other interventional procedures to manage chronic low back pain associated with Bertolotti's syndrome have also been reported. Injections of steroids and/or local anesthetics into the LSTV pseudoarticulation site can be both diagnostic and therapeutic in providing temporary pain relief if the primary pain generator is the pseudarthrosis [11]. Posterolateral fusion, partial or full resection of the LSTV pseudoarticulation have been reported to provide pain reduction and can be considered for long-term relief if the diagnostic block of pseudoarticulation was positive [12-14].

Conclusion

In light of the diversity of clinical presentations, management of patients with low back pain associated with Bertolotti's syndrome has to be individualized. Multimodal care is often required based on clinical data, imaging and diagnostic blocks. Interventional procedures may provide better pain relief and facilitate participation in functional physical activities. Understanding the biomechanical and pathophysiological mechanisms underlying the chronic low back pain is the key to choosing the appropriate procedures.

References

1. Apazidis A, Ricart PA, Diefenbach CM, Spivak JM. The prevalence of transitional vertebrae in the lumbar spine. *Spine J.* 2011;11(9):858-62.
2. Quinlan JF1, Duke D, Eustace S. Bertolotti's syndrome. A cause of back pain in young people. *J Bone Joint Surg Br.* 2006;88(9):1183-6.

3. Tang M, Yang XF, Yang SW, Han P, Ma YM, Yu H, et al. Lumbosacral transitional vertebra in a population-based study of 5860 individuals: prevalence and relationship to low back pain. *Eur J Radiol.* 2014;83(9):1679–82.
4. Mahato NK. Morphometric analysis and identification of characteristic features in sacra bearing accessory articulations with L5 vertebrae. *Spine J.* 2010;10(7):616–21.
5. Delport EG, Cucuzzella TR, Kim N, Marley J, Pruitt C, Delport AG. Lumbosacral transitional vertebrae: incidence in a consecutive patient series. *Pain physician.* 2006;9(1):53–6.
6. Taskaynatan MA, Izci Y, Ozgul A, Hazneci B, Dursun H, Kalyon TA. Clinical significance of congenital lumbosacral malformations in young male population with prolonged low back pain. *Spine.* 2005;30(8):E210-E13.
7. Nardo L, Alizai H, Virayavanich W, Liu F, Hernandez A, Lynch JA, et al. Lumbosacral transitional vertebrae: association with low back pain. *Radiology.* 2012;265(2):497–503.
8. Wu J, Cheng J. Unusual pain syndromes. Kaye A, Shah R, editors. In: Bertolotti's syndrome. *Case Studies in Pain Management.* 1st ed. Cambridge: Cambridge University Press; 2014. 155-158.
9. Otani K, Konno S, Kikuchi S. Lumbosacral transitional vertebrae and nerve-root symptoms. *J Bone Joint Surg Br.* 2001;83(8):1137–40.
10. Jancuska JM, Spivak JM, Bendo JA. A Review of Symptomatic Lumbosacral Transitional Vertebrae: Bertolotti's Syndrome. *Int J Spine Surg.* 2015;9:42.
11. Almeida DB, Mattei TA, Soria MG, Prandini MN, Leal AG, Milano JB, et al. Transitional lumbosacral vertebrae and low back pain: diagnostic pitfalls and management of Bertolotti's syndrome. *Arquivos de neuro-psiquiatria.* 2009;67(2A):268–72.
12. Santavirta S, Tallroth K, Ylinen P, Suoranta H. Surgical treatment of Bertolotti's syndrome. Follow-up of 16 patients. *Arch Orthop Trauma Surg.* 1993;112(2):82–7.
13. Brault JS, Smith J, Currier BL. Partial lumbosacral transitional vertebra resection for contralateral facetogenic pain. *Spine.* 2001;26(2):226–9.
14. Li Y, Lubelski D, Abdullah KG, Mroz TE, Steinmetz MP. Minimally invasive tubular resection of the anomalous transverse process in patients with Bertolotti's syndrome: presented at the 2013 Joint Spine Section Meeting: clinical article. *J Neurosurg Spine.* 2014;20(3):283–90.