



Endovascular Management of a Pseudoaneurysm Following Ankle Arthroscopy: A Case Report

Seyed M. Qaderi^{1*}, Eva AK van Delft¹, Arjan van der Elst¹ and Lars W. Kaufmann²

¹Department of Surgery, Spaarne Gasthuis, Hoofddorp, Netherlands

²Department of Radiology Spaarne Gasthuis, Hoofddorp, Netherlands

Abstract

Introduction: Pseudoaneurysm formation following ankle arthroscopy is an uncommon complication that can have serious consequences. Early recognition and diagnosis of this condition are challenging. The treatment method we describe can help prevent long-term therapy and comorbidity, and has not been published as such in the literature.

Case Presentation: In this article, we describe a case of successful endovascular coil embolization of the dorsal pedal artery to exclude a pseudoaneurysm due to ankle arthroscopy in a 57-year-old Caucasian male.

Conclusion: What this report adds to the existing literature is that endovascular coil embolization of a damaged dorsal pedal artery can be a treatment option for pseudoaneurysms in selective patients.

Keywords: Dorsal pedal artery; Coil embolization; Pseudoaneurysm; Doppler ultrasonography; Case report

Abbreviations

ED: Emergency Department; CRP: C -Reactive Protein; WBC: White Blood Cell Count; MA: Massachusetts; MRI: Magnetic Resonance Imaging; CTA: Computed Tomogram Angiography; MRA: Magnetic Resonance Angiography

OPEN ACCESS

*Correspondence:

Seyed M. Qaderi, Department of Surgery, Spaarne Gasthuis, Spaarnepoort 1, 2124 TM Hoofddorp, Netherlands, Tel: +31(0)238908900; E-mail: s.m.qaderi@gmail.com

Received Date: 07 Nov 2016

Accepted Date: 27 Mar 2017

Published Date: 29 Mar 2017

Citation:

Qaderi SM, van Delft EAK, van der Elst A, Kaufmann LW. Endovascular Management of a Pseudoaneurysm Following Ankle Arthroscopy: A Case Report. *Ann Clin Case Rep.* 2017; 2: 1317.

ISSN: 2474-1655

Copyright © 2017 Qaderi SM. This is an open access article distributed under the Creative Commons Attribution License, which permits unrestricted use, distribution, and reproduction in any medium, provided the original work is properly cited.

Introduction

In less than 1% of ankle arthroscopies, vascular complications occur, mostly related to instrument placement [1]. Pseudoaneurysm formation of the dorsal pedal artery following ankle arthroscopies has an incidence of 0,008% [2]. Recognition of this condition is challenging and this could impose treatment delay. The risk of vascular complications during ankle arthroscopies is mainly caused by the close anatomic relationship of the pedal arteries with the ankle joint capsule and because of anatomic variations [1]. We describe a case of endovascular coil embolization of the dorsal pedal artery to exclude a pseudoaneurysm due to ankle arthroscopy. The treatment method we describe can help prevent long-term therapy and comorbidity, and has not been published as such in literature before.

Case Presentation

A 57-year-old Caucasian male was admitted to our Emergency Department (ED) with complaints of a painful and swollen right ankle. Three days before the orthopedic surgeon performed an ankle arthroscopy because of ankle impingement syndrome. Since compression bandage was removed two days after the procedure the man experienced progressive swelling and pain of the ankle. The patient was treated with compression bandage. Four days later the patient presented to the ED because of persistent complaints of pain. Physical examination revealed erythema surrounding the operation wounds (Figure 1). Blood tests now revealed an elevated CRP of 40 mg/L and a WBC count of $10.4 \times 10^9/L$. The microbiologist was consulted and because an infected hematoma or septic arthritis with a (gram positive) skin agent was suspected, clindamycin (600 mg, 3 times a day) for 10 days was prescribed. At that moment, there was no indication for incision and drainage. Three weeks after the start of antibiotic treatment the infection was controlled effectively with no infectious symptoms, but the patient complained about a local swelling on his foot. Physical examination revealed a pulsatile swelling on the dorsal side of the foot. Sonography confirmed a pseudoaneurysm of the dorsal pedal artery which measured 3 centimeters in diameter (Figure 2). The patient was admitted to our

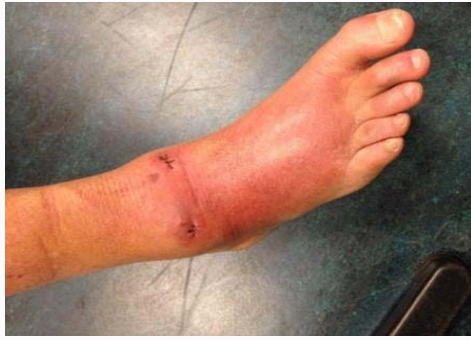

Figure 1: Presentation at the Emergency Department, 7 days after ankle arthroscopy. Redness and swelling of the dorsal foot. Stitches present.

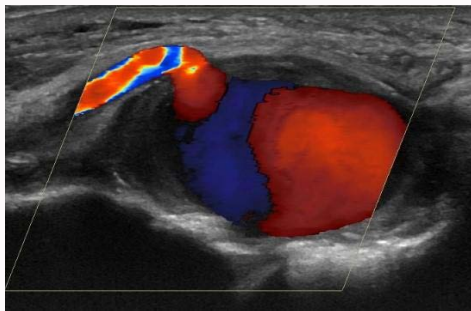


Figure 2: Pseudoaneurysm of the dorsal pedal artery measuring 3.32 cm. The pseudoaneurysm is supplied by the dorsal pedal artery. Outflow not visible.

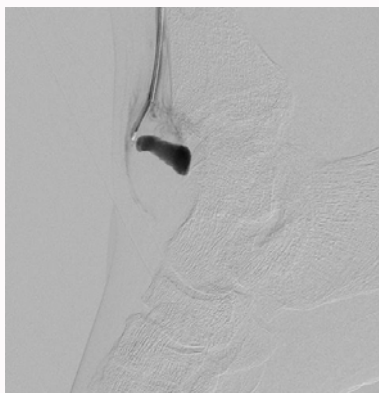


Figure 3: Arteriogram depicting the pseudoaneurysm of the dorsal pedal artery.

department. Five weeks after the primary procedure we performed an arteriography (Figure 3) which showed the pseudoaneurysm, originating from the dorsal pedal artery without efferent flow out of the aneurysm (Figure 4). No evident aneurysm neck or orifice was recognizable. Arteriography revealed retrograde filling of the distal dorsal pedal artery from the pedal arch (posterior tibial artery and plantar arteries). Selective catheterization of the distal anterior tibial artery was conducted. Because the pedal arch and the distal pedal artery were vascularized properly out of the posterior tibial artery, during the same procedure endovascular micro-coil embolization of the dorsal pedal artery was done to exclude the pseudoaneurysm (Figure 5A, fibered platinum 3.3 mm coil, VortX; Boston Scientific, Natick, MA). Post embolic arteriography showed no flow in the former aneurysm (Figure 5B). Although peripheral coil embolization can be complicated with dislocation of the coils, ischemia and

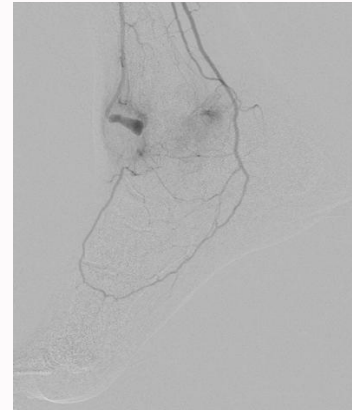


Figure 4: Arteriogram showing the pseudoaneurysm of the dorsal pedal artery. No distal flow is seen from that level in the dorsal pedal artery.

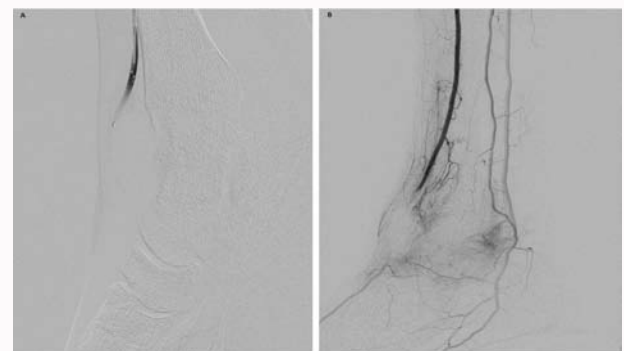


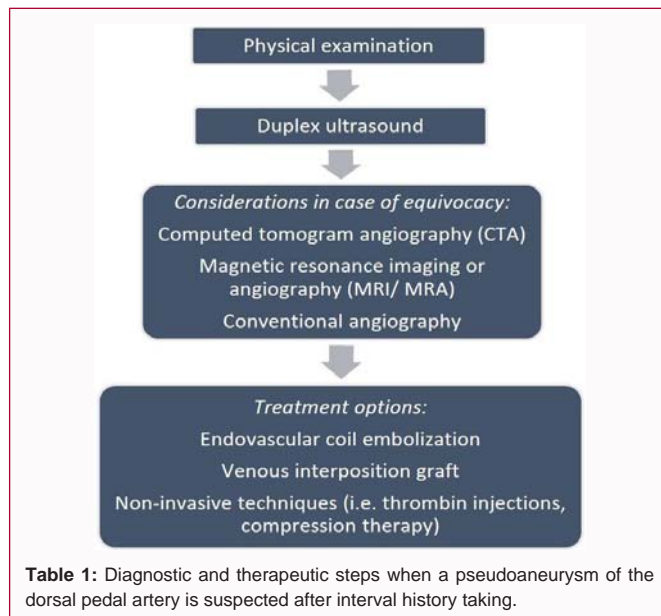
Figure 5: (A) Guiding up the catheter in the dorsal pedal artery with the micro-coil at the tip just near the entry of the aneurysm. (B) Control arteriogram after embolization.

general procedure complications such as contrast allergic reactions no complications were observed in our patient [2]. The patient had a prosperous recovery without swelling or pain complaints whatsoever. Doppler sonography confirmed the absence of the pseudoaneurysm and the patient was discharged after three months follow-up.

Discussion

Pseudoaneurysms develop in damaged vascular walls. Most pseudoaneurysms are iatrogenic of origin and usually result from vascular interventions [3]. Pseudoaneurysm formation after ankle arthroscopy is a condition hard to recognize and the timeframe to diagnosis can range to several months. Delay in treatment can lead to risk of rupture, hemarthros and compression neuropathy [4]. The risk of vascular complications during ankle arthroscopy is mainly caused by the close anatomical relationship of the pedal and crural arteries with the ankle joint capsule, the anatomic variations in vessel position and the choice of trocar placement [1]. When physical examination is inconclusive in detecting a pseudoaneurysm of the dorsal pedal artery, ultrasound presents a noninvasive, relatively cheap and accurate diagnostic tool for diagnosing pseudoaneurysms [5]. Other modalities such as magnetic resonance imaging (MRI) or computed tomogram angiography (CTA) and magnetic resonance angiography (MRA) can also play a role in detection of aneurysms [6,7]. Performing conventional angiography allows an intervention in the same procedure. We recommend physical examination combined with duplex ultrasound (Table 1).

The choice of treatment of pseudoaneurysms depends on size,



location, and associated symptoms [3]. In the recent past several methods of treatment for pseudoaneurysms have been described in the literature, for example open surgical treatment with an autologous interposition vein graft, compression therapy, stent-graft implantation and thrombin injections [3,8]. Ultrasound-guided thrombin injections have shown to be useful, but its use in smaller, distal arteries are less supported. Also, it can be complicated with iatrogenic embolization of the plantar arteries [9,10]. Though compression therapy may be successful, it is painful, time-consuming, it can be complicated with aneurysm rupture and it is associated with frequent failures in treatment [10]. Endovascular treatment with covered stents allows vessel preservation, but it is not favored because of low patency rates in small size vessels and in relatively young patients [8,11,12].

Minimally invasive treatment such as endovascular coil embolization has proven to be an alternative for surgical repair. It can be performed along diagnostic arteriography and has been described with good results. Advantages are lower complication rates, rapid recovery and no need for lifetime anticoagulative treatment as in venous interposition grafting [3,8,9]. Despite this, the use of endovascular embolization has not been described for treating a similar complication as we encountered. Embolization of the dorsal pedal artery is potentially harmful when an artery of the foot is affected by peripheral arterial disease. However, when other runoff vessels are patent, there is no evidence that embolization of a single vessel will do harm [5]. Our patient did not have relevant vascular risk factors. Regarding our case, we suggest that arterial injury caused by trocars along with attempted hemostasis and weight bearing lead to aneurysm formation. The damaged dorsal pedal artery maintained the pseudoaneurysm. Contemplating a venous interposition graft on a damaged, poor run-off vessel would not be credible. Taking in mind the limitations of alternative treatments along with our experience with endovascular embolotherapy, we favored embolization to abolish the pseudoaneurysm and prevent further harm.

Conclusion

Dorsal pedal artery pseudoaneurysm formation is a rare complication of ankle arthroscopy that can have significant

complications. In the case of abnormal swelling following ankle arthroscopy, this diagnosis has to be taken into account. Several treatment options have been described in literature before. We treated the patient with endovascular coil embolization, a minimally invasive technique which showed good results without any complications. What this report adds to the existing literature is that endovascular coil embolization of a damaged dorsal pedal artery can be a treatment option for pseudoaneurysms in patients with well vascularized lower limbs and no vascular risk factors.

Informed Consent

Written informed consent was obtained from the patient for publication of this case report and any accompanying images. A copy of the written consent is available for review by the Editor-in-Chief of this journal.

Availability of Data and Supporting Materials

All images and relevant patient chart notes are, on request, available for fellow colleagues and scientists.

Declarations

Written consent was obtained for writing and publishing this case report from the patient. This manuscript reports data obtained from retrospective chart review, and did not have active (prospective) human participants. Therefore, writing and publishing this case report did not require ethics committee approval.

Authors' Contributions

Conception and design: SQ, ED; Data collection: SQ, ED; Writing the article: SQ, ED, AE; Critical revision of the article: AE, LK, ED, SQ; Final approval of the article: SQ, ED, AE, LK; Interventions: LK; Overall responsibility: AE; All authors read and approved the final manuscript: LK: Lars W. Kaufmann; AE: Arjan van der Elst; ED: Eva A.K van Delft; SQ: Seyed M. Qaderi.

References

1. Son KH, Cho JH, Lee JW, Kwack KS, Han SH. Is the anterior tibial artery safe during ankle arthroscopy?: anatomic analysis of the anterior tibial artery at the ankle joint by magnetic resonance imaging. *Am J Sports Med.* 2011;39(11):2452-6.
2. Jacobs E, Groot D, Das M, Hermus JP. Pseudoaneurysm of the anterior tibial artery after ankle arthroscopy. *J Foot Ankle Surg.* 2011;50(3):361-3.
3. Gratl A, Klocker J, Glodny B, Wick M, Fraedrich G. Treatment options of crural pseudoaneurysms. *Vasa.* 2014;43(3):209-15.
4. Brimmo OA, Parekh SG. Pseudoaneurysm as a complication of ankle arthroscopy. *Indian J Orthop.* 2010;44(1):108-11.
5. Maydew MS. Dorsalis pedis aneurysm: ultrasound diagnosis. *Emergency Radiology.* 2007;13:277-80.
6. Nishi H, Miyamoto S, Minamimura H, Ishikawa T, Katoh Y, Shimizu Y. Pseudoaneurysm of the dorsalis pedis artery causing neurological deficit. *Ann Vasc Surg.* 2004;18(4):487-9.
7. Kato T, Takagi H, Sekino S, Manabe H, Matsuno Y, Furuhashi K, et al. Dorsalis pedis artery true aneurysm due to atherosclerosis: case report and literature review. *J Vasc Surg.* 2004;40(5):1044-8.
8. Lopera JE, Suri R, Cura M, Fadi El-Merhi. Crural Artery Traumatic Injuries: Treatment with Embolization. *Cardiovascular Interventional Radiology.* 2008;31(3):550-7.

9. Yu JL, Ho E, Wines AP. Pseudoaneurysms around the foot and ankle: case report and literature review. *Foot Ankle Surg.* 2013;19(3):194-8.
10. Schaarschmidt BMS, Heuser LJ. Diagnostics and treatment of pseudoaneurysm of the distal anterior tibial artery after upper ankle joint arthroscopy: A case report and a review of literature. *Fortschritte Rontgenstrahle.* 2013; 185(2):169-71.
11. Joglar F, Kabutey NK, Maree A, Farber A. The role of stent grafts in the management of traumatic tibial artery pseudoaneurysm: case report and review of the literature. *Vasc Endovascular Surg.* (2010);44(5):407-9.
12. De Roo RA, Steenvoorde P, Schuttevaer HM, Den Outer AJ, Oskam J, Joosten PP. Exclusion of a crural pseudoaneurysm with a PTFE-covered stent-graft. *J Endovasc Ther.* 2004;11(3):344-7.