



Demyelinating Disease after Anti-tumor Necrosis Factor Alfa Treatment

Refah Sayın^{1*}, Muhammed Ertuğrul Güvenç¹ and Mehmet Zülküf Önal²

¹Department of Neurology, Ufuk University, Turkey

²Department of Neurology, Medicana International Ankara Hospital Neurology, Turkey

Abstract

Certolizumab is a Tumor Necrosis Factor alpha (TNF- α) inhibitor. It is a biological medicine used for the treatment of Crohn's disease, Rheumatoid Arthritis (RA), psoriatic arthritis and Ankylosing Spondylitis (AS). Although certolizumab has many reported side effects, neurological side effects are rare. Suicide attempt, mental disorder, delirium, hearing-vision and facial nerve inflammation, epileptic seizure, coordination and/or balance disorder, paralysis, acute inflammatory demyelinating polyneuropathy, Chronic Inflammatory Demyelinating Polyneuropathy (CIDP), peripheral neuropathy and Optic Neuritis (ON) are possible visible effects. Peripheral neuropathy is the most common; Central Nervous System (CNS) and/or medulla spinalis demyelination follows this. While other TNF- α inhibitors (Adalimumab, Infliximab, Etanercept, Golimumab) are used in the treatment of RA, they have been reported to cause demyelinating disease or Guillain-Barre Syndrome (GBS). With certolizumab treatment, the risk of CNS and/or medulla spinalis demyelination or peripheral neuropathy is known and very rare. We aimed to present a case of demyelinating disease secondary to the rare use of certolizumab.

Case Presentation

Analgesics are administered to 33 years old right-handed female patient who visits emergency with complaints of tingling in the right half of her face and pain in her right eye. She is advised to go to the Neurology department the next day if her complaints continue. The patient applied to our clinic. According to the neurological examination performed, hypoesthesia-hypoalgesia-hypothermosis due to touch-pain-heat sensations in the right half of her face and vitality in deep tendon reflexes were detected. As it is mentioned in her resume, she had been using Familial Mediterranean Fever colchicum-dispert for 17 years and certolizumab (subcutaneous once every 2 weeks since 2 years) in the treatment of AS for 5 years. Before the patient visited our clinic, a contrast-enhancing hyperintense lesion was detected in the right pons lateral side of the contrast-enhanced cranial Magnetic Resonance Imaging (MRI) taken at another clinic. Therefore, the necessary triggers were requested considering that the patient might have demyelinating disease and/or vasculitis as a pre-diagnosis. Lumbar puncture was performed before medical treatment. In the cerebrospinal fluid examination; NMO IgG negative, oligoclonal band type 2 and IgG index were found as 0.63. Vasculitis, hematological and infection markers were normal. Evoked potentials and cervical MRI, MR angiography were normal. Certolizumab treatment was immediately stopped. The patient was given 1 gr/day intravenous methyl prednisolone treatment for 7 days. Almost complete improvement was detected in the patient's complaints. It was observed that the lesion completely disappeared in the cranial MRI taken as a control during the follow-up after 9 months.

Discussion

Certolizumab is TNF- α inhibitor. Other TNF- α inhibitors are used in the treatment of Crohn's disease, RA, psoriatic arthritis and AS. Although certolizumab has many reported side effects, neurological side effects are rare. Demyelinating disease and/or GBS has been reported to develop due to TNF- α inhibitors used in the treatment of RA. Certolizumab was given to two patients with Crohn's disease; peripheral neuropathy was detected in one of them; CNS demyelinating disease was reported in the other patient [1-5]. In an article published as a review, it was not precisely explained how TNF- α inhibitors cause demyelination. Six theories were proposed in the study. These were;

- TNF- α inhibitors cannot cross the blood-brain barrier, they cause demyelination by activating the increase of peripheral T cells,

OPEN ACCESS

*Correspondence:

Refah Sayın, Department of Neurology,
Ufuk University, 06520, Ankara, Turkey,
Tel: +90 505 217 87 69; Fax: +90 312
2044440;

E-mail: refahsayin@yahoo.com.tr

Received Date: 28 Oct 2021

Accepted Date: 09 Dec 2021

Published Date: 16 Dec 2021

Citation:

Sayın R, Güvenç ME, Önal MZ.

Demyelinating Disease after Anti-tumor
Necrosis Factor Alfa Treatment. *Ann
Clin Case Rep.* 2021; 6: 2063.

ISSN: 2474-1655

Copyright © 2021 Refah Sayın. This is an open access article distributed under the Creative Commons Attribution License, which permits unrestricted use, distribution, and reproduction in any medium, provided the original work is properly cited.

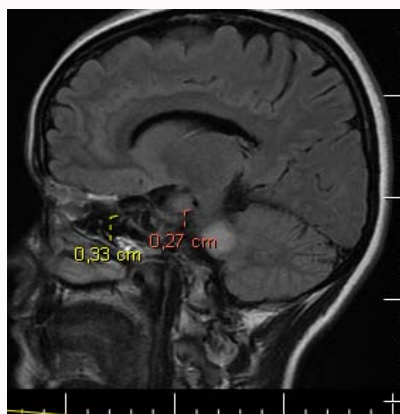


Figure 1: FLAIR-contrast-enhanced cranial MRI sequences dated 27/11/2019.

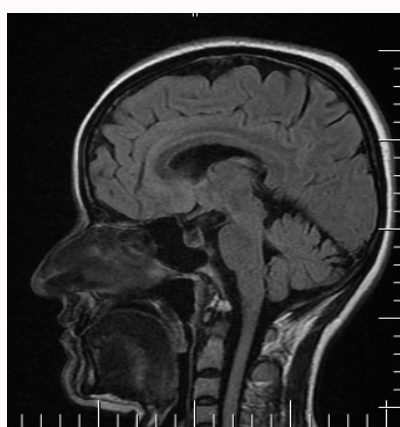


Figure 2: FLAIR-contrast-enhanced cranial MRI sequences dated 24/08/2020.

- TNF- α inhibitors impair myelin repair by decreasing R2 receptors,
- By reducing interleukin 10 and increasing IL-12 and interferon-gamma, it can reveal demyelinating disease findings in patients,
- Since TNF- α inhibitors cannot pass to the CNS, they cause a high concentration of TNF- α in the CNS,
- Dysregulation of TNF- α in the serum causes neutralization of TNF- α in relapsing-remitting MS patients,
- It has been reported that these medicines cause autoimmune demyelination by reactivating the underlying masked infections [6].

The use of certolizumab was not encountered for the patients in this study. Exactly 26 of 122 patients were treated with the thought that MS might be present, only 7 of these patients were started to be followed up with the diagnosis of MS after the treatment was discontinued [6]. In another study conducted in Denmark 6 cases were reported. In these cases they used TNF- α inhibitors other than certolizumab, 4 of them were followed up considering that they may have demyelinating diseases. The first patient was diagnosed

with MS; interferon therapy was initiated. The second patient was recommended to apply to the MS clinic. With the initiation of rituximab the complaints of the third patient decreased and also remission was observed. The fourth patient was followed up with a diagnosis of demyelinating disease [7]. In another study conducted in France between 2005-2008 patients who used 38 TNF- α inhibitors and developed demyelinating disease afterwards were evaluated. These patients used agents other than certolizumab. Demyelinating disease was reported for 33 patients at a mean of 10.2 months. Demyelinating disease was observed in 22 patients due to the CNS and 11 patients due to the PNS. 22 patients; in 16 of them brain involvement (5 patients MS, 5 patients with ON) were observed. In 8 of them findings of medulla spinalis involvement were found [8]. In a study conducted in Spain, neurological side effects were reviewed in patients who received 175 TNF- α inhibitors until July 2009. MS and MS-like disease were seen in 43 patients, optic neuritis in 115 patients. Eight patients had both MS and ON and five patients had other demyelinating lesions. In addition, 20 of peripheral neuropathy patients were reported as GBS, 11 as multifocal neuropathy, 6 as CIDP, 5 as axonal polyneuropathy and 2 were reported as Lewis-Summer Syndrome. In our case, demyelinating disease findings were revealed after the use of certolizumab with the diagnosis of AS. After the medicine was discontinued, demyelinating disease treatment was given and followed. Although TNF- α inhibitors are used in some diseases, they rarely have neurological side effects. We found it valuable to present a patient who developed CNS demyelinating disease due to the use of certolizumab and completely recovered after the medicine was discontinued.

References

1. Karampetsou MP, Liossis S-NC, Sfikakis PP. TNF- α antagonists beyond approved indications: Stories of success and prospects for the future. *QJM*. 2010;103:917-28.
2. Bosch X, Ramos-Casals M. Monoclonal antibody therapy-associated neurological disorders. *Nat Rev Neurol*. 2011;7:165-72.
3. Mohan N, Edwards E, Cupps T, Oliverio P, Sandberg G, Crayton H, et al. Demyelination occurring during anti-tumor necrosis factor alpha therapy for inflammatory arthritides. *Arthritis Rheum*. 2001;44:2862-69.
4. Deepak P, Stobaugh DJ, Sherid M, Sifuentes H, Ehrenpreis ED. Neurological events with tumour necrosis factor alpha inhibitors reported to the Food and Drug Administration Adverse Event Reporting System. *Aliment Pharmacol Ther*. 2013;38(4):388-96.
5. Kemanetzoglou E, Andreadou E. CNS Demyelination with TNF- α Blockers. *Curr Neurol Neurosci Rep*. 2017;17(4):36.
6. Theibich A, Dreyer L, Magyar M, Loch H. Demyelinating neurological disease after treatment with tumor necrosis factor alpha-inhibiting agents in a rheumatological outpatient clinic: Description of six cases. *Clin Rheumatol*. 2014;33:719-23.
7. Seror R, Richez C, Sordet C, Rist S, Gossec L, Direz G, et al. Inflammation Section of the SFR. Pattern of demyelination occurring during anti-TNF- α therapy: A French national survey Comparative Study. *Rheumatology*. 2013;52:868-74.
8. Ramos-Casals M, Roberto Perez A, Diaz-Lagares C. Autoimmune diseases induced by biological agents: A double-edged sword? *Autoimmun Rev*. 2010;9:188-93.