



Broncho-Biliary and Bilio Cutaneous Fistulas: A Severe Complication of Liver's Hydatid Cysts

Rabiou S^{1*}, Ouadnoui Y^{1,2} and Smahi M^{1,2}

¹Department of Thoracic Surgery, University Hospital Hassan II-Fez, Morocco

²Faculty of Medicine and Pharmacy, Sidi Mohamed Ben abdellah University-Fez, Morocco

Abstract

Fistulas are one of the main complications of hydatid cysts. The case of female patient of 37 years old, came from a rural area, operated first for hepatic hydatid cyst two years ago, then she didn't receive any antiparasitic agents later. Addressed to us for the treatment of biliptysis. The clinical and radiological examination revealed a broncho-biliary fistula associated with a bilio-cutaneous fistula of hydatid origin. In order to restore the biliary tract flow, an Endoscopic Retrograde Cholangiopancreatography (ERCP) with a sphincterotomy and the establishment of a biliary stent has been performed. The surgical treatment consists of a pulmonary and hepato-diaphragmatic disconnection with rather satisfying results.

Introduction

The hydatid cyst has a different anatomic-pathological form, because of the large evolving character and radiological appearance of cyst. These complications are different; it's depending on the seat, which we quoted in this article: The broncho-biliary fistula associated with bilio cutaneous fistula. It considered a serious complication of hepatic hydatid. Regardless of the considerable advancement made in diagnostic imaging in the last few years, the patient care remains difficult with a rather important recurrence rate [1,2]. The increasingly systematic introduction of per operative Endoscopic Retrograde Cholangiopancreatography (ERCP) with the undergoing of a sphincterotomy for patients with higher risks, has allowed a radical change in the approach adopted for the treatment of this condition. However, the prognosis remains severe in spite of the betterment of resuscitation means and facilities alongside operative techniques.

Case Presentation

MB, is a female patient of 37 years of age, came from a rural area, she was operated two years ago for a hydatid cyst opened in the biliary tract, with any antiparasitic agents later. She came back a year later with a cutaneous fistula with an outflow of bile evoking a bilio-cutaneous fistula. She had benefited a just from percutaneous fistulography that confirmed the existence of a communication of the skin with a fistulized liver injury (Figure 1). In order to restore the biliary tract flow, an Endoscopic Retrograde Cholangio-Pancreatography (ERCP) with a sphincterotomy and the establishment of a biliary stent has been performed. In the few months that followed the cutaneous fistula dried out, but some pulmonary symptoms appeared: a cough with biliptysis. At her admission into our department, the clinical examination has found a patient in a fair general condition, afebrile, with the presence of crepitation at the pulmonary auscultation. A thoraco-abdominal computed tomography (CT) scan objectified a liver injury communicating with another lung injury (Figure 2). The treatment consisted in a right posterolateral thoracotomy allowing a pulmonary and hepato-diaphragmatic disconnection, the treatment of the liver injury through the diaphragmatic breach, and also the treatment of the lung injury. After a diaphragmatic plasty, two drains (one pleural and the other inter hepato-diaphragmatic) were left in place. The post-operative evolution was satisfactory, with the disappearance of the biliptysis and a good recovery of the pulmonary dynamic.

Discussion

Broncho-biliary fistulas can manifest themselves either loudly and abruptly, or progressively and insidiously [1]. In the case of our patient, the clinical manifestation was progressive, with predisposing factors, in particular, the notion of an anterior surgery for a hydatid cyst opened in the biliary tract. In severe acute cases, major respiratory disorders can be observed, sometimes leading to a respiratory distress syndrome as a consequence of the flooding of the contralateral lung, and/

OPEN ACCESS

*Correspondence:

Rabiou Sani, Department of Thoracic Surgery, University Hospital Hassan II-Fez, Morocco, Tel: 212680772220; E-mail: rabiouani2@icloud.com

Received Date: 23 Sep 2016

Accepted Date: 25 Oct 2016

Published Date: 27 Oct 2016

Citation:

Rabiou S, Ouadnoui Y, Smahi M. Broncho-Biliary and Bilio Cutaneous Fistulas: A Severe Complication of Liver's Hydatid Cysts. *Ann Clin Case Rep.* 2016; 1: 1165.

Copyright © 2016 Rabiou S. This is an open access article distributed under the Creative Commons Attribution License, which permits unrestricted use, distribution, and reproduction in any medium, provided the original work is properly cited.

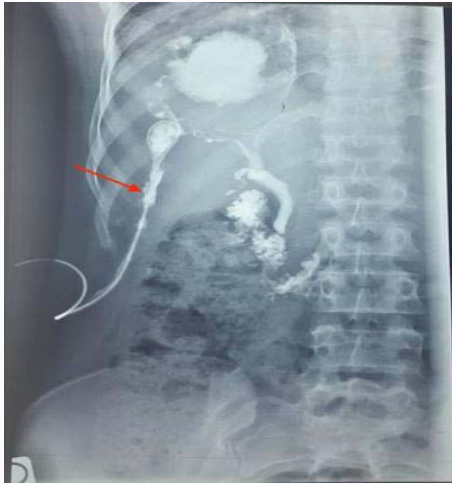

Figure 1: Percutaneous fistulography showing liver hydatid cyst fistulized to the skin (Red arrow).

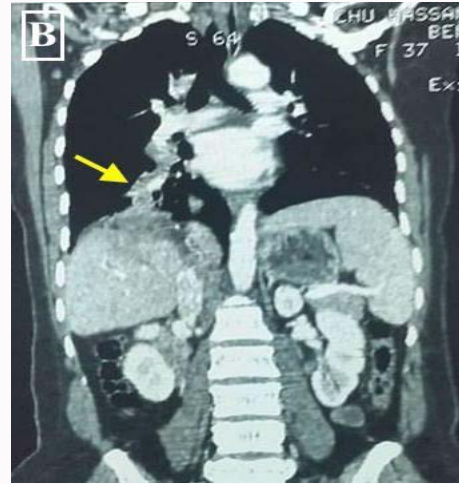


Figure 2: Thoraco-abdominal CT Scan objectified a liver hydatid cyst communicating with the lung (yellow arrow).

or because of the caustic action of bile on the tracheobronchial tree [1-3]. Exceptionally, an anaphylactic shock can be the inaugural sign [4]. Thus, when facing patients presenting biliptysis, a thoraco-abdominal CT scan must complete the assessment. It will allow thoroughly analyze the liver injury, and eventually identify a possible communication between the liver and the lung, and also to evaluate the damaged caused on the lung. The hepatobiliary ultrasound must look for an obstacle or a dilatation on the common bile duct [5]. It also allows us to find the liver hydatid cyst and determine its type [6]. The ERCP, is a major step in the preparation of surgery. It enables us to visualize the fistula and look for an obstruction on the biliary duct. It also permits its desobstruction in order to restore the biliary flow thus avoiding recurrence. In the case of our patient, the fact that we placed a biliary stent endoscopically, permitted the healing of the bilio cutaneous fistula. The surgical treatment consists of a pulmonary and hepato-diaphragmatic disconnection. Low thoracotomy is the approach adopted in this context as it allows the treatment of three levels (Thoracic, abdominal and hepatic). From this we concluded the important role of antiparasitic agents in the prevention of complications of non-operated hydatid cysts, as well as to prevent postoperative recurrence. Although the frequency appears in regression and increased from 16% to 2.5%, it is still a serious complication of hydatid cysts of the liver, due to the multiplicity of lesions that affect the same time the abdominal and thoracic level through the diaphragm. This is in most cases very old hydatid cysts localized in the liver dome. The best knowledge of hydatid disease and the availability of investigative increasingly accurate as abdominal ultrasound appear to have a role in the regression of this frequencies allowing early treatment of hydatid cysts of the liver, avoiding its evolution stage of complications.

Conclusion

Hydatid cysts of liver origin opened in the thorax are a major complication that affects the three levels: Abdominal, diaphragmatic and thoracic making the surgical approach rather difficult. The results of the surgery depend on the quality of the preparation of the patient before the procedure. The endoscopic cholangiography with the recovery of the biliary flow is a major step that helps avoid any recurrence.

References

1. Abi F, el Fares F, Khaiz D, Bouzidi A. [Unusual localizations of hydatid cysts. Apropos of 40 cases]. *J Chir (Paris)*. 1989; 126: 307-312.
2. Dziri C, Haouet K, Fingerhut A, Zaouche A. Management of cystic echinococcosis complications and dissemination: where is the evidence?. *World J Surg*. 2009; 33: 1266-1273.
3. Kilani T, El Hammami S, Horchani H, Ben Miled-Mrad K, Hantous S, Mestiri I, et al. Hydatid disease of the liver with thoracic involvement. *World J Surg*. 2001; 25: 40-45.
4. Yuste MG, Duque JL, Heras F, Sanchez E, Gonzalez Selma ML, Ramos G, et al. [Thoracic development of liver hydatid cysts, and its complications. Apropos of 21 cases]. *Ann Chir*. 1984; 38: 153-157.
5. Moumen M, el Fares F. [Bilio-bronchial fistula of hydatid origin. Apropos of 8 cases]. *J Chir (Paris)*. 1991; 128: 188-192.
6. Gharbi HA, Hassine W, Brauner MW, Dupuch K. Ultrasound examination of the hydatid liver. *Radiology*. 1981; 139: 459-463.