



Benefits of Physical Therapy Interventions for a Patient with End-Stage Pulmonary Disease who developed Right-Sided Heart Failure Requiring ECMO Support Bridging to Lung Transplantation

Samantha Mancuso*, Kirby Mayer** and Anil Gonipath

Rehabilitation Sciences Doctoral Program, University of Kentucky, USA

*Both the authors contributed equally

Abstract

Background: Extracorporeal Membrane Oxygenation Support (ECMO) is the highest level of life support. The purpose of this case report is to establish the multi-disciplinary approach to rehabilitation in a novel patient case. The report establishes the safety and importance of rehabilitation interventions during two phases of the patient's critically complex medical course.

Case Presentation: A 50-year-old male diagnosed with advanced idiopathic pulmonary fibrosis that required ECMO support as a bridge to lung transplantation. During the pre-transplantation phase, the patient suffered significant decline leading to the development of right-sided heart failure and acute kidney injury. The severity of his medical condition required multiple re-configurations of the ECMO circuit to maximize cardio-respiratory support. Rehabilitation interventions were implemented during both pre- and post-transplant stages with emphasis placed on a multi-disciplinary approach to delivery of interventions.

Outcomes: On day 50, the patient underwent successful bilateral lung transplantation. During both phases, there were no adverse events during any rehabilitation session. In addition, the patient progressed from fully dependent in the initial stages to a modified independence state at hospital discharge. The complicated and novel case (IPF developing right sided heart failure requiring multiple cannulation strategies) demonstrates the feasibility and importance of physical therapy to improve pre-transplantation status as well as maximize outcomes following surgery.

Discussion: There is limited evidence describing rehabilitation interventions for critically ill patients requiring ECMO support. This case report confirms that physical therapy can be safely implemented in the most complex cases. The case report also attempts to show the importance of implementing physical therapy to best prepare the patient for transplantation surgery.

Introduction

Extracorporeal Membrane Oxygenation Support (ECMO) is a therapeutic intervention utilized for patients suffering from cardio-respiratory failure. ECMO, the highest level of life support, allows for different perfusion strategies to temporarily support patients as they recover or to facilitate as a bridge to transplantation (heart or lung) [1,2]. ECMO provides cardiorespiratory support by facilitating gas exchange and perfusion through a device outside the body. Cannulas placed in large caliber veins direct deoxygenated blood to the membrane oxygenator outside the body. The oxygenator replenishes oxygen and removes carbon dioxide through the juxtaposition of airflow and blood across a semipermeable membrane. The blood is then returned through a different channel (either in the same cannula – double lumen cannulation, or in a different cannula – two single lumen cannulae). A pump (commonly, a centrifugal pump in adults) assists the flow through the circuit and may also, in Veno-arterial (VA) ECMO contribute directly to the generation of an arterial pressure gradient; this promotes adequate systemic perfusion. VenoVenous (VV) ECMO (drainage from and return to the venous system) is used primarily for respiratory support in acute respiratory failure to manage refractory hypoxia, hypercapnia and respiratory acidosis or both [1]. Comparatively, VA ECMO is used for hemodynamic support in patients with decompensated heart failure who may also have respiratory compromise [1,2].

OPEN ACCESS

*Correspondence:

Kirby Mayer, Samantha Mancuso,
Rehabilitation Sciences Doctoral
Program, College Health Sciences,
University of Kentucky, 900 S.
Limestone, CTW Lexington, KY 40536-
0200, USA,

E-mail: kirby.mayer@uky.edu

Received Date: 26 May 2017

Accepted Date: 07 Jul 2017

Published Date: 17 Jul 2017

Citation:

Mancuso S, Mayer K, Gonipath
A. Benefits of Physical Therapy
Interventions for a Patient with End-
Stage Pulmonary Disease who
developed Right-Sided Heart Failure
Requiring ECMO Support Bridging to
Lung Transplantation. *Ann Clin Case
Rep.* 2017; 2: 1402.

ISSN: 2474-1655

Copyright © 2017 Kirby Mayer. This is
an open access article distributed under
the Creative Commons Attribution
License, which permits unrestricted
use, distribution, and reproduction in
any medium, provided the original work
is properly cited.

Table 1: Physical therapist initial systems review.

System	Findings
Cognition	Responses to name with eyes opening; reduced communication; limited command following; decreased attention/arousal
Musculoskeletal	BUE and BLE = PROM WFL
Neuromuscular	Bilateral shoulders = 1/5 grossly Bilateral elbows = 3-/5 Bilateral grip = 3-/5 Bilateral ankles = 3-/5 Unable to accurately assess hip and knee MMT due to decreased arousal (grossly 1/5 for bilateral hip and knee strength)
Integumentary	Stage II sacral pressure ulcer – interventions being performed by wound care Nurse.
Kansas Functional Outcome	1/28

Abbreviations: BUE: Bilateral Upper Extremities; BLE: Bilateral Lower Extremities; RUE: Right Upper Extremity; LUE: Left Upper Extremity; PROM: Passive Range Of Motion; WFL: With Functional Limitations.

ECMO interventions are high-risk, invasive procedures undertaken in critically-ill patients. A multi-center randomized controlled trial (CESAR) in the UK compared ECMO with conventional mechanical ventilation for severe Acute Respiratory Distress Syndrome (ARDS). The CESAR study suggested that ECMO was associated with an improved rate of survival [3]. The collaboration of the multidisciplinary team is essential to maximizing the benefits of ECMO therapy. However, ECMO is not without its complications. The nature of the device presents multiple risks including hemorrhage, extremity ischemia, thrombosis, infection, and pump/oxygenator failure [4]. Complications also arise from the complexity of treating a critically-ill patient including prolonged immobility, use of sedation, and long term mechanical ventilation [5-7]. To address these issues, early mobilization has been identified as a key intervention. Recent research has established that early mobilization has many benefits including improved survival rates, prevention of multi-organ system failure, prevention of pressures ulcers and reduction in long-term, critical illness related to neuromuscular dysfunction [5,6,8,-12]. Rehder et al. [13] found that “awake ECMO” patients had improved survival rates, reduced wait-times to transplant surgery and notably shorter post-transplant length of hospital stay. Furthermore, it has been suggested that pre-transplant conditioning is an important predictor of morbidity and mortality in patients who undergo ECMO therapy [13].

Early mobilization in patients requiring ECMO is possible through improvements in technology. The introduction of the Avalon double lumen cannulas, improved portability, and enhanced membrane oxygenator design has allowed patients to mobilize easier and with reduced risks. The use of ECMO has allowed facilitated a reduction in the need for mechanical ventilation and sedation in patients with ARDS, allowing them to engage in Activities of Daily Living (ADL) as well as rehabilitation exercises.

Rehabilitation in the form of physical therapy may improve physical functioning and conditioning; this is likely to better prepare critically ill patients for either organ transplant or return to baseline functioning prior to critical illness. The complexity of cannulation strategies, disease types and patient demographics present a challenge in terms of validating physical therapy interventions in patients receiving ECMO therapy. Furthermore, evidence supporting physical therapy interventions with patients on ECMO is limited. Case reports, however, can provide insight and confirm the need for early physical therapy interventions with this select population.

The purpose of this case report is to describe safe and effective physical therapy interventions utilized to treat a patient with end-stage pulmonary disease as he awaited transplantation (on ECMO)

and in the post-transplant recovery phase. The patient case is a novel case due to the complexity of the patient’s pre-transplant medical condition requiring multiple re-configurations of the ECMO circuit due to his deteriorating medical condition including onset of right-sided heart failure. The physical therapy plan of care required ongoing modifications as cannulation strategies were adjusted to provide continued support in the face of progressive cardiopulmonary disease.

Clinical Findings and Hospital Stay

A 50-year-old male with significant past medical history of COPD and histoplasmosis was hospitalized in February 2014 for pneumonia and then transferred to the University of Kentucky on April 5, 2014. Initially, he required high-flow supplemental oxygen to maintain oxygen saturation; however, in spite of significant support, he continued to become progressively more hypoxemic. An extensive workup including clinical assessment, radiographic picture, and bronchoscopy results were consistent with a new diagnosis of advanced idiopathic pulmonary fibrosis. Due to the patient’s clinically deteriorating lung function and likely candidacy for lung transplantation, the patient was brought to the Cardiothoracic Intensive Care Unit to initiate Veno-Venous (VV) ECMO. This was performed with a size 27 French Avalon cannula inserted through the right internal jugular vein with a goal of bridging the patient to lung transplantation. After cannulation, the patient developed an Acute Kidney Injury (AKI) with etiology of acute tubular necrosis likely a combination of low flow (flow of approximately 4.2 Liters) and high vancomycin levels; he eventually required continuous renal replacement therapy and intermittent hemodialysis which complicated mobility as well. He underwent a tracheostomy on day 5 to help with ambulation on ECMO and his kidney function continued to worsen. On day 12, due to concerns for right heart failure (Table 1) and continued less than optimal oxygenation, he was transitioned to venoarterial-venous (VAV) ECMO with cannulation in the left femoral artery with a 17 French cannula to provide enhanced systemic perfusion and support; this ultimately provided an additional two liters of flow. On day 15, he was transitioned to venovenous-arterial (VVA) ECMO with de-cannulation of the left femoral arterial cannula and placement of a right axillary arterial 22 French cannula. This promoted enhanced mobility with few limitations to walking except use of the right shoulder.

On day 55, he underwent bilateral orthotopic lung transplantation which was complicated by bleeding of the left hemithorax necessitating re-exploration of the surgical site and administration of favor VII. Due to this complication, the patient was left with an open sternotomy which was closed on post-operative day 3. This limited the patient to passive range of motion only during that time. Also,

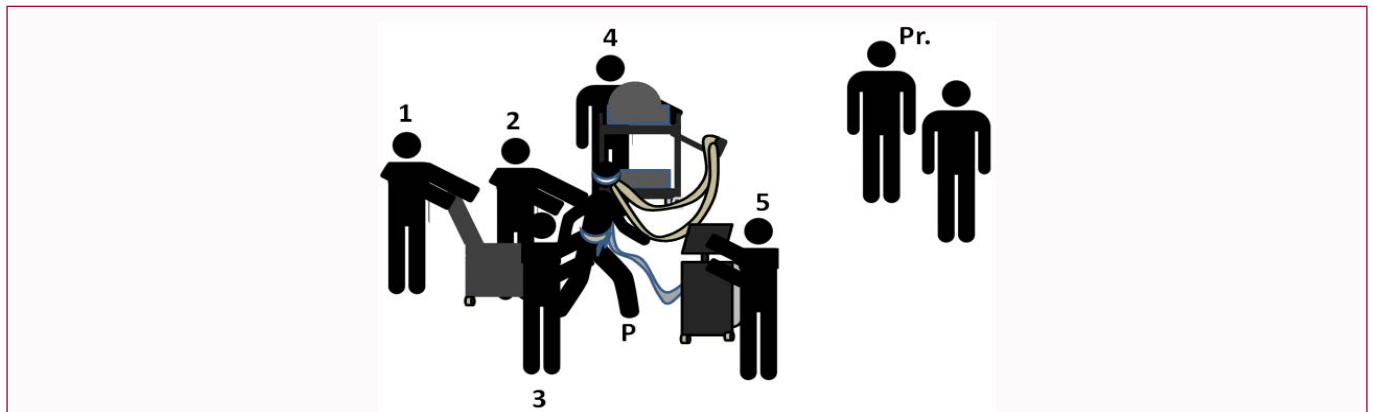


Figure 1: ECMO Mobility Interdisciplinary Team.

The multidisciplinary team is essential to the safety of ambulatory ECMO programs and the success of therapy interventions aimed at preventing deconditioning prior to transplant so that post-transplant outcomes may be optimized.

Key: 1: Nursing Care Technician or Physical Therapy Technician; 2: Physical Therapist; 3: Occupational Therapist; 4: Perfusionist or Nurse; 5: Respiratory Therapist; Pr.: Physician, Advanced Practice Provider, or Nurse; P: Patient on ECMO.

during that time, there was concern for subclinical seizures (clinically, a change in mental status with abnormal EEG findings of generalized slowing and intermittent bifrontal and right fronto-temporal sharp waves). On day 58, he returned to OR for pleural washout, closure of the sternum, and therapeutic bronchoscopy. During recovery phase of transplantation, he required frequent therapeutic bronchoscopic procedures to clear secretions daily initially and moving out to every other day. On day 106, his tracheostomy was removed and he was discharged from the hospital the next day.

The Incorporation of Physical and Occupational Therapy Interventions to Promote Mobility

This patient required ECMO for irreversible end-stage respiratory failure as a means of bridging to lung transplantation. Physical therapy interventions are vital to prepare for a successful surgery and promote recovery following surgery to minimize deconditioning and optimize functional status. Physical therapy in the postoperative period is equally as important to the success of the patient with emphasis placed on restoring independence and functional mobility.

In the bridge to transplant and recovery stages, the goal of physical therapy interventions is to optimize physical functioning in order to maximize medical outcomes and quality of life following discharge from the hospital. The severity of this patient's illness presented multiple barriers to rehabilitation. First, safety is a primary concern in all phases of hospitalization. This is further emphasized when a patient is receiving ECMO therapy. Ensuring safety of the ECMO patient requires a well-coordinated multidisciplinary approach with the assistance of many care providers (Figure 1). Effective communication with all involved parties is essential to ensure safe and effective therapy. Collaboration to ensure the ECMO circuit is constantly monitored to decrease risk of an adverse event is essential. Potential risks include dislodgement of a thrombus during physical activity, mal-positioning of cannulas resulting in decreased flow, and the accidental disengagement of cannula connections that could result in massive hemorrhage and distributive shock. These risks can result in fear or uncertainty of the multidisciplinary team; thus, extensive training and troubleshooting of problems is required of all professional working with patients on ECMO. Figure 1 describes how the Mechanical Circulatory Support (MCS) team organized ECMO

mobility.

Additionally, early mobility is further restricted by placement of certain arterial cannulations. For example, this patient had a femoral arterial cannulation present initially which limited hip flexion; hip flexion can occlude the cannula preventing blood flow to the distal extremity and the body overall. This occurred in this case study and was one reason for fewer PT interventions prior to transplantation. In most cases supine interventions can still be conducted but are not preferred to exercises that involve standing and walking because upright exercise engage all of the muscles, promote trunk control and improve strength.

Furthermore, the placement of arterial cannulations in areas such as the axillary artery can limit ROM of the upper extremities, resulting in decreased strength and deconditioning that affects independent activities of daily living. This cannulation limited occupational therapy treatments to the fullest extent for this particular patient. Thus, the rehabilitation plan of care must be fulfilled in a way that addresses cannulation sites to promote safety and optimizing treatment.

Physical Therapy Examination

The initial physical therapy evaluation was conducted on day 6 (two days after initiation of ECMO support). In addition to the physical therapist, a perfusionist, nurse, and a nursing care technician were present for initial examination to monitor the patient and ECMO circuit. The patient was able to follow commands, but required constant verbal and tactile cues to maintain alertness; he was repeatedly distracted by fatigue and inability to keep his eyes open. He communicated with hand and facial gestures as he was unable to vocalize due to tracheostomy placement. The patient required dependent assistance to perform rolling in bed as well as moving from supine to sitting at the edge of the bed. Once in the sitting position, he had difficulty maintaining control of his trunk and head without support from the therapist. The patient remained sitting for twelve minutes with vital signs stable, but had severe difficulty maintaining arousal, requiring repeated stimulation. The physical therapist determined that the patient could not safely attempt standing due to severe weakness, fatigability, and difficulty maintaining arousal. In addition, muscle manual testing was difficult to fully assess; he had significant weakness throughout. This signifies the weakness and deconditioning from reduced mobility from initial hospitalization in

Table 2: Physical and occupational therapy treatments prior to bilateral lung transplantation.

Physical and Occupational Therapy Treatments Prior to Bilateral Lung Transplantation					
Date	Manual Muscle Testing Results	Time standing (minutes)	Kansas University PT Acute Care Functional Outcomes Score	Barthel Activities of Daily Living Index	Therapist Comments
5/5/14	BUE: 3/5 BLE: 4/5	0	12/28		Difficulty with balance, coordination, decreased strength and significant activity intolerance
5/9/14	BUE: 4/5 BLE: 4/5	0		20/100	Improved strength; No resistance with right shoulder
5/20/14	BUE: 3/5 BLE: 4/5	3	9/28		Right shoulder flexion limited due to arterial axillary cannula
5/23/14	RUE proximal: 4/5 RUE distal: 5/5 LUE proximal: 4+/5 LUE distal: 5/5 BLE: 4/5	3		30/100	Right shoulder flexion limited due to arterial axillary cannula

This is a timeline of physical and occupational therapy treatments prior to bilateral lung transplantation on 5/28/14. The pt. was originally cannulated for veno-venous (VV) ECMO in the left internal jugular vein on 4/9/14. On 4/17/14, there was an additional arterial cannula added in the left femoral artery which was later taken out in exchange for the placement of a right axillary artery cannula placed on 4/20. Femoral cannulations limit mobility including any activity where the body is greater than 30 degrees and axillary artery cannulations limit range of motion (ROM) of the left arm which is where it is typically placed. The Kansas University Physical Therapy (PT) Acute Care Functional Outcomes Score was scored by a physical therapist. The higher the score on the Kansas University PT Acute Care Functional Outcomes Score means the patient is able to physically function at a higher level. The Barthel Activities of Daily Living (ADL) Score was scored by an occupational therapist. The higher the score out of 100 on the Barthel ADL score, the less functional impairment of the patient's ADLs they have.

Abbreviations: BUE: Bilateral Upper Extremities; BLE: Bilateral Lower Extremities; RUE: Right Upper Extremity; LUE: Left Upper Extremity.

February as well as one week of full immobility.

The initial assessment revealed that his functional mobility was severely impaired due to severely decreased activity tolerance from poor cardiopulmonary function. Prolonged immobility (~37 days immobility: 6 days in our hospital plus 31 days at transferring facility) resulted in significant weakness and reduced physical functioning. Based on his initial physical therapy evaluation combined with evolving medical condition, the patient was a poor candidate for lung transplantation. An intensive physical therapy plan was developed and implemented to improve his candidacy in preparation for lung transplantation. An updated plan was established following surgical interventions to focus on interventions to maximize independence and functional mobility.

Therapeutic Interventions

Pre-transplantation interventions (Bridge phase)

During the pre-transplantation phase or bridge phase physical therapy interventions focused on tolerance to activity to improve overall physicality. Initially the patient engaged in bed mobility tasks and sitting upright at the edge of the bed with assistance. Progression to standing interventions were delayed as the patient presented with severe weakness, deconditioning, and a femoral arterial cannula which prevented this. The physical therapist gradually progressed interventions by reducing the assistance level with tasks in bed and during sitting upright, thus maximizing patient work load. The therapist continued this progression until the patient demonstrated improved core and trunk strength in the sitting then standing positions. The first standing interventions lasted only a few seconds and the patient required substantial assistance to achieve and maintain erect, upright position.

In addition to sitting and standing interventions in the bridge phase, the therapist emphasized therapeutic exercises to increase tolerance to activity and improve strength. The therapist encouraged the family to assist the patient with performance of these exercises three times per day, providing written instruction and verbal feedback. These exercises focused on gross movements of the arms and legs to improve global strength and cardiovascular function. Exercises were crucial on days when the physical therapist was not

available to incorporate mobility into the daily plan of care. In the bridge phase, mobility other than rolling in bed was deferred multiple days due to evolving medical condition including development of right-sided heart failure with patient requiring changes in location of cannulation, femoral cannulas, femoral central lines, decreases in alertness, worsening of kidney function and hemodynamic instability. His right-sided heart failure included severe dilatation of the right ventricle and pulmonary artery resulting in an estimated right ventricular systolic pressure of 50 mm Hg to 60 mm Hg. The patient also had peripheral signs including peripheral edema, hepatic steatosis, and borderline splenomegaly. See Table 2 for a summary of interventions.

Post-transplantation interventions (Recovery phase)

Following surgery, the patient was severely debilitated with significant weakness. During the immediate postoperative period, the patient was critically ill requiring extensive medical interventions including vasopressor support to maintain adequate blood pressure and subsequent perfusion. After sternal closure and washout, the patient's clinical condition began to improve each day, allowing for increased participation in daily physical therapy interventions. The patient engaged in a variety of rehabilitation interventions including bed mobility training, transfer training, gait training, therapeutic exercises, balance training and activity tolerance training. Given the duration and complexity of his critical illness, the patient had to re-learn how to perform many ADLs such as bathing, dressing, toileting, hygiene, eating and transferring. The physical therapist utilized a variety of strategies for learning including the cognitive and psychomotor domains. Strategies included verbal and tactile cues as well as demonstration of activities with teach back methods. Learning was evaluated using return demonstration of psychomotor skills and limiting feedback as time progressed to allow the patient time to reflect on importance of skills learned; this utilized the affective learning domain.

During the recovery phase, the patient followed a gradual progression pattern that was positive in nature. Each therapy session, the patient demonstrated improved strength and tolerance translating to less assistance. For example, after transplantation, the patient required max assistance of two people to perform one sit

Table 3: Physical and occupational work post bilateral lung transplantation.

Physical and Occupational Therapy Treatments Post Bilateral Lung Transplantation				
Date	Manual Muscle Testing Results	Ambulation (feet)	Kansas University PT Acute Care Functional Outcomes Score	Barthel Activities of Daily Living Index
5/30/14	Not able to perform; LUE moves vs. gravity Moving right side spontaneously	0*	0/28	
5/31/14	Bilateral hands 2-/5 Right elbow 1/5 Left elbow: 2-/5 Bilateral shoulders: 1/5 Bilateral hips and knees: 0/5 Right ankle: 2-/5 Left ankle: 0/5 BLE: 4/5	0*		0/100
6/11/14	Bilateral shoulders: 3-/5 Bilateral elbow: 3/5 Bilateral grips 3+/5 RLE: 3+/5 LLE: 3-/5	50	11/28	
6/18/14	Left shoulder 3-/5 Right shoulder: 3/5 Bilateral elbows: 3/5 Bilateral grips: 3+/5 BLE: 3/5	N/A		30/100
6/24/14	Bilateral shoulders: 3/5 Bilateral elbows: 3/5 Bilateral grips: 3+/5 BLE: 3+/5	370	19/28	
7/2/14	RUE: 3/5 LUE: 2+/5 BLE: 3+/5			60/100
7/5/14	RUE proximal: 3/5 RUE distal 3+/5 LUE proximal 3-/5 LUE distal 3/5 BLE: 3/5	600	19/28	
7/16/14	Full functional movement; BUE= BLE	1,000	24/28	

This Table describes the timeline of physical and occupational therapy treatments post bilateral lung transplant on 5/28/14. The patient returned from the operating room on 5/28/14 with an open sternotomy due to intraoperative bleeding. He returned to the operating room on 6/1/14 for sternal closure and pleural washout of the left chest which limited physical and occupational therapy treatments beyond passive range of motion. The Kansas University Physical Therapy (PT) Acute Care Functional Outcomes Score was scored by a physical therapist. The higher the score on the Kansas University PT Acute Care Functional Outcomes Score means the patient is able to physically function at a higher level. The Barthel Activities of Daily Living (ADL) Score was scored by an occupational therapist. The higher the score out of 100 on the Barthel ADL score, the less functional impairment of the patient's ADLs they have. occupational therapy treatment due to the inability of the patient to perform certain range of motion (ROM).

*Denotes that the patient only participated in passive ROM at that point in time.

Key: BUE= bilateral upper extremities; BLE= bilateral lower extremities; RUE= right upper extremity; LUE= left upper extremity; PT= physical therapy

to stand transfer. Two weeks after surgery, the patient could stand with moderate assist of one person. Once the difficulty of standing decreased, the therapist initiated bed to chair transfer training. This intervention expanded upon sit to stand transfer with the addition of pivoting to a chair. This eventually evolved to side to side and forward steps from the bed to the chair. This was a significant milestone as this allowed him to sit upright in a chair for extended periods, but also marked the beginning of gait training. This has great implications for his respiratory status postoperatively as it allowed him to properly expand the lungs and participate in pulmonary hygiene with physical exercise.

As time progressed, walking became an important component of the patient's physical therapy. Ambulation demands global strength, tolerance to activity, coordination, and balance. Once the patient demonstrated the strength to participate in ambulation, the therapist shifted focus from tasks in the sitting position to maximizing his ability to walk. The patient, once again, gradually improved his ambulation distance as the days passed. Initially, he required support of a thoracic walker with multiple rest periods to travel a total of fifty feet. Goals for ambulation were communicated to the multidisciplinary team to promote recovery for the patient including the use of nursing and

ancillary staff. At discharge, the patient successful performed 1000 feet of ambulation using a rolling walker and only contact guard assist for safety. See Table 3 for the patient's physical and occupational therapy milestones.

Post transplantation, therapeutic exercises were used in adjunct to the patient's daily session of therapy that included ambulation. A detailed, progressive exercise program was established including upper and lower extremities exercises performed at least three times a day. These exercises focused on isolated muscle strengthening due to severe weakness in the patient's hips, shoulders, and core. The therapist also initiated and coordinated care to include exercises against manual resistance or a resistive exercise band. Patient confidence and motivation to perform the home-exercise plan was crucial to his adherence to his therapy regimen during the recovery phase. As the patient's functional mobility improved, the therapist initiated higher-level exercises such as standing dynamic balance exercises.

Discussion

The patient had very little cardiopulmonary reserve and reduced muscular endurance both pre and post-bilateral lung transplantation.

Activity tolerance training was implemented into every session not separately as it is in some circumstances. The patient participated in physical therapy interventions at minimum five times per week as well as daily activity and exercises driven by nursing and family during both stages pre- and post-transplantation. Nursing and family provided interventions were directed by the therapists. In addition to physical therapy, the patient received interventions focused on strength and activity from an occupational therapist. After discharge, the patient repeatedly stated his thankfulness for the ability to perform simple task such as brushing his teeth or washing his hair with the occupational and physical therapist. The use of the multidisciplinary team as well as role identification for the patient's family seemed to optimize the patient's experience and allow him to grow both physically and mentally. Particularly, nursing staff and the family focused on mental well-being; they served as a major source of psychosocial support for the patient in his journey to recovery. Close communication and education delivered by the physical therapist positively influenced the patient's strength and tolerance both pre and post-transplant. Task completion improved as the need for rest breaks slowly dissipated. As the patient grew more tolerant of activity, his confidence increased. The patient seemed to gain more self-efficacy as well which also greatly improved his tolerance to activity because he believed he could achieve the goals set forth before him.

In regards to functionality, the patient improved his score on the Kansas Functional Outcome Measure from a 1/28 on initial PT evaluation to a 24/28 at discharge. In addition, the patient was performing bed mobility, transfers, and ADLs with modified independence; this was a significant improvement from dependency at initial evaluation. During his final PT intervention, the patient performed 1,000 feet of gait with an assistive device, on room air with no rest breaks and no assistance.

It is important to note that during the patient's physical therapy program, no adverse events occurred during any activity. Both phases of rehabilitation were performed in a safe, controlled environment with a strong emphasis on communication between the multidisciplinary team. Additionally, physical therapy interventions did not result in the worsening or acute changes of the patient's medical condition at any point in time. As the patient progressed, the therapist increased the difficulty of intervention to appropriately challenge the patient's functional status and mobility. As the patient progressed, the proper number of staff and care providers was available. This often included a one to one ratio of the primary nurse to the patient in addition to physical rehabilitation technicians, nursing care technicians, therapists (both physical and occupational), perfusionists, and respiratory therapists. The multidisciplinary involvement of this patient was essential to his success in therapy while on ECMO as well as post transplantation.

Conclusion

This case reports demonstrates how a fifty-year-old patient with idiopathic pulmonary fibrosis was able to safely ambulate while on ECMO and how that therapy improved his functional status post-transplant. Although his medical course was complicated by right-sided heart failure, physical therapy interventions proved effective and did not result in any adverse events or negative unintended consequences in regards to his medical condition. This case shows how a well-integrated physical rehabilitation program contributed to the patient's improved physicality, activity tolerance, and self-efficacy in regards to physical activity.

The methodology used in this case is based on evidence that suggests physical rehabilitation can be successful in patients who require ECMO support suffering from advanced lung disease [14]. Furthermore, clinicians have noted that therapy can be safe and effective for patients awaiting lung transplantation; however, there is limited research in this population [15]. As the use of ECMO increases, more evidence is needed to support mechanical circulatory support (MCS) programs in their development of ambulatory ECMO teams. Identification of how therapy is initiated, communicated to the interdisciplinary team, and implemented with the assistance of multiple disciplines can set a foundation for the development of such programs. The determination of valid and reliable tools to track physical progress in this population would also be beneficial. Therefore, it is important to identify trials, tribulations, and lessons learned so that the care of patient's on ECMO therapy may be improved.

References

1. Shekar K, Mullany DV, Thomson B, Ziegenfuss M, Platts DG, Fraser JF. Extracorporeal life support devices and strategies for management of acute cardiorespiratory failure in adult patients: a comprehensive review. *Crit Care*. 2014; 18: 219.
2. Fraser JF, Shekar K, Diab S, Dunster K, Foley SR, McDonald CI, et al. ECMO – the clinician's view. *ISBT Science Series*. 2012; 7: 82-88.
3. Thalanany MM, Mugford M, Hibbert C, Cooper NJ, Truesdale A, Robinson S, et al. Methods of data collection and analysis for the economic evaluation alongside a national, multi-centre trial in the UK: conventional ventilation or ECMO for Severe Adult Respiratory Failure (CESAR). *BMC Health Serv Res*. 2008; 8: 94.
4. Tramm R, Ilic D, Davies AR, Pellegrino VA, Romero L, Hodgson C. Extracorporeal membrane oxygenation for critically ill adults. *Cochrane Database Syst Rev*. 2015; 1: CD010381.
5. De Jonghe B, Sharshar T, Lefaucheur J, Authier FJ, Durand-Zaleski I, Boussarsar M, et al. Paresis acquired in the intensive care unit: A prospective multicenter study. *JAMA*. 2002; 288: 2859-2867.
6. Needham DM. Mobilizing patients in the intensive care unit: Improving neuromuscular weakness and physical function. *JAMA*. 2008; 300: 1685-1690.
7. Desai SV, Law TJ, Needham DM. Long-term complications of critical care. *Crit Care Med*. 2011; 39: 371-379.
8. Thomsen GE, Snow GL, Rodriguez L, Hopkins RO. Patients with respiratory failure increase ambulation after transfer to an intensive care unit where early activity is a priority. *Crit Care Med*. 2008; 36: 1119-1124.
9. Bailey P, Thomsen GE, Spuhler VJ, Blair R, Jewkes J, Bezdjian L, et al. Early activity is feasible and safe in respiratory failure patients. *Crit Care Med*. 2007; 35: 139-145.
10. Morris PE, Goad A, Thompson C, Taylor K, Harry B, Passmore L, et al. Early intensive care unit mobility therapy in the treatment of acute respiratory failure. *Crit Care Med*. 2008; 36: 2238-2243.
11. Burtin C, Clerckx B, Robbeets C, Ferdinande P, Langer D, Troosters T, et al. Early exercise in critically ill patients enhances short-term functional recovery. *Crit Care Med*. 2009; 37: 2499-2505.
12. Needham DM, Korupolu R, Zanni JM, Pradhan P, Colantuoni E, Palmer JB, et al. Early Physical Medicine and Rehabilitation for Patients with Acute Respiratory Failure: A Quality Improvement Project. *Arch Phys Med Rehabil*. 2010; 91: 536-542.
13. Rehder KJ, Turner DA, Hartwig MG, Williford WL, Bonadonna D, Walczak RJ Jr, et al. Active rehabilitation during extracorporeal membrane oxygenation as a bridge to lung transplantation. *Respir Care*. 2013; 58: 1291-1298.

14. Rahimi RA, Skrzat J, Reddy DR, Zanni JM, Fan E, Stephens RS, et al. Physical rehabilitation of patients in the intensive care unit requiring extracorporeal membrane oxygenation: a small case series. *Phys Ther.* 2013; 93: 248-255.
15. Turner DA, Cheifetz IM, Rehder KJ, Williford WL, Bonadonna D, Banuelos SJ, et al. Active rehabilitation and physical therapy during extracorporeal membrane oxygenation while awaiting lung transplantation: a practical approach. *Crit Care Med.* 2011; 39: 2593-2598.