



Application of the “4S” Technique - A Modified Double-Incision Extracapsular Cataract Extraction Combined with IOL Implantation in a Senile Cataract Patient with Low Corneal Endothelial Cell Density: A Clinical Report

Chao-Yue Wang, Qing Xu*, Chen Yang and Xin Tian

Yueyang Hospital of Integrated Traditional Chinese and Western Medicine, Shanghai University of Traditional Chinese Medicine, China

Abstract

We describe a case of senile cataract with congenital low corneal endothelial cell density in our patient. This is a case report of an 81-year-old woman who had developed a progressive deterioration of binocular vision without obvious inducement one year ago. Her best preoperative corrected visual acuity was 20/80 in her right eye and 20/50 in her left eye. Slit-lamp examination showed a C4 cortical opacification (LOCS II) of the lens OD (C3 in OS), grade III nucleus in both eyes (Emery scale). To reduce the loss rate of Corneal Endothelial Cells (CECs) during surgery, we implemented a safer way - the “4S” technique, a modified double-incision Extracapsular Cataract Extraction (ECCE) combined with IOL implantation. The patient’s vision recovered well and remained stable. Although PHACO has become the mainstream surgical method due to its several advantages, ECCE is still preferred in patients with low CEC count and high nuclear hardness. The “4S” technique can be used as a new cataract surgery method to protect the corneal endothelium in patients with low CEC density.

OPEN ACCESS

*Correspondence:

Qing Xu, Yueyang Hospital of Integrated Traditional Chinese and Western Medicine, Shanghai University of Traditional Chinese Medicine, Shanghai 200080, China,

E-mail: xqinganan@126.com

Received Date: 16 Aug 2022

Accepted Date: 01 Sep 2022

Published Date: 05 Sep 2022

Citation:

Wang C-Y, Xu Q, Yang C, Tian X. Application of the “4S” Technique - A Modified Double-Incision Extracapsular Cataract Extraction Combined with IOL Implantation in a Senile Cataract Patient with Low Corneal Endothelial Cell Density: A Clinical Report. *Ann Clin Case Rep.* 2022; 7: 2296.

ISSN: 2474-1655.

Copyright © 2022 Qing Xu. This is an open access article distributed under the Creative Commons Attribution License, which permits unrestricted use, distribution, and reproduction in any medium, provided the original work is properly cited.

Keywords: Extracapsular Cataract Extraction (ECCE); Senile cataract; Cornea endothelial cell

Introduction

This case indicates even now PHACO has probably become the mainstream surgical method; ECCE is still preferred in patients with low CEC count and high nuclear hardness. The “4S” technique could be used as a customized cataract surgery method to protect the corneal endothelium.

Case Presentation

An 81-year-old female complained of a progressive deterioration of binocular vision without obvious inducement for a year. Her Corrected Distance Visual Acuity (CDVA) was 20/80 in her right eye (OD) and 20/50 in her left eye (OS). Slit-lamp examination showed a C4 cortical opacification (LOCS II) of the lens OD (C3 in OS), grade III nucleus in both eyes (Emery scale), and normal anterior chamber with the depth of 2.5 mm in both eyes. The specular microscope found the patient had a low density of CEC, 867 cells/mm² OD, and 790 cells/mm² OS, but the Central Corneal Thickness (CCT) was normal: 501 μm OD and 509 μm OS. Moreover, the cells were regular in shape, tightly connected, and equal in size. Other ophthalmic examinations showed no other pathological changes in both eyes.

With the diagnosis of senile cataract, the patient was scheduled for modified double-incision ECCE combined with Intraocular Lens (IOL) implantation, which aimed to minimize damage to the corneal endothelium. The scleral incision was made at 12:00 position 3 mm posterior to the limbus and corneal incision at 9:00. After fully inflating the anterior chamber with the viscoelastic agent (DisCoVisc), we created an 8mm circular anterior capsulectomy with a Continuous Curvilinear Capsulorhexis (CCC), and then the viscoelastic agent was used instead of BSS for the nucleus dissection. The viscoelastic agent was injected into the posterior to the nucleus, facilitating the prolapse of the nucleus into the anterior chamber (Figure 1). With the help of continuous injection of the viscoelastic agent and simultaneously slight pressure on the post lip of the 10 mm incision, the lens nucleus slid out readily (Figure 2). The 10 mm incision was sutured for 3 stitches, and the residual cortex was aspirated clockwise after one-time insertion of the instrument into the capsule

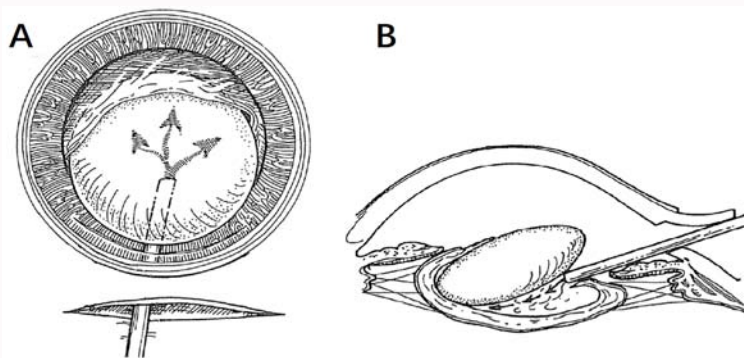


Figure 1: Prolapse of the nucleus into the anterior chamber is facilitated by injection of the viscoelastic agent posterior to the nucleus. (A) Front view, (B) Side view.

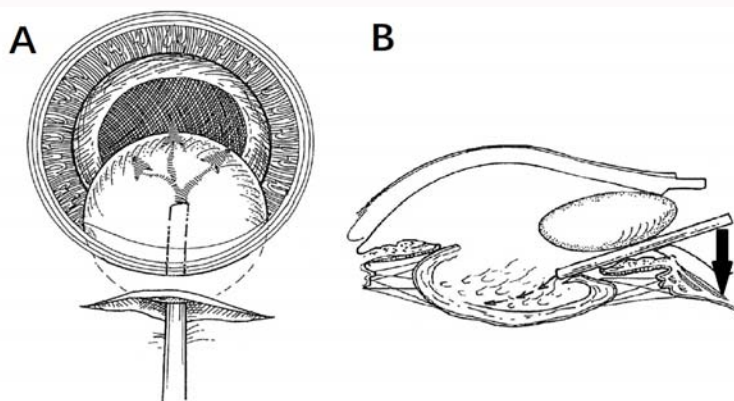


Figure 2: Continue injecting viscoelastic into the posterior of the nucleus; meanwhile gently press the post lip of the incision to make the nucleus slides out. (A) Front view, (B) Side view.

Table 1: Summary of visual acuity (Diopters) and intraocular pressure over 6-month review period.

Day		Preoperative	Postoperative			
			1d	30d	90d	180d
CDVA	OD	20/80	20/30	20/25	20/25	20/20
	OS	20/50	20/60	20/40	20/25	20/25
IOP	OD	14.3	39	11.2	10.2	14.5
	OS	17	28	16.3	16.7	17.2

CDVA: Corrected Distance Visual Acuity; IOP: Intraocular Pressure (mmHg)

through the 2 mm incision. A +22.00D (+22.50D OS) intraocular lens (Rayner) was implanted with an injector through the remaining unsutured part of the wound. After residual viscoelastic was aspirated, the anterior chamber was irrigated with BSS.

Examinations at one day, one month, three months, and six months post-surgery showed clear pupils, a stable IOL, and no inflammatory or other complications. Grade I corneal edema was observed OS on the first-day post-surgery. The patient’s vision recovered well and remained stable (Table 1, 2).

Discussion

CEC’s regeneration ability is not sufficient to replace dead or injured cells, they often cover wounds with the spread or migration of neighboring cells [1], resulting in increased cell size and shape on the polymorphic changes. The count of central CECs in normal adults is 2986 ± 314 cells/mm², which decreases with age [2]. Corneal decompensation and subsequent bullous keratitis may occur in the condition of a lower count than 500 cells/mm² [3].

Table 2: Summary of central corneal endothelial density, central corneal thickness, hexagonal cell rate, and coefficient of variation of corneal endothelial cells over a 6-month review period.

Day		Preoperative	Postoperative		
			30d	90d	180d
CCD	OD	867	640	710	641
	OS	790	467	685	626
CCT	OD	501	547	563	513
	OS	509	543	533	528
HEX	OD	67	50	48	47
	OS	55	43	41	39
CV	OD	21	25	19	14
	OS	25	19	27	26

Mean cell loss rate 23.41%

CCD: Central Corneal Endothelial Cell Density (cells/mm²); CCT: Central Corneal Thickness (μm); HEX: Hexagonal cell rate (%); CV: Coefficient of Variation (%)

Since it was an individual case, the overall CEC count was unknown, only the preoperative and postoperative central CEC density was compared. Therefore, in our case, the mean loss rate of central CEC density in both eyes was 23.41%. In this case, we took the “4S” technique to protect the corneal endothelium: (1) Smooth slide-out: The length of the primary incision (the scleral incision) was slightly larger than the diameter of the nucleus. Besides, injecting the viscoelastic agents behind the nucleus while gently squeezing the post lip of the incision guaranteed that the lens slid out smoothly without the use of other auxiliary instruments. (2) Soft instrument: We make full use of these features as a soft instrument in surgery

since viscoelastic is a non-Newtonian fluid [4] that exhibits physical properties in response to changes in shear strain rate. It is to separate free nuclear tissue, maintain the anterior chamber depth and improve the success rate of CCC [5] when injected into the capsule because of its elasticity, jet swelling effect, and thickening ability. It wraps around the nuclear tissue, allowing the nucleus and viscoelastic to flow easily out of the incision without injuring the endothelium, thanks to its viscosity and damping effect. We also used hydrophilic IOLs [6] and high-adhesion viscoelastic agents [7], which are better for preserving anterior Chamber stability and preventing accidental injury. (3) Separate channel to implant IOL: To avoid injuring the corneal endothelium, the injector was still employed to implant the foldable IOLs, and the operation of adjusting the IOLs's position was limited. (4) Single operation, one step in place: When removing the cortex and viscoelastic agents, double sets of suction needles were inserted at once instead of repeated entry and exit to protect the endothelium.

The CEC's Hexagon Cell Ratio (HEX) and Coefficient of Variation (CV) should also be considered to determine the prognosis pre-surgery. Studies have shown [8] that there are differences in the morphology of CEC in age-related cataract patients of different ages. Therefore, morphological examination of CECs can determine the degree of ocular aging in patients to predict the rate of CEC loss post-surgery. For example, the central CEC density, in this case, was as low as 467 cells/mm² one month after surgery OS (Table 2). Lower than the critical value of corneal decompensation reported clinically the preoperative HEX and CV level was normal, suggesting the loss of CECs was relatively low and the postoperative outcomes were good.

Funding

Scientific research project of Shanghai Municipal Health Commission (202042309).

References

1. Joyce NC. Proliferative capacity of corneal endothelial cells. *Exp Eye Res.* 2012;95(1):16-23.
2. Zheng T, Le Q, Hong J, Xu J. Comparison of human corneal cell density by age and corneal location: An *in vivo* confocal microscopy study [J]. *Bmc Ophthalmol.* 2016;16(1):109.
3. Li-Xin X, Yao Z, Yusen H, Ying L. Corneal endothelial damage and its repair after phacoemulsification. *Zhonghua Yan Ke Za Zhi.* 2004;40(2):90-3.
4. Astarita G, Marrucci G, Joseph DD. Principles of non-Newtonian fluid mechanics. *J Appl Mech.* 1975;42(3).
5. Loskutov IA, Korneeva AV, Lebedev PA. The use of new cohesive ophthalmic viscoelastic in cataract surgery. *Clin Ophthalmol.* 2008;2(1):21-30.
6. HariPriya A, David FC. Comparison of surgical repositioning rates and outcomes for hydrophilic vs. hydrophobic single-piece acrylic toric IOLs. *J Cataract Refract Surg.* 2021;47(2):178-83.
7. Praveen MR, Koul A, Vasavada AR, Pandita D, Dixit NV, Dahodwala FF, et al. DisCoVisc versus the soft-shell technique using Viscoat and Provisc in phacoemulsification: Randomized clinical trial. *J Cataract Refract Surg.* 2008;34(7):1145-51.
8. Zhijian J, Min X, Jianhong D. Characteristics of corneal endothelial cells in patients with age-related cataract. *Adv Ophthalmol.* 2013;33(10):3.