



## Aggressive Angiomyxoma: A Case Report and Review of Literature

Tripti Saxena\*, Ruchi Singh, Meenu Walia, Bhuvnesh Guglani and Rooma Ambastha

Department of Radiation Oncology, Max Superspeciality Hospital, India

### Abstract

Aggressive Angiomyxoma is a rare slow growing mesenchymal tumor, which is usually encountered in females of reproductive age group and has a marked tendency for local recurrence. We report the case of an eighteen-year-old female who presented with a large gradually increasing swelling on the right labia majora. A wide excision was carried out and biopsy confirmed an aggressive Angiomyxoma. Adjuvant Tamoxifen was given in view of Estrogen receptor positive status and there has been no recurrence till the last follow up at 1 year post surgery.

**Keywords:** Aggressive angiomyxoma; Mesenchymal tumor; Local recurrence

### Introduction

Aggressive Angiomyxoma (AA) is a rare slow growing benign mesenchymal tumor, which is typically found in the pelvic and perineal regions in reproductive age females and infiltrates into the skeletal muscle and fat [1]. It usually presents as a painless growing mass, and is thus easily misdiagnosed as a groin hernia, Bartholin gland cyst, Lipoma or a gynecological malignancy. Other presenting complaints include dull aching pain, urinary and gastrointestinal symptoms such as dysuria, urinary retention and dyspareunia. This entity was first described by Steeper and Rosai in 1983 [2]. The recent WHO classification lists aggressive Angiomyxoma as a "Tumor of Uncertain Differentiation" [3]. The term aggressive emphasizes frequent local recurrence and its infiltrative nature [4]. Local recurrence may occur between 2 months to 15 years following the initial diagnosis and the recurrence rates vary from 9% to 72% [5]. Extension of the tumour to urethra, vagina, rectum and anal sphincter as well as extension through pelvic diaphragm is associated with incomplete resection and thus high risk of local recurrence. Considering its locally aggressive nature, an early diagnosis followed by appropriate management and follow up is of utmost importance to prevent future recurrences. Initially, AA has been regarded as a tumour with no metastatic potential, but this concept has now changed after few case reports of metastasis [6]. Unusual locations from where AA has been reported include Liver, Lungs, Larynx and Supraclavicular fossa [7]. Although common in females, some cases of AA have been reported in male patients as paratesticular masses. Literature on AA is scarce, most of it limited to case reports, with around 250 cases reported till date. Due to its rarity there is still a lack of consensus on the clinical presentation, treatment protocols and follow-up pattern of the tumor in the current literature. Hence, we are submitting our case by presenting the outcome of a patient who underwent excisional surgery for an AA.

### Case Presentation

An eighteen-year-old female presented with complain of white discharge per vagina for three weeks along with history of a nodular swelling over the perineal region for 5 years which was gradually increasing in size.

On local examination, a well circumscribed, pedunculated, ulcerated, lipo-hemangiomas mass measuring approximately 14 cm × 12 cm was present, arising from right labia majora. There was no evidence of pelvic organ prolapse with good support of the uterus, posterior wall, and anterior wall above the mass. The mass was nontender, soft and spongy in consistency. It did not appear to involve the rectum or urethra. No induration was palpated internally on vaginal or rectal exam. She had no symptoms of dysuria, pain, bleeding, or change in bowel and bladder habits. Her generalized and systemic examination was normal. Metastatic work up was done, and no systemic disease was found. CECT scan was performed and showed mild soft tissue thickening in right labia in the region of tumor pedicle. The main tumor mass was seen in posterior midline along intergluteal cleft showing homogenous soft tissue attenuation (Figure 1). FDG Whole body PET

### OPEN ACCESS

#### \*Correspondence:

Tripti Saxena, Department of Radiation Oncology, Max Superspeciality Hospital, 108A, IP Extension, Patparganj, Delhi, 110092, India, Tel: +91-8130458355; E-mail: drtriptisaxena@gmail.com

Received Date: 18 Jan 2021

Accepted Date: 08 Feb 2021

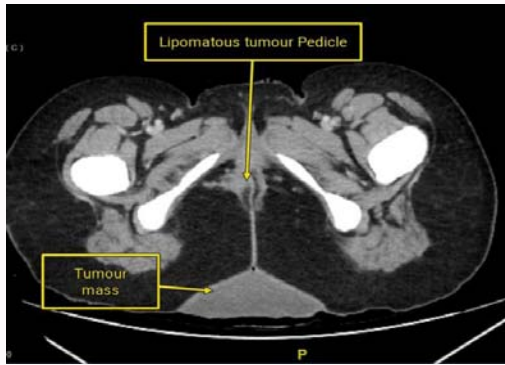
Published Date: 16 Feb 2021

#### Citation:

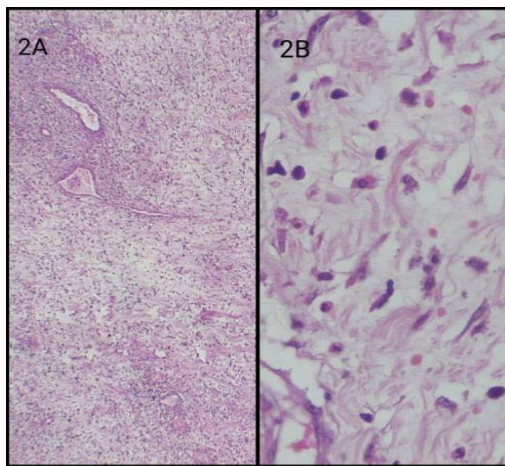
Saxena T, Singh R, Walia M, Guglani B, Ambastha R. Aggressive Angiomyxoma: A Case Report and Review of Literature. *Ann Clin Case Rep.* 2021; 6: 1916.

ISSN: 2474-1655

Copyright © 2021 Tripti Saxena. This is an open access article distributed under the Creative Commons Attribution License, which permits unrestricted use, distribution, and reproduction in any medium, provided the original work is properly cited.



**Figure 1:** Axial contrast enhanced CT image shows mild asymmetric soft tissue thickening in the right labia in the region of tumour pedicle (arrow). The main tumour mass is seen in posterior midline along interguteal cleft showing homogeneous soft tissue attenuation (double arrow).



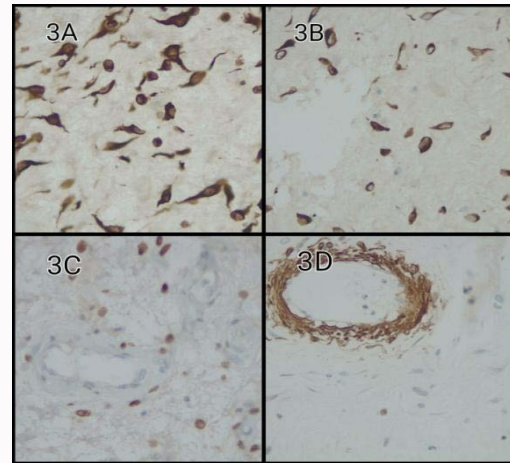
**Figure 2:** Spindle and stellate cells and thin walled curvilinear blood vessels in myxoid background A) Low power field B) High power field.

scan was performed and showed ill-defined soft tissue thickening with mild metabolic activity in labia majora on right side. A wide local excision was performed.

The mass was sent for histopathological examination. On gross examination, large polypoidal lesion of size 16 cm × 11 cm × 9 cm was completely covered by skin. On cut section, mass was gelatinous along with surface ulceration of epithelium with dense inflammatory cells. Stroma and deep tissue showed tumour composed of spindle cells with wavy cytoplasm. Mitotic figures were rare and blood vessels were seen in between spindle cells (Figure 2). Closest margin was 1 mm. On immunohistochemistry, tumor cells were positive for vimentin, desmin, Estrogen Receptor (ER) and negative for SMA, CD34, S100, H Caldesmon, ALK, beta catenin and CK (Figure 3). The KI 67 proliferation index was 2% to 3%. Her case was discussed in multidisciplinary tumor board and it was decided to start the patient on tamoxifen, in view of Estrogen Receptor (ER) positivity.

## Discussion

Majority of patients with Aggressive Angiomyxoma (AA) are usually asymptomatic and present in premenopausal age. AA usually present as an incidental finding or a slow growing mass, which is usually unnoticed or unrecognized for years [8]. They are often



**Figure 3:** A) Showing on immunohistochemistry, tumour cells were positive for Vimentin, B) Desmin, C) Estrogen Receptor and D) SMA.

misdiagnosed as Bartholin's cyst, labial cyst, Gartner duct cyst, abscess, lipoma, fibroepithelial polyp or sarcoma. The tumour usually grows with pushing borders, but in long standing growth, it may infiltrate adjacent organs [9]. On examination, they are yellowish white, with rubbery, soft or gelatinous consistency and areas of congested blood vessels, hemorrhage and fibrosis [2,3]. After collecting pertinent history and performing a thorough clinical examination, radiological (MRI/CT imaging study) examination helps to narrow down the differential diagnosis. MRI and CT are recommended to provide objective data to delineate the extent of the tumor. On CT scan, these tumors have well defined margins with attenuation less than that of the muscle. On MRI, these tumors show extremely high signal intensity on T2 weighted images and a swirled or layered internal architecture in most patients. The high signal intensity on MRI is related to high water content and loose myxoid matrix of AA [10]. MRI is also the preferred mode of investigation to detect recurrence. Our patient didn't undergo any radiological investigations as clinical appearance was like that of a benign polypoidal lesion.

Complete surgical removal with negative margins (>1 cm) is the desired goal. But achieving negative resection margins can sometimes be difficult because of the unencapsulated and infiltrative nature of the tumor. Superficial tumors may be removed by wide local excision, while large and deep seated tumors require more extensive and morbid surgery [8]. Resections with close or positive margin are acceptable when significant surgical morbidity is a concern or fertility preservation a priority. Our patient underwent wide local excision as the traditional treatment of choice. A review of 111 cases of AAM showed no significant difference in disease free interval between positive and negative resection margin groups (40% vs. 50% in 10 years respectively) [11].

On gross pathology, these tumors are usually unencapsulated, poorly circumscribed and blend with surrounding soft tissue. They are often tan pink to tan grey, bulky and have a rubbery consistency with glistening gelatinous surface [12]. Histopathology and immunohistochemistry examinations are the gold standard for diagnosing AA. Microscopically these tumors are sparsely cellular. The tumor matrix is composed of stellate to spindle shaped tumor cells with ill-defined cytoplasmic borders, fibromyxoid stroma, and haphazardly arranged blood vessels. Mitotic figures are rare with no necrosis or cellular atypia [1].

Although there is no specific immunohistochemical marker for AAM, but these tumors generally show diffuse immunopositivity for vimentin, desmin, smooth muscle actin, muscle specific actin and CD34 [13]. They usually display strong estrogen and progesterone receptor positivity. Ki67 labeling index consistently demonstrates low proliferative index (<1% of tumor cells) [14]. The pathogenesis of these tumors is not clear. Chromosomal translocations involving 12q13-15 have been reported in a variety of mesenchymal neoplasms, including lipoma, liposarcoma, leiomyoma and pulmonary hamartoma [15]. The genetic correlation of 12q13-15 chromosomal translocation with AA is further area of research.

Apart from surgical excision other treatment modalities include hormonal therapy, angiographic embolization of the mass, and radiotherapy. As AA occurs in predominantly in premenopausal women and these tumor express estrogen and progesterone, adjuvant hormonal treatment with tamoxifen, raloxifen or gonadotropin releasing hormone analogs (GnRH agonists) may be offered [16]. GnRH agonists have been used to treat recurrent AA, primary treatment of small AA, and as adjuvant therapy. In a recent multicentric retrospective study involving 36 patients Fuca et al showed that surgical local control may be challenging, with a significant rate of local relapse despite complete surgery. Thirteen patients received a first-line systemic treatment with hormone therapy for locally advanced disease, with an overall response rate of 62% and a median progression-free survival of 24.6 months. They concluded that hormone therapy is an active treatment option, with a potential of disease control and of being combined with surgery.

Angiographic embolization has been used to shrink the size of the mass by devascularization the tumor. If used alone there is high risk of recurrence due to development of an alternative blood supply to the tumor. However, embolization may be used for large tumors requiring extensive surgery to facilitate excision by decreasing the tumour size and decrease the amount of operative morbidity especially when preservation of fertility is desired. Radiation therapy alone has little or no role as the tumor has a low proliferative index. Also, there is no evidence that adjuvant or neoadjuvant radiation therapy lowers the recurrence rate. However, it can be considered in patients with no response to embolization or hormonal treatment and in whom mutilating surgery for tumor resection is not warranted [17]. Radiation therapy has been used to treat tumor recurrences with reported tumor free interval of 2 to 3 years [17]. To decrease the risk of local recurrence, use of intraoperative electron beam radiotherapy has also been reported in literature [18]. The prognosis is generally considered good with recurrence rate from the largest case series ranging from 25% to 47% with 85% of those recurring within 5 years of initial surgery [11,13,19]. Hence routine follow up with clinical examination and necessary imaging is warranted.

## Conclusion

Angiomyxoma is a rare slow growing locally infiltrative tumor, predominantly localized to the perineal region in premenopausal women. A high index of suspicion should be maintained by primary care physicians, gynecologists and oncologists, for patients presenting with enlarging vulvar or perineal lesions. Surgical resection with wide or clear margins is the treatment of choice. However, when operative morbidity is anticipated to be high, due to large size of the tumor or infiltration of adjacent vital organs, preoperative embolization and excision with narrow margins can be considered based on the data available. Adjuvant hormonal therapy should be strongly considered

even after resection with clear margins, due to high risk of local recurrence. Patients should be counseled that a high recurrence rate also mandates a close and long-term follow up.

## Statement of Ethics

Written informed consent has been obtained from the patient for publication of this case report and any accompanying images. A copy of the written consent form is available for review from the Editor-in-Chief of this journal.

## Author Contributions

Tripti Saxena and Ruchi Singh have substantial contributions to the design of the work. Meenu Walia, Bhuvnesh Guglani and Rooma Ambastha are accountable for all aspects of the work in ensuring that questions related to the accuracy or integrity of any part of the work are appropriately investigated and resolved.

## References

- Sutton BJ, Laudadio J. Aggressive angiomyxoma. *Arch Pathol Lab Med.* 2012;136(2):217-21.
- Steeper TA, Rosai J. Aggressive angiomyxoma of the female pelvis and perineum. Report of nine cases of a distinctive type of gynecologic soft-tissue neoplasm. *Am J Surg Pathol.* 1983;7(5):463-75.
- Bai HM, Yang JX, Huang HF, Cao DY, Chen J, Yang N, et al. Individualized managing strategies of aggressive angiomyxoma of female genital tract and pelvis. *Eur J Surg Oncol.* 2013;39(10):1101-8.
- Padmavathy L, Rao LI, Lakshmi MD, Sylvester N. Aggressive Angiomyxoma. *Indian Dermatol Online J.* 2014;5(2):151-3.
- Huang CC, Sheu CY, Chen TY, Yang YC. Aggressive angiomyxoma: A small palpable vulvar lesion with a huge mass in the pelvis. *J Low Genit Tract Dis.* 2013;17(1):75-8.
- Siassi RM, Papadopoulos T, Matzel KE. Metastasizing aggressive angiomyxoma. *N Engl J Med.* 1992;341(23):1772.
- Sato K, Ohira M, Shimizu S, Kuroda S, Ide K, Ishiyama K, et al. Aggressive angiomyxoma of the liver: A case report and literature review. *Surg Case Rep.* 2017;3(1):92.
- Haldar K, Martinek IE, Kehoe S. Aggressive angiomyxoma: A case series and literature review. *Eur J Surg Oncol.* 2010;36(4):335-9.
- Junzu G, Bofeng C, Liping W. Aggressive angiomyxoma: An unusual presentation. *Korean J Radiol.* 2012;13(1):90-3.
- Outwater EK, Marchetto BE, Wagner BJ, Siegelman ES. Aggressive angiomyxoma: Findings on CT and MR imaging. *Am J Roentgenol.* 1999;172(2):435-8.
- Chan YM, Hon E, Ngai SW, Ng TY, Wong LC. Aggressive angiomyxoma in females: Is radical resection the only option? *Acta Obstet Gynecol Scand.* 2000;79(3):216-20.
- Mc Cluggage WG. A review and update of morphologically bland vulvovaginal mesenchymal lesions. *Int J Gynecol Pathol.* 2005;24(1):26-38.
- Granter SR, Nucci MR, Fletcher CDM. Aggressive angiomyxoma: Reappraisal of its relationship to angiomyofibroblastoma in a series of 16 cases. *Histopathology.* 1997;30(1):3-10.
- Fetsch JF, Laskin WB, Lefkowitz M, Kindblom LG, Meis-Kindblom JM. Aggressive angiomyxoma: A clinicopathologic study of 29 female patients. *Cancer.* 1996;78(1):79-90.
- Kazmierczak B, Wanschura S, Meyer-Bolte K, Caselitz J, Meister P, Bartnitzke S, et al. Cytogenetic and molecular analysis of an aggressive angiomyxoma. *Am J Pathol.* 1995;147(3):580-5.
- Fine BA, Munoz AK, Litz, CE, Gershenson DM. Primary medical

- management of recurrent aggressive angiomyxoma of the vulva with a gonadotropin-releasing hormone agonist. *Gynecol Oncol.* 2001;81(1):120-2.
17. Suleiman M, Duc C, Ritz S, Bieri S. Pelvic excision of large aggressive angiomyxoma in a woman: Irradiation for recurrent disease. *Int J Gynecol. Cancer.* 2006;16 Suppl 1:356-60.
18. Nyam DC, Pemberton JH. Large aggressive angiomyxoma of the perineum and pelvis: An alternative approach. Report of a case. *Dis Colon Rectum.* 1998;41(4):514-6.
19. White J, Chan YF. Aggressive angiomyxoma of the vulva in an 11-year-old girl. *Pediatr Pathol.* 1994;14(1):27-37.