



A Case Report of Type B Acute Aortic Dissection with Massive Pericardial Effusion

Yuko Kumagai, Soki Kurumisawa, Kei Aizawa and Yoshio Misawa*

Division of Cardiovascular Surgery, Jichi Medical University, Japan

Abstract

A 73-year-old man was transferred to our emergency room with a sudden onset of severe back pain, being under mechanical ventilation because of an intractable pain. His heart rate was regular and blood pressure was 166/96mmHg. A chest computed tomographic scan revealed a massive pericardial effusion associated with type B aortic dissection. His family told us that he had a history of hypothyroidism, and that he had stopped taking medicine several years prior by his judgment. Blood test revealed that thyroid stimulating hormone, free triiodothyronine, and free thyroxine level were 200.93 μ U/ml, 0.88pg/ml, and below 0.1ng/dl, respectively. We strongly suspected that hypothyroidism caused the chronic pericardial effusion without apparent hemodynamic relevance. To get a definite diagnosis of the effusion, we drained the effusion through the left antero-lateral thoracotomy, considering a subsequent pericardial fenestration to the left pleural cavity. Then, we confirmed that the pericardial effusion was caused by chronic hypothyroidism because of a yellowish and transparent fluid. Treatment for hypothyroidism was initiated postoperatively. The patient was doing well, without pericardial effusion and aortic enlargement, under a euthyroid condition 10 months after the surgery. In conclusion, getting his past history help we choose an adequate treatment in a type B dissection case associated with a massive pericardial effusion.

Keywords: Hypothyroidism; Pericardial effusion; Aortic dissection; Thyroid stimulating hormone; Free triiodothyronine; Free thyroxine

Introduction

Pericardial effusion appears followed by cardiac, aortic, pericardial, and other systemic diseases. Acute accumulation can cause cardiac tamponade associated with hemodynamic instability. By contrast, chronic fluid accumulation typically presents with limited clinical symptoms. Herein, we report a case of massive pericardial effusion associated with type B acute aortic dissection.

Case Presentation

A 73-year-old man was transferred to our emergency room with a sudden onset of severe back pain. The patient could not get us his medical history, as he was under mechanical ventilation for the intractable pain. However, his family told us that he had a history of hypothyroidism, but he decided to stop taking medicine several years prior by his own judgment. No other past and family histories were informed. Physical examination revealed normal heart sounds with no murmurs, and normal breathing sounds. His heart rate was regular and blood pressure was 166/96 mmHg. Electrocardiogram revealed a sinus rhythm with a heart rate of 48 beats per minute. A chest computed tomographic scan revealed a massive pericardial effusion and type B aortic dissection with a small amount of pleural effusion (Figure 1). No intimal flap was observed in the ascending aorta and aortic arch. Dissection between the descending aorta and the bilateral common iliac arteries was observed. Echocardiographic findings revealed a massive pericardial effusion without paradoxical movements of the right heart showing cardiac tamponade and valve diseases.

Laboratory tests showed a c-reactive protein of 0.45mg/dl and a white blood cell count of 4,100/ μ g. Other blood tests revealed creatine phosphokinase of 1038U/L, total cholesterol of 187mg/dl, and triglyceride of 117mg/dl. In addition, thyroid stimulating hormone, free triiodothyronine, and free thyroxine level were 200.93 μ U/ml, 0.88pg/ml, and below 0.1ng/dl, respectively. His stable hemodynamic condition with the massive pericardial effusion prevented us from performing a median sternotomy for drainage of the effusion. We chose a small left anterolateral thoracotomy for drainage considering a subsequent pericardial fenestration to the left pleural cavity. The effusion was yellowish and transparent. Then, we confirmed a chronic pericardial effusion induced by a long-

OPEN ACCESS

*Correspondence:

Yoshio Misawa, Division of
Cardiovascular Surgery, Jichi
Medical University, 3311-1 Yakushiji,
Shimotsuke, Tochigi 329-0498, Japan,
Tel: 81-285-58-7368; Fax: 81-285-44-
6271;

E-mail: tcvmisa@jichi.ac.jp

Received Date: 01 Aug 2016

Accepted Date: 22 Aug 2016

Published Date: 30 Aug 2016

Citation:

Kumagai Y, Kurumisawa S, Aizawa K,
Misawa Y. A Case Report of Type B
Acute Aortic Dissection with Massive
Pericardial Effusion. *Ann Clin Case
Rep.* 2016; 1: 1113.

Copyright © 2016 Yoshio Misawa. This
is an open access article distributed
under the Creative Commons Attribution
License, which permits unrestricted
use, distribution, and reproduction in
any medium, provided the original work
is properly cited.

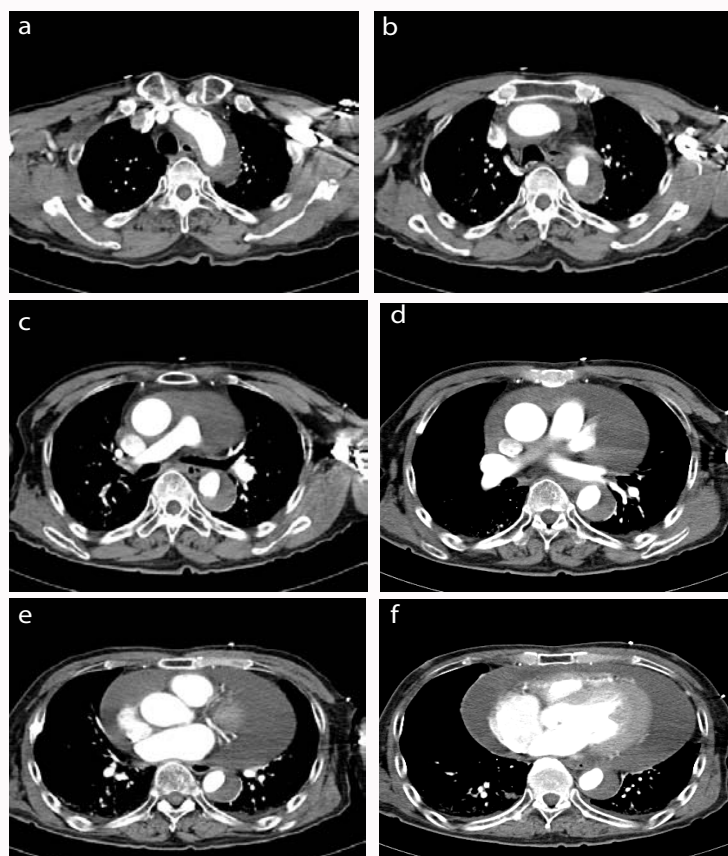


Figure 1: Preoperative chest computed tomographic scan (a-f).

A massive pericardial effusion and type B aortic dissection with a small amount of pleural effusion is shown. No intimal flap is observed in the ascending aorta and aortic arch. The diameter of the dissected aorta is normal.

standing hypothyroidism.

Treatment for systemic hypertension and hypothyroidism was started postoperatively. The aortic dissection remained unchanged in diameter and longitudinal range for two weeks. The patient was transferred to another hospital for continued treatments for both diseases. He was doing well, without pericardial effusion and aortic enlargement, under a euthyroid condition 10 months after the surgery.

Discussion

Heart failure, type A aortic dissection, and pericarditis can produce accumulation of pericardial effusion, which can result in hemodynamic deterioration because of its rapid progress. Systemic diseases such as hypothyroidism, systemic lupus erythematosus, and renal failure are also associated with pericardial effusion [1,2]. Slowly developing pericardial effusion is seldom associated with clinical symptoms. By contrast, rapid accumulation of the effusion can result in cardiac tamponade even in a systemic disease [3,4].

Pericardial effusion is a common clinical manifestation in patients with hypothyroidism, although it is often unrelated to disease severity [5]. Dattilo et al. [5] reported a case of subclinical hypothyroidism with a ubiquitous pericardial effusion. Subclinical hypothyroidism is defined by elevated serum levels of thyroid stimulating hormone, with normal levels of free thyroid hormones. Before surgery, our case had a high level of creatine phosphokinase, but no clinical symptoms, indicating hypothyroidism.

Acute aortic dissection can cause pericardial effusion particularly in type A dissection [6]. Takagi et al. [7] reported a case of hemopericardium in type B aortic dissection, with bloody fluid collected via pericardiocentesis, suggestive of an intramural hemorrhage that was unable to be detected by computed tomography, as previously reported [8]. A chest computed tomographic scan of our case showed type B aortic dissection with massive pericardial effusion. Although his hemodynamic condition was stable, we drained the effusion to provide a definitive cause of the fluid accumulation.

Conclusion

A 73-year-old man with a history of medical treatment for hypothyroidism presented with a sudden onset of severe back pain. A chest computed tomographic scan revealed a massive pericardial effusion and type B aortic dissection. Blood test for thyroid functions with his past medical history and the macroscopic findings of the effusion provided that the pericardial effusion was independent of the type B acute aortic dissection.

Authors' Contributions

Y Kumagai, S Kurumisawa, and K Aizawa contributed to the study conception and design, acquisition, analysis, and interpretation of data, and drafting of the manuscript. Y Misawa critically revised the manuscript and provided final approval for publication.

References

1. Purkait R, Prasad A, Bhadra R, Basu A. Massive pericardial effusion as the only manifestation of primary hypothyroidism. *J Cardiovasc Dis Res.* 2013; 4: 248-250.

2. Chaudhari SS, Wankhedkar KP, Mushiyev S. SLE or hypothyroidism: who can triumph in cardiac tamponade? *BMJ Case Rep.* 2015; 2015.
3. Butala A, Chaudhari S, Sacerdote A. Cardiac tamponade as a presenting manifestation of severe hypothyroidism. *BMJ Case Rep.* 2013; 2013.
4. Ekka M, Ali I, Aggarwal P, Jamshed N. Cardiac tamponade as initial presenting feature of primary hypothyroidism in the ED. *Am J Emerg Med.* 2014; 32: 683.
5. Dattilo G, Crosca S, Tavella S, Marte F, Patanè S. Pericardial effusion associated with subclinical hypothyroidism. *Int J Cardiol.* 2011; 153: e47-50.
6. Cruz I, Styart B, Caldeira D, Morgado G, Gomes AC, Almeida AR, et al. Controlled pericardiocentesis in patients with cardiac tamponade complicating aortic dissection: experience of a center without cardiothoracic surgery. *Eur Heart J Acute Cardiovasc Care.* 2015; 4: 124-128.
7. Takagi H, Manabe H, Sekino S, Kato T, Matsuno Y, Umemoto T. Paradoxical hemopericardium in type B acute aortic dissection. *J Thorac Cardiovasc Surg.* 2005; 129: 939-940.
8. Attenhofer CH, Vogt PR, von Segesser LK, Dirsch OR, Ritter M, Jenni R. Leaking giant aneurysm of the aortic root due to cystic medial necrosis with pericardial tamponade mimicking type-A aortic dissection. *Thorac Cardiovasc Surg.* 1996; 44: 103-104.