



A Case of Sealed Off Gastric Perforation with Epigastric Collection due to Ingested Fish Bone

Mahadeo Garale, Varsha Kulkarni and Prashant Umare*

Department of Surgery, Seth G.S. Medical College & KEM Hospital, Mumbai, India

Abstract

Introduction: Gastric perforation secondary to ingested foreign bodies is rare, with fish bones being a common cause due to their sharp and linear nature. Such perforations may occasionally seal off, leading to localized intra-abdominal collections and atypical clinical presentations.

Case Presentation: A 54/M patient presented with mild epigastric pain and localized tenderness without features of generalized peritonitis. Contrast-enhanced computed tomography of the abdomen revealed a linear hyperdense foreign body below left lobe of liver and lesser curvature of the stomach with a localized epigastric collection, suggestive of a sealed-off gastric perforation. Exploratory laparotomy confirmed a sealed perforation with surrounding inflammatory adhesions and an epigastric pus collection which was aspirated and peritoneal lavage was given. The fish bone was retrieved. Postoperatively, the patient was managed with broad-spectrum antibiotics and supportive care. Recovery was uneventful, and the patient was discharged in stable condition.

Discussion: This case emphasizes the importance of maintaining a high index of suspicion for foreign body-related perforation in patients presenting with localized abdominal pain and highlights the role of timely imaging and surgical management in preventing morbidity.

Conclusion: Sealed-off gastric perforation due to fish bone ingestion is an uncommon clinical entity and may present with localized symptoms. Early imaging, especially computed tomography, is crucial for diagnosis. Prompt surgical intervention ensures favorable outcomes and prevents serious complications

Keywords: Sealed-off gastric perforation; Fish bone; Epigastric pus

OPEN ACCESS

*Correspondence:

Prashant Umare, Department of Surgery, Seth G.S. Medical College, Mumbai, India, Tel: 8793792434

Received Date: 16 Jun 2026

Accepted Date: 24 Jun 2026

Published Date: 25 Jun 2026

Citation:

Mahadeo G, Varsha K, Prashant U. A Case of Sealed Off Gastric Perforation with Epigastric Collection due to Ingested Fish Bone. *Ann Clin Case Rep.* 2026; 11: 2839. ISSN: 2474-1655.

Copyright © 2026 Prashant Umare.

This is an open access article distributed under the Creative Commons Attribution License, which permits unrestricted use, distribution, and reproduction in any medium, provided the original work is properly cited.

Introduction

Unintentional ingestion of fish bones is a common but frequently unrecognized occurrence at the emergency rooms.

Gastrointestinal perforation may occur in 1% of cases and lead to acute abdomen. The clinical manifestations are mainly determined by the location of the perforation, imaging examinations and surgery are often needed for the diagnosis [1].

The non-specific spectrum of presentations and unawareness of episode of ingestion make the diagnosis of this entity a clinical challenge. This entity is often forgotten when establishing a differential diagnosis of acute abdominal pain and may mimic other frequent abdominal emergencies, such as ruptured gastric ulcer, appendicitis or diverticulitis.

In the present article we report a case of a patient came to emergency with pain in epigastric region mimicking pancreatitis and who after performing CT scan showed epigastric collection resulting due to fish bone infection.

Patient Information

Demographics: 54-year-old male.

Main concerns: Mild epigastric pain for 2 weeks.

Medical history: No significant comorbidities.

Clinical Findings

On admission, patient presented with mild epigastric pain. He denied any nausea vomiting. No history of bladder and bowel complaints. No history of hematemesis or Malena. No-comorbidities.

Table 1:

Day	Event
14 days	Complaint of mild pain in epigastrium
Day 0	Admission to emergency department with epigastric pain. USG done suggestive of epigastric collection with query pancreatitis. CT scan performed - diagnosed fish bone with epigastric collection. Normal pancreas. Initiation of broad-spectrum antibiotics.
Day 1	Emergency exploratory laparotomy done. Epigastric pus aspirated. Fish bone removed.
POD 2	Started on liquid diet tolerated well, stepped up to soft diet. Drain output 20ml/day. Passing stool flatus.
POD 5	Drain removed
POD 6	Discharge

Passing Stool and Flatus. Denies addiction. No history of any abdominal surgery.

Examination revealed - He was afebrile, hemodynamically stable, mild epigastric tenderness with no obvious lump on palpation and no evidence of guarding and rigidity. Digital examination was normal and negative for occult blood.

Timeline

See table 1.

Diagnostic Assessment

Laboratory tests: Marked leukocytosis (21,400/mm³); HB 13.2 mg/dl, normal serum creatinine (1.8 mg/dL); normal electrolytes.

Imaging: Chest and abdomen x-ray- normal.

USG: Epigastric collection 550 cc.

Contrast-Enhanced CT Abdo- revealed a hyperdense linear image with 5 cm in between left lobe of liver and lesser momentum, with epigastric collection of 600 cc. Inflammatory thickening of gastric wall (Figures 1 and 2).

Microbiology: Culture of aspirated pus yielded monomicrobial

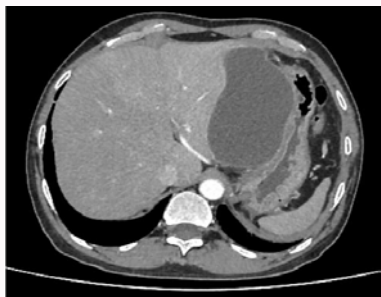


Figure 1:

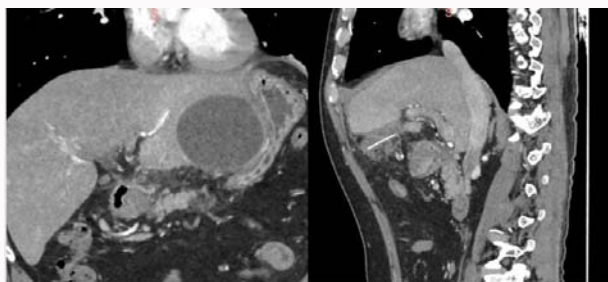


Figure 2:

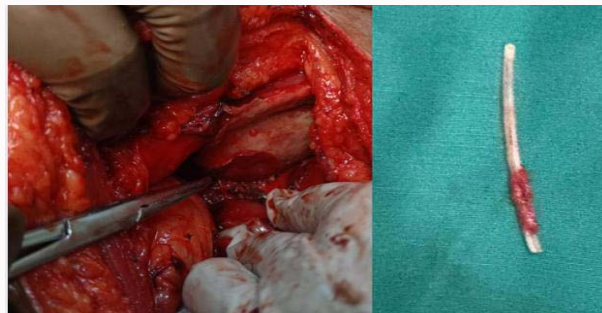


Figure 3:

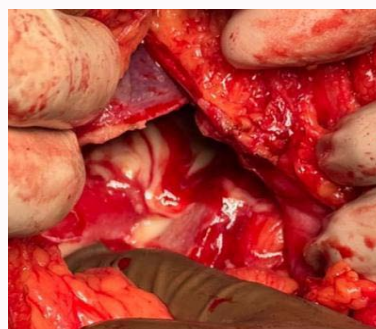

Figure 4:

growth of *Escherichia coli*.

Surgical Intervention

Emergency exploratory laparotomy done -Localized perigastric abscess with pus (600 ml)- aspirated and warm saline lavage given. Fish Bone embedded between lesser curvature of stomach and left lobe of liver was removed. Inflamed gastric wall and thickened momentum with sealed off gastric perforation was seen. No visible free perforation noted. Lesser sac opened- no collection seen. Air leak test was performed- negative. Rest of bowel traced found to be normal. With these findings, the foreign body was removed, a culture obtained and a drain was placed without complications (Figures 3 and 4). Ingested foreign body causing a stomach perforation and abscess was the final diagnosis.

Follow-up and Outcomes

The patient extubated and shifted to general ward. Daily drain output and vitals monitored. POD 2 started on liquid diet, tolerated well, stepped up to soft diet. Completed course of antibiotics. POD-5 drain output was low and serous, it was removed and POD 6- patient discharges with normal WBC counts and without any post op complications.

Discussion

Fish bone may account for 84% of the foreign bodies ingested accidentally, majority are eliminated from the gastrointestinal system without any Symptoms [2].

Fish bone perforation of the GIT can be a challenging diagnosis due to its broad spectrum of presentation, as it will be depended on the location and size of perforation. Symptoms vary from abdominal pain to vomitus and fever and since patient often do not recall ingesting foreign body, it makes the clinical diagnosis more challenging [6].

Multidetector CT scan is the method of choice to evaluate patient with acute abdominal pain and to detect foreign bodies. Findings at site of perforation includes: mucosal thickening of the bowel, intestinal obstruction, perigastric fat stranding and at time abscess formation like in our case [3,4].

Gastroscopy can be both diagnostic and therapeutic if done during initial period of perforation with the foreign body visible intraluminally. Surgical intervention becomes necessary when the foreign body becomes extraluminal like in our case. Exploratory laparotomy followed by retrieval of fish bones with drainage of the abscess cavity is required like we did in our case [5].

Our case is unique in which initially pain and USG findings mimicking pancreatitis with turnout to be sealed off gastric perforation with epigastric collection due to fish bone ingestion, which the patient not able to recall when he last eats fish.

Conclusion

Fish bone perforation is not a common cause of gastrointestinal perforation. However, it can cause diagnostic challenges. History of fish ingestion should be asked in case of diagnostic suspicion. CT scan is a sensitive investigation and aids in definitive preoperative diagnosis leading to a less morbid surgical treatment for the patient. Delay in diagnosis and treatment can be associated with significant morbidity and mortality.

References

1. Song J, Yang W, Zhu Y, Fang Y, Qiu J, Qiu J, et al. Ingested a fish bone-induced ileal perforation: a case report. *Medicine (Baltim.)* 2020;99(15):19508.
2. Venkatesh SH, Venkatanarasimha Karaddi NK. CT findings of accidental fish bone ingestion and its complications. *Diagn Interv Radiol.* 2016;22(2):156-60.
3. Pulat H, Karakose O, Benzin MF, Benzin S, Cetin R. Small bowel perforation due to fish bone: a case report. *Turk J Emerg Med.* 2016;15(3):136-8.
4. Sibanda T, Pakkiri P, Ndlovu A. Fish bone perforation mimicking colon cancer: a case report. *SA J Radiol.* 2020;24(1):1885.
5. Sharma R, Padhy BP, Kumar S, Hareesh M, Suchithra GL. Gastric perforation due to fish bone ingestion presenting as gastric outlet obstruction: a case report. *Int Surg J.* 2018;5(12):4081-84.
6. McCansie DE, Kurchin A, Hinshaw JR. Gastrointestinal foreign bodies. *Am J Surg.* 1981;142:335-7.