



A Case of a Cervical Cancer Patient with Elevated CEA Caused by Hashimoto's Thyroiditis

Lei Gao^{1*}, Gong Li¹, Xiaojuan Li², Cheng Xiao² and Shucong Zhang²

¹Department of Radiotherapy, Guangdong Provincial Hospital of Chinese Medicine, China

²Department of Medical Oncology, Second Clinical College of Guangzhou University of Chinese Medicine, China

Abstract

Carcinoembryonic Antigen (CEA) is a broad-spectrum tumor marker that can be expressed in a variety of malignancies, it has relatively high sensitivity, and can be used as an index for evaluation of therapeutic effect. Its level has been shown to be associated with tumor burden with colorectal cancer. However, it is also elevated to a significant degree in non-malignant conditions. The purpose of this case report is to describe Hashimoto's thyroiditis causing a marked elevation of CEA levels and to review other benign causes of elevated CEA.

A 77-year-old woman was diagnosed with cervical cancer, and received radical chemoradiotherapy. All data showed that the treatment was effective, but repeated serum CEA levels were found to have an upward trend, so we initially thought that was the result of tumor recurrence or other malignancies. Then, we conducted further assessment, the SCC-Ag level was at a low state, it was an important indicator of the effectiveness of cervical cancer treatment. And the rest of other tumor markers, which including serum AFP, CA12-5, CA19-9, CA15-3, were all within the normal limit. On the other hand, follow-up imaging examinations, including PET, CT and MRI, showed that treatment was effective, and there were no primary recurrence or metastasis. It is noteworthy that all imaging studies suggest the sign of the thyroid gland was changed, but the patient did not have overt hyperthyroid or hypothyroid features. With our further evaluation, serum thyroid peroxidase antibody (ATPO), and thyroglobulin antibody titers (ATG) were markedly elevated. On thyroid ultrasonography revealed the increase of the volume of thyroid gland, and multiple isoechoic nodules, the patient was diagnosed with Hashimoto thyroiditis.

OPEN ACCESS

*Correspondence:

Lei Gao, Radiotherapy Department,
Guangdong Provincial Hospital of
Chinese Medicine, Guangzhou 510120,
China,

E-mail: gzgaolei@126.com

Received Date: 23 Jun 2017

Accepted Date: 04 Oct 2017

Published Date: 06 Oct 2017

Citation:

Gao L, Li G, Li X, Xiao C, Zhang S. A
Case of a Cervical Cancer Patient with
Elevated CEA Caused by Hashimoto's
Thyroiditis. *Ann Clin Case Rep.* 2017;
2: 1438.

ISSN: 2474-1655

Copyright © 2017 Lei Gao. This is an
open access article distributed under
the Creative Commons Attribution
License, which permits unrestricted
use, distribution, and reproduction in
any medium, provided the original work
is properly cited.

Keywords: Carcinoembryonic antigen; Hashimoto's thyroiditis; Cervical Cancer

Introduction

Carcinoembryonic antigen (CEA) is an oncofetal glycoprotein, what normally expressed by mucosal cells. It is over expressed in patients with adenocarcinoma like endometrial cancer colorectal cancer, etc. And it is elevated to significant degree in variety of other malignancies, such as breast, lung, stomach, and pancreas. And CEA is also expressed on the cell surface in certain inflammatory conditions, including inflammatory bowel disease, peptic ulcer disease and hypothyroidism.

CEA is widely used as a screening tool for cancer. However, there are a number of non-malignant etiologies of elevated CEA level. Therefore, clinicians need to be aware of its rare associations so as to avoid unnecessary investigations without missing the malignant disorders. On the other hand, CEA serum levels have been reported elevated in patients with autoimmune thyroid disease [1]. We report the case of a patient with an elevated CEA level who underwent investigations for cervical cancer, which was later found to be related to Hashimoto's thyroiditis.

Case Presentation

A 77-year-old female with past medical history of hypertension, diabetes mellitus (DM), nephrolithiasis and fatty livers. On August 18, 2016, she was diagnosed as cervical cancer; pathological result was FIGO stage II b, squamous-cell carcinoma. Elevated serum CEA was raised at 18.57 µg/L (normal range 0~5 µg/L), and squamous cell carcinoma antigen (SCC-Ag) was 1.6 mg/ml (normal range 1.5 mg/ml), which associated with squamous cell carcinoma (HCC) and as an important indicator of the effectiveness or prognosis of cervical cancer treatment. The rest of other tumor markers, which including serum AFP, CA12-5, CA19-9, CA15-3, were all within the normal limit. At the same time, a MRI scan showed that the posterior wall of cervix was occupied,

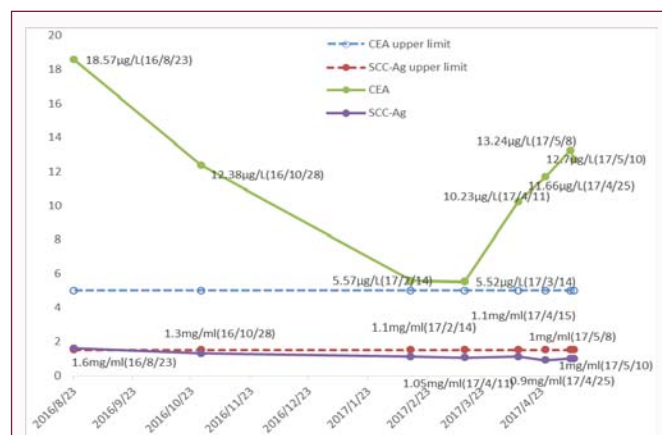


Figure 1: Graph shows the serum CEA level and SCC-Ag level at different timelines.

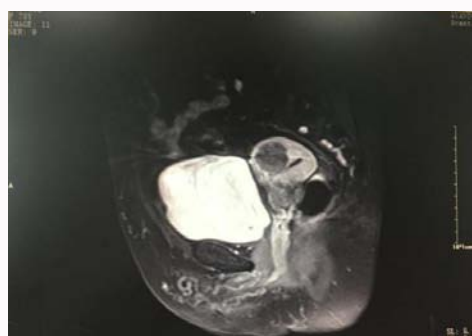


Figure 2: MRI image of the tumor, On August, 2016.

which accord with cervical cancer, and myoma of uterus? Therefore she received radical radiotherapy. From September 19 to October 28, she had undergone external radiotherapy (ERBT), that a total does of 45Gy/25Fx for five weeks. To investigate the short-term clinical outcomes, on October 28, she was evaluated. Repeat serum CEA was 12.38µg/L, which was lower than before. And compared previous imaging results, a positron emission tomography (PET) scan showed that treatment is effectively, because that the focus of tumor was limited, and negative for hypermetabolic lesions, besides, a sign of the thyroid gland was abnormal, considering nodular goiter. However, as she did not have overt hyperthyroid or hypothyroid features, treatment was not started. Subsequently she received a total four times brachy therapy with dose of 6Gy/Fx, and plus three cycles concurrent chemotherapy with oral capecitabine 1.0g bid, from day1 to day4, as adjuvant therapy. Repeat serum CEA was noted to decrease to 5.57µg/L, SCC-Ag was 1.3mg/ml, and MRI findings were roughly the same as PET. Five months after radical treatment, the patient tumor markers were demonstrated normal, and SCC-Ag level was 1.1µg/L, except for CEA that was increased to 10.23µg/L.

Initially, we considered whether there was recurrence or metastasis. But follow-up CT scans were no evidence of primary recurrence or metastasis, at the subsequent review, the CEA level continued to rising, range from 11.6µg/L to 13.24µg/L, the level of other tumor makers were within normal range, and all imaging studies did not reveal any evidence of primary recurrence, metastasis or other malignancy. There was one noteworthy, that all imaging results suggest the sign of the thyroid gland had changed, so we conducted further evaluation. On physical examination, we found that the size of thyroid was observed to be increased and extended

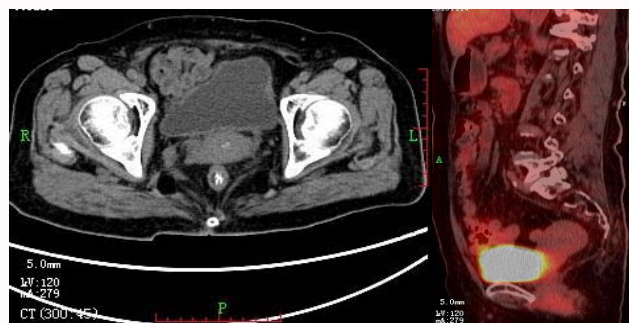


Figure 3: CT and PET image of the tumor after finished ERBT.

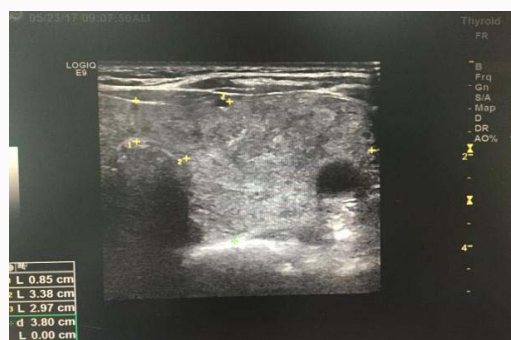

Figure 4: Ultrasound image of thyroid, on May, 2017.

to sternocleidomastoid region; there were non-tender mass and no prominent lymph nodes in the neck. Serum TSH was 0.441mIU/L (normal level 0.5 to 4.5mIU/L), free T3 and free T4 were normal, and serum thyroid peroxidase antibody (>1,300IU/ml; normal range<60IU/ml; strongly positive), thyroglobulin antibody titers (>500 IU/ml, normal range<60IU/ml) were markedly elevated. On thyroid ultrasonography revealed the increase of the volume of thyroid gland, and multiple isoechoic nodules, range from 4mm to 36mm. In the left lobe of the thyroid, the largest of which measured 34 mm × 36mm × 24mm, and the right lobe of thyroid gland was measured a 14 mm × 14 mm × 9 mm-sized isohypoechoic nodule. There were no prominent lymph nodes in the neck. All data was consistent with Hashimoto's thyroiditis (Figure 1 -4).

Discussion

In this report, we describe a case of a cancer patient with evaluated level of CEA caused by Hashimoto's thyroiditis. Although the exact mechanism causing high serum CEA levels in patients with Hashimoto's thyroiditis remains unknown and would need further studies to elucidate the pathophysiology. To our knowledge and literature, this is not the first case report linking Hashimoto's thyroiditis with an elevated CEA level [2]. Keiji Inia et al. [1] reported a case of myxedema coma caused by isolated thyrotropin stimulating hormone deficiency and Hashimoto's thyroiditis, that observed possesses transient elevated levels of CEA, which rapidly decreased after the hypothyroidism was treated.

The increase of CEA level could be caused by various factors, such as, the presence of immunologically cross-reacting CEA-like substances, or increased CEA synthesis, decrease CEA degradation. In the current studies, these have shown hypothyroidism as potential cause of the elevated CEA level, for example, Tukamu et al. [3] observed that the mean CEA concentration was significantly higher in hypothyroid patients than in normal and hyperthyroid patients, which

means when patients are suffering from hypothyroidism, caution should be taken when reading the tumor marker concentration. In another study, found that increased CEA is not coming from the thyroid itself. A significantly high frequency of positive CEA was observed in hypothyroid patients with Hashimoto's disease, these findings indicate that elevated CEA levels in hypothyroid patients do not necessarily indicate malignancy [4].

Conclusion

Our case highlights the importance of awareness of the associations of elevated tumor markers with not just malignant conditions but also benign ones. The evaluation of prognosis of the tumor should be cautious with the interpretation of CEA. Whether to check the thyroid-related biochemical indexes, to exclude the relationship with Hashimoto's thyroiditis, when cancer patients in the process of examination found CEA level continuous increased. Or patients with elevated CEA should also be evaluated for underlying thyroid disorders that may be sub-clinical.

References

1. Keiji Iida, Yasuhisa Hino, Takeshi Ohara, Kazuo Chihara. A case of myxedema coma caused by isolated thyrotropin stimulating hormone deficiency and Hashimoto's thyroiditis. *Endocr J.* 2011; 58: 143-148.
2. Asad Ur Rahman F, Saif M W. Elevated Level of Serum Carcinoembryonic Antigen (CEA) and Search for a Malignancy: A Case Report. *Cureus.* 2016; 8: e648.
3. Hashimoto T, Matsubara F. Changes in the Tumor Marker Concentration in Female Patients with Hyper-, Eu-, and Hypothyroidism. *Endocrinol Jpn.* 1989; 36: 873-879.
4. Amino N, Kuro R, Yabu Y, Takai SI, Kawashima M, Morimoto S, et al. Elevated Levels of Circulating Carcinoembryonic Antigen in Hypothyroidism. *Journal of Clinical Endocrinology and Metabolism.* 1981; 52: 457-462.