



Epithelioid Sarcoma Presenting as Pulmonary Cysts Detected by Spontaneous Pneumothorax

Tomoyuki Miyazawa¹, Hideki Marushima¹, Masahiro Hoshikawa¹, Koji Kojima¹, Masayuki Takagi² and Hisashi Saji^{1*}

¹Department of Chest Surgery, St. Marianna University School of Medicine, Japan

²Department of Pathology, St. Marianna University School of Medicine, Japan

Abstract

A 42-year-old woman was referred to our hospital with chest pain. Chest CT showed left pneumothorax and bilateral pulmonary cysts. We performed lung cyst resection using video assisted thoroscopic surgery. Pathological diagnosis revealed lung metastasis of Epithelioid Sarcoma (ES). During the four months following the development of left pneumothorax, right lung cysts gradually increased. We performed a right lower lobectomy and a further pathological diagnosis of lung metastasis of ES was made. Five months after the right lower lobectomy, the patient felt a swelling in her left calf. A soft tissue tumor was present in the soleus muscle. We took a pathological biopsy from the soft tissue tumor, and its pathological diagnosis was ES. Twenty one months following the development of pneumothorax, the patient died due to disease progression.

Introduction

Epithelioid Sarcoma (ES) is a rare mesenchymal tumor that occurs more often in the dermal or subcutaneous area of the distal extremities of young adults, typically in men. ES has a poor prognosis owing to its aggressiveness; it frequently recurs locally and can undergo metastasis, usually to the lymph nodes, soft tissues, bones, lungs, or brain [1]. Spontaneous pneumothorax with cystic lung metastasis has been reported previously, although to our knowledge just six patients have been reported in the literature [1-6] (Table 1). We describe a rare case of ES diagnosed with the development of pneumothorax. A 42-year-old woman was admitted to St. Marianna University Hospital due to a left pneumothorax. Chest CT revealed bilateral pulmonary cysts (Figure 1). She underwent left thoracotomy and received a pathological diagnosis of metastasis of ES.

Case Presentation

The patient was a 42-year-old woman who had undergone total hysterectomy salpingo oophorectomy because of stage IIA cervical cancer two years previously. She was admitted complaining of chest pain. Chest CT revealed left pneumothorax and bilateral pulmonary cysts. We initially considered pneumothorax to be caused by the rupture of lung metastasis from cervical cancer, and performed thoroscopic lung cyst resection. Histopathological examination revealed the tumor had formed bullae and consisted of circular epithelioid cells. The specimen was immunohistochemical positive for cytokeratin, and negative for Integrase Interactor 1 (INI-1) (Figure 2). The pathological diagnosis was lung metastasis of ES. Four months following the development of pneumothorax, right lung cysts showed an increasing trend, so we performed right lower lung lobectomy, and a further pathological diagnosis of lung metastasis of ES was made. Five months after the right lower lung lobectomy, the patient felt swelling in her left calf. We performed MRI and PET scans. Soft tissue tumor was present in the soleus muscle, with a maximum standardized uptake value of 28.2. A biopsy of the soft tissue tumor resulted in a further pathological diagnosis of ES. She received three cycles of chemotherapy with Doxorubicin (DXR). However, progression continued resulting in enlarged inguinal lymph nodes and brain lesions. The patient then received three cycles of docetaxel and gemcitabine therapy, and 1 cycle of Ecteinascidin 743, and showed a poor response to both treatments. Twenty one months following development of pneumothorax, the patient died owing to disease progression.

Discussion

ES is rare soft tissue sarcoma with a known high propensity for local recurrence and distant metastases. Local recurrence occurs in 77% patients. Metastases have been reported in a range 30%

OPEN ACCESS

*Correspondence:

Hisashi Saji, Department of Chest Surgery, St. Marianna University School of Medicine, 2-16-1 Sugao, Miyamae-ku, Kawasaki, Kanagawa 216-8511, Japan, Tel: +81-44-977-8111; Fax: +81-44-976-5792;

E-mail: hsaji@marianna-u.ac.jp

Received Date: 02 May 2019

Accepted Date: 28 Jun 2019

Published Date: 03 Jul 2019

Citation:

Miyazawa T, Marushima H, Hoshikawa M, Kojima K, Takagi M, Saji H. Epithelioid Sarcoma Presenting as Pulmonary Cysts Detected by Spontaneous Pneumothorax. *Ann Clin Case Rep.* 2019; 4: 1683.

ISSN: 2474-1655

Copyright © 2019 Hisashi Saji. This is an open access article distributed under the Creative Commons Attribution License, which permits unrestricted use, distribution, and reproduction in any medium, provided the original work is properly cited.

Table 1: Characteristics, treatment, and outcome of reported epithelioid sarcoma cases with spontaneous pneumothorax.

Authors	Journal	Age/ Sex	Primary Site	Pneumothorax Site	Features of lung cyst	Treatment	Prognosis
Hasegawa et al. [2]	CHEST, 1999	20/F	Right forearm	Bilateral	Cysts	Op	Alive at 7 years
Chan et al. [3]	Ann Thorac Surg, 2003	42/M	Thigh	Bilateral	Cysts	Op Chemotherapy	Alive
Kikuchi et al. [4]	Respirology, 2006	39/F	Right hand	Bilateral	Cysts and nodules	Op Chemotherapy (carboplatin+paclitaxel and ifosfamide +doxorubicin)	Died 38 month after Pneumothorax
Barnoud et al. [6]	Ann Pathol, 2010	24/M	Right foot	Bilateral	Cysts	Op Chemotherapy (Adriamycin+ifosfamide)	Died 38 month after Pneumothorax
Liu et al. [5]	EJD, 2011	30/M	Right forefinger	Right	Not	Untreated	Not Given
So-Yean Jeon et al. [1]	KJIM, 2016	42/M	Perianal area	Right	Cysts and nodules	Op Chemotherapy (ifosfamide+doxorubicin+dacarbazine)	Died 3 month after Pneumothorax
This case	42/F	Left foot	Left	Cysts	Op Chemotherapy (doxorubicin and docetaxel+gemcitabine and Ecteinascidin 743)	Died 21 month after pneumothorax	Died 21 month after Pneumothorax

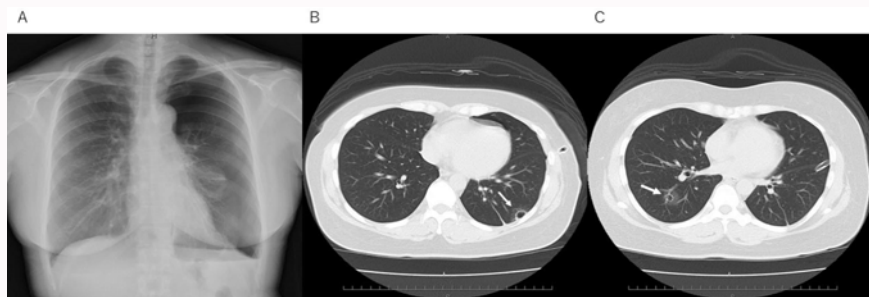


Figure 1: A) Chest radiograph showing a pneumothorax on the left lung. Axial chest computed tomography scan of lower lobes showing two well-defined lung cysts present. The cyst walls are smooth and thin. B) The left one is in a sub pleural location (black arrow). C) The right one is located centrally (white arrow).

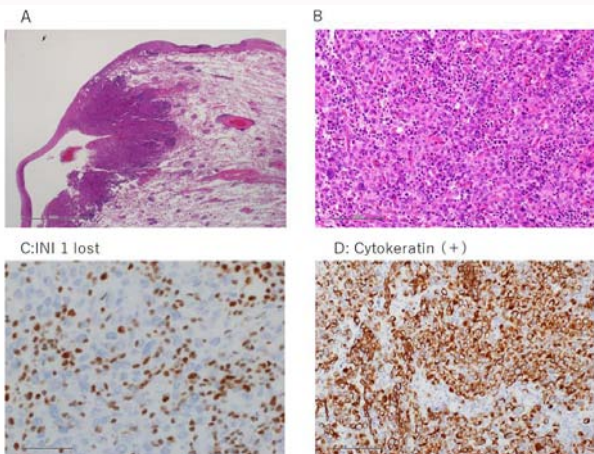


Figure 2: Histopathologic examination revealed A) A malignant cells accompany cyst present in subpleural. B) Epithelial-like compounds round cells in the tumor (hematoxylin-eosin). C) Tumor cells were negative for INI-1. D) Tumor cells were positive for cytokeratin.

to 58% in patients, mainly to lymph nodes, bones, lungs, pleura, and the brain [5]. Pulmonary metastases of soft tissue sarcomas commonly manifest as solid nodules, but a few cases of cystic pulmonary metastases have been described. Pneumothorax may have also been caused by distension of alveoli through the ball-valve effect, permitting passage of air along the interlobular septa to the pleura, where cysts may have formed and eventually ruptured [2]. To our knowledge only six patients who developed pneumothorax caused by

lung metastasis of ES have been reported in the literature [1-5]. Of these six patients with ES, our patient represents the first reported case of a diagnosis made following the development of spontaneous pneumothorax. The clinical presentation of ES is indolent, so this case was diagnosed by lung lesions prior to the detection of the left calf lesion.

References

1. Jeon SY, Yhim HY, Lee NR. Epithelioid sarcoma with spontaneous pneumothorax and massive pleural effusion. *Korean J Intern Med.* 2016;31(1):191-3.
2. Hasegawa S, Inui K, Kamakari K, Kotoura Y, Suzuki K, Fukumoto M. Pulmonary cysts as the sole metastatic manifestation of soft tissue sarcoma: case report and consideration of the pathogenesis. *Chest.* 1999;116(1):263-5.
3. Chan DP, Griffith JF, Lee TW, Chow LT, Yim AP. Cystic pulmonary metastases from epithelioid cell sarcoma. *Ann Thorac Surg.* 2003;75(5):1652-4.
4. Kikuchi E, Kinoshita I, Yamazaki K, Itoh T, Shimizu T, Shimizu H, et al. Epithelioid sarcoma presenting as pulmonary cysts with cancer antigen 125 expression. *Respirology.* 2006;11(6):826-9.
5. Liu Y, Ma X, Zang D, Zhou C, Zhang J. Epithelioid sarcoma with osteoporosis and pneumothorax. *Eur J Dermatol.* 2011;21(2):296-7.
6. Barnoud R, Collardeau-Frachon S, de la Roche E, Vasiljevic A, Thomson V, Ranchère D, et al. Lung metastases of epithelioid sarcoma revealed by bilateral spontaneous pneumothorax: a pathological diagnosis. *Ann Pathol.* 2010;30(2):139-42.