



## Masson's Haemangioma - An Unusual Neck Swelling

Mohit Malhotra<sup>1</sup>, Chisel Bhatia<sup>1</sup>, Uttamjot Kaur<sup>2</sup>, Sushma Bhardwaj<sup>1</sup> and Simrandeep Singh<sup>1\*</sup>

<sup>1</sup>Department of Surgery, Government Medical College and Hospital, India

<sup>2</sup>Department of Pathology, Government Medical College and Hospital, India

### Abstract

Masson's Haemangioma (Intravascular Papillary Endothelial Hyperplasia) is a rare vascular tumor that is often misdiagnosed. We report the case of a 56-year-old male with a left supraclavicular swelling that was diagnosed as Masson's haemangioma on histopathological examination.

**Keywords:** Intravascular papillary endothelial hyperplasia (IPEH); Masson's haemangioma; OPD

### Introduction

Masson's haemangioma is a rare, benign vascular lesion that accounts for approximately 2% of all vascular tumors of the skin and subcutaneous tissue. It was first described by Pierre Mason in 1923 in an ulcerated haemorrhoidal vein, but has also been reported to occur at various sites such as the cranium, thyroid, breast, neck, external jugular vein, tongue, oral cavity and rarely urethra [1]. Due to its histological features of papillary formation, anastomosing vascular channels and plump endothelial cells, it was earlier thought to be a variant of angiosarcoma; however nowadays, it is considered a reactive vascular proliferation to traumatic vascular stasis [2]. Due to its common presentation as a subcutaneous soft tissue lump, the diagnosis is usually not possible without histopathological examination.

### Case Presentation

A 56-year-old, male patient came to our Outpatient Department (OPD) with the complaint of a left supraclavicular swelling for one year. On examination, the swelling measured 2 cm × 2 cm, and was mobile, non-tender, firm, and with no associated skin changes. A clinical diagnosis of lymphadenopathy was made and Fine Needle Aspiration Cytology (FNAC) asked for. FNAC reported the lesion as a benign lipomatous lesion (Figure 1) and the patient underwent excision of the lesion under local anaesthesia on OPD basis. During excision, the lump was found to be highly vascular, and multiple small vessels were seen traversing through it. The lesion was excised and sent for histopathological examination.

Histopathological examination revealed proliferation of endothelial cells within fibrous tissue, dilated blood vessels that contained thrombi, as well as fibrin deposition. There was no cellular atypia or mitotic figures, and a diagnosis of Masson's haemangioma was made (Figures 2 and 3). On receiving the histopathology report, the patient was questioned about any past history of trauma, and he revealed that he had been involved in a road side accident two years ago in which he had sustained trauma to the neck, left upper limb and a fracture of the shaft of left humerus that were managed conservatively.

### Discussion

Masson's haemangioma is a benign vascular tumor that is always almost intravascular, and clearly distinct from an organizing thrombus. It is known by various eponyms such as Masson's intravascular hemangioendothelioma, Intravascular Papillary Endothelial Hyperplasia (IPEH) or reactive endothelial hyperplasia [2]. It was first described in 1923 by Pierre Masson within the lumen of inflamed hemorrhoidal veins in a 68-year-old male and he believed the lesion caused obliteration of the vessel lumen leading to subsequent degeneration and necrosis. Masson's observations were modified by Henschen, who believed that the lesion was a reactive process rather than a neoplasm. This was confirmed by the findings reported by Kauffman and Stout [3] that the endothelial layer of the lesion was composed of normal endothelial cells and that the endothelial proliferation was of benign papillae pattern and the cells showed no atypia. Nowadays it is considered to be a reactive vascular proliferation following traumatic vascular stasis [4].

### OPEN ACCESS

#### \*Correspondence:

Simrandeep Singh, Department of Surgery, Government Medical College and Hospital, Sector 32, Chandigarh, India,

E-mail: [dr\\_simrandeep@yahoo.co.in](mailto:dr_simrandeep@yahoo.co.in)

Received Date: 09 Apr 2019

Accepted Date: 06 May 2019

Published Date: 15 May 2019

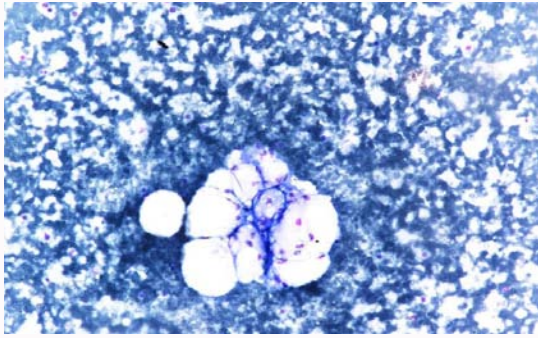
#### Citation:

Malhotra M, Bhatia C, Kaur U, Bhardwaj S, Singh S. Masson's Haemangioma - An Unusual Neck Swelling. *Ann Clin Case Rep.* 2019; 4: 1654.

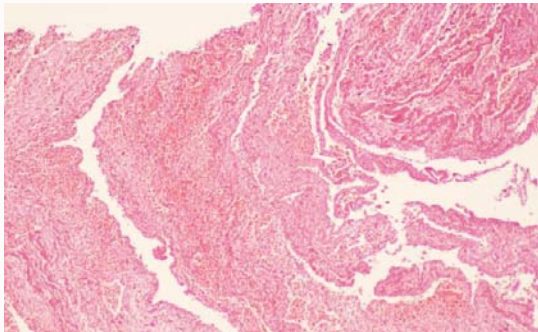
ISSN: 2474-1655

Copyright © 2019 Simrandeep

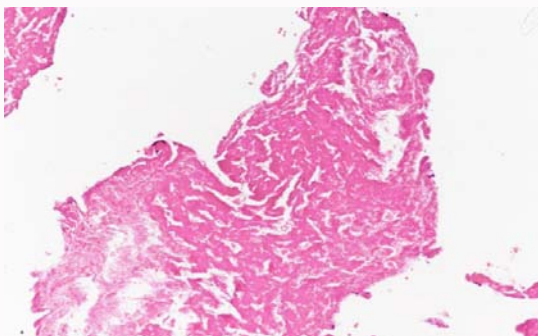
Singh. This is an open access article distributed under the Creative Commons Attribution License, which permits unrestricted use, distribution, and reproduction in any medium, provided the original work is properly cited.



**Figure 1:** 200X FNA smear showing fibro fatty tissue.



**Figure 2:** Photomicrograph of excised specimen (100x) thrombus in blood vessel lined by endothelium.



**Figure 3:** Photomicrograph of excised specimen (200x) showing thrombus in blood vessel lined by endothelial cells.

It is difficult to make a pre-operative diagnosis of Masson's haemangioma, and it is often misdiagnosed as fibrolipoma, ganglion, cyst, soft tissue tumor or sarcoma. The lesion has no age or gender predilection and has been frequently reported from the head, neck, fingers, trunk and cutaneous veins. It usually presents as a small, firm, superficial mass with bluish-red discoloration of the overlying skin. Color Doppler or a plain ultrasound can be helpful in diagnosing a vascular lesion, but there are no pathognomic features to make the diagnosis with certainty.

Histopathological examination of the excised swelling is the gold standard for making a diagnosis-the following features are important in making the diagnosis and ruling out other vascular lesions:

- Intravascular papillary endothelial hyperplasia, either well-circumscribed or encapsulated;
- The papillae are composed of fibro-hyalinized tissue of two or more endothelial cell layers;
- The proliferative process is completely limited to the intravascular spaces;
- The endothelial cells are hyperchromatic, but extreme nuclear atypia and mitotic figures and necrosis are not seen;
- There may be pseudo channels, but there are no irregular or anastomosing blood vessels in the stroma [5].

Based on histopathology, Masson's haemangioma can be classified into three distinct categories:

However, these different pathological varieties do not have any clinical significance, since the treatment is total excision. When resected completely, recurrence is extremely rare.

- A "pure form" that occurs within a dilated vascular space, and is most frequently located in the fingers, in the region between the elbows and hands or head and neck,
- A "mixed form" that represents a focal change in a pre-existing haemangioma, vascular malformation, or pyogenic granuloma, and
- A rare "indeterminate" form that does not belong to either of the first two categories, and has an extravascular origin [6].

However, these different pathological varieties do not have any clinical significance, since the treatment is total excision. When resected completely, recurrence is extremely rare.

## References

1. Abdal K DDS, Hafezi Ahmadi M. Masson's hemangioma of the urethra: A case report. *Iran J Med Sci.* 2018;43(3):336-9.
2. Clearkin KP, Enzinger FM. Intravascular papillary endothelial hyperplasia. *Arch Pathol Lab Med.* 1976;100(8):441-4.
3. Kauffman SL, Stout AP. Malignant hemangioendothelioma in infants and children. *Cancer.* 1961;14:1186-96.
4. Farah JM, Sawke N, Sawke GK. Cutaneous intravascular papillary endothelial hyperplasia of the forearm: A case report. *People's J Scientific Res.* 2013;6(2):38-40.
5. Korkolis DP, Papaevangelou M, Koulaxouzidis G, Zirganos N, Psychogiou H, Vassilopoulos PP. Intravascular papillary endothelial hyperplasia (Masson's hemangioma) presenting as a soft-tissue sarcoma. *Anticancer Res.* 2005;25(2B):1409-12.
6. Gill M, Batra A, Jain D, Gupta V, Sen R, Gupta S. Intravascular papillary endothelial hyperplasia (Masson's Hemangioma) presenting as soft tissue mass in left scapular region-An unusual presentation. *J Interdiscipl Histopathol.* 2014;2(3):179-83.