



A Case Report of Thrombocytopenia Associated with Initiation of Dimethyl-Fumarate in a Patient with Multiple Sclerosis

Allison Jordan¹, Michael K Racke¹ and Jaime Imitola^{1,2*}

¹Department of Neurology, The Ohio State University Wexner Medical Center, Columbus, OH, USA

²Department of Neuroimmunology and Multiple Sclerosis, Comprehensive Multiple Sclerosis Center, OH, USA

Abstract

This is a case report of a 44-year-old woman with a past medical history of idiopathic thrombocytopenia purpura (ITP), with previous stable platelet counts, who developed drug induced thrombocytopenia after starting dimethyl fumarate for her Relapsing Remitting Multiple Sclerosis (RRMS). Her platelet count returned to baseline without any intervention except for cessation of the drug. To date, thrombocytopenia has not been described as a side effect of dimethyl fumarate. Treatment of Multiple Sclerosis (MS) patients with dimethyl fumarate in the setting of concomitant Idiopathic thrombocytopenic purpura (ITP) should prompt close platelet monitoring.

Keywords: Dimethyl-fumarate; Idiopathic thrombocytopenic purpura

Introduction

Dimethyl fumarate (Tecfidera), was first approved by the FDA in 2013 for relapsing remitting multiple sclerosis. While its exact mechanism of action has not been fully elucidated, Tecfidera has been shown to selectively reduce circulating CD4+ and CD8+ lymphocytes [1]. Lymphopenia is a well characterized side effect of dimethyl fumarate, with increased incidence and severity in patients older than fifty-five [2]. Fumaric acid esters, which include dimethyl fumarate, have also been shown to cause eosinophilia after initiation of treatment [3]. Case reports of eosinophilic fasciitis like disorder [4] and eosinophilic cardiac injury [5] have been reported with dimethyl fumarate therapy. Additional commonly reported side effects of this medication include flushing and gastrointestinal side effects such as nausea, diarrhea, and abdominal pain [6]. While dimethyl fumarate has been shown to affect other hematopoietic cell lines, thrombocytopenia has not been observed. Here we present a case of a forty-four-year-old woman with past medical history significant for Idiopathic Thrombocytopenia Purpura (ITP) who developed severe thrombocytopenia after starting dimethyl fumarate for her relapsing remitting multiple sclerosis.

Case Presentation

The patient is a 44-year-old African American woman with a past medical history of ITP, depression, GERD and migraines. She was first diagnosed with ITP in 2013 by a hematologist at The Ohio State University. Diagnosis of ITP was given based on her clinical presentation and other wise negative laboratory evaluation. At time of presentation she was started on a short course of IVIG and was maintained on prednisone until November 2013. She did not require any further steroid therapy until her diagnosis of multiple sclerosis in May 2014.

She was diagnosed with relapsing remitting multiple sclerosis in May 2014 with optic neuritis as her first presenting symptom. Diagnosis was based on the 2010 McDonald criteria for Multiple Sclerosis. At time of diagnosis she was given methylprednisolone 1 gram IV for 3 days and completed a prednisone taper over the course of 2 weeks. After investigating the literature for any contraindications with the use of Dimethyl fumarate in ITP patients, she was started on Dimethyl fumarate in August 2014 as a first line disease modifying therapy.

Given the patient's diagnosis of ITP, a complete blood count (CBC) was obtained every few months for routine surveillance. Her last routine blood draw prior to drug initiation was on 7/31/14, which showed a platelet count of seventy-seventy thousand, which was her normal baseline. The patient started dimethyl fumarate on 8/20/14. Her platelet count was checked after initiation of

OPEN ACCESS

*Correspondence:

Jaime Imitola, Department of Neuroimmunology and Multiple Sclerosis, Ohio State University Wexner Medical Center, 460W12th Ave, Biomedical Research Tower, Room 688, Columbus, OH 4321, USA, E-mail: jaime.imitola@osumc.edu

Received Date: 08 Apr 2017

Accepted Date: 04 May 2017

Published Date: 06 May 2017

Citation:

Jordan A, Racke MK, Imitola J. A Case Report of Thrombocytopenia Associated with Initiation of Dimethyl-Fumarate in a Patient with Multiple Sclerosis. *Ann Clin Case Rep.* 2017; 2: 1350.

ISSN: 2474-1655

Copyright © 2017 Jaime Imitola. This is an open access article distributed under the Creative Commons Attribution License, which permits unrestricted use, distribution, and reproduction in any medium, provided the original work is properly cited.

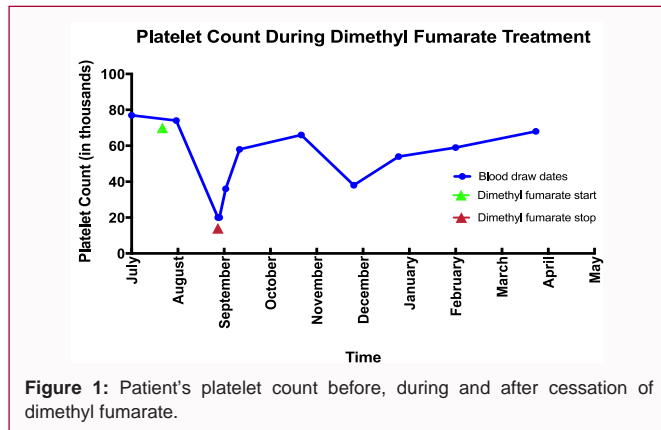


Figure 1: Patient's platelet count before, during and after cessation of dimethyl fumarate.

the drug (on 8/29/14) with a result of seventy-four thousand. The patient tolerated initiation of dimethyl fumarate well, with only a report of mild nausea which improved when the patient took the medication with food. A CBC was ordered on 9/25/14 as part of a routine lab check, and platelets were found to be twenty thousand. This number was confirmed by two independent labs. The first lab draw was completed at The Ohio State University, and the second lab draw was completed a day later on 9/26/14 at the patient's local laboratory. Dimethyl fumarate was immediately discontinued by the patient on 9/25/14. After discontinuation of the drug, the patient's platelet counts slowly returned to baseline without need for steroid intervention (Figure 1).

Discussion

Drug induced platelet destruction is thought to be antibody mediated [7]. Onset of platelet destruction typically occurs after a week or more of therapy with the offending agent, but can occur as early as 1-2 days [7]. The decline in this patient's platelet count after initiating dimethyl fumarate, combined with return to baseline platelet count after discontinuation of dimethyl fumarate, strongly suggests drug induced thrombocytopenia. Additionally, the time from drug initiation to platelet nadir (in this case occurring sometime between 9 and 36 days after drug initiation) closely matches the typical time line of drug-induced thrombocytopenia. One could argue that the patient's drop in platelet count could be secondary to her known ITP, but platelet decline in the setting of an ITP flare would not likely resolve without steroid treatment.

It is also possible that dimethyl fumarate directly caused thrombocytopenia by impairing platelet maturation. Dimethyl fumarate has been shown to activate NRF2, a transcription factor integral to megakaryocyte proliferation [8]. Platelet maturation

requires an increased ratio of the transcription factor P45 to NRF2 [8]. Through the activation of NRF2, it is possible that dimethyl fumarate could hinder megakaryocyte maturation resulting in underproduction of mature platelets.

Given the popularity of dimethyl fumarate in the treatment of MS, this case report aspires to make the medical community aware of the possibility of drug induced thrombocytopenia with dimethyl fumarate. It is likely that our patient was at higher risk of this side effect given her co-diagnosis of MS and ITP. In one population based study in Maryland, patients with ITP were 25 times more likely to have MS than the general population [9], showing co-diagnoses is not rare. When starting dimethyl fumarate, heightened monitoring is suggested in patients with co-diagnoses of MS and ITP.

In summary, this is a case of a 44-year-old woman who developed drug-induced thrombocytopenia after initiation of Dimethyl fumarate for relapsing remitting multiple sclerosis.

References

- Longbrake EE, Ramsbottom MJ, Cantoni C, Ghezzi L, Cross AH, Piccio L. Dimethyl fumarate selectively reduces memory T cells in multiple sclerosis patients. *Mult Scler*. 2016;22(8):1061-70.
- Longbrake EE, Naismith RT, Parks BJ, Wu GF, Cross AH. Dimethyl fumarate-associated lymphopenia: Risk factors and clinical significance. *Mult Scler J Exp Transl Clin*. 2015;1:2055217315596994.
- Harries MJ, Chalmers RJ, Griffiths CE. Fumaric acid esters for severe psoriasis: a retrospective review of 58 cases. *Br J Dermatol*. 2005;153(3):549-51.
- Sheu J, Kattapuram SV, Stankiewicz JM, Merola JF. Eosinophilic fasciitis-like disorder developing in the setting of multiple sclerosis therapy. *J Drugs Dermatol*. 2014;13(9):1144-7.
- Brown W, Suksaranjit P, Khor LL. Eosinophil-Mediated Cardiac Injury Possibly Due to Dimethyl Fumarate. *JACC Cardiovasc Imaging*. 2016;9(6):752-3.
- Gold R, Kappos L, Arnold DL, Bar-Or A, Giovannoni G, Selmaj K, et al. Placebo-controlled phase 3 study of oral BG-12 for relapsing multiple sclerosis. *N Engl J Med*. 2012;367(12):1098-107.
- Aster RH, Bougie DW. Drug-induced immune thrombocytopenia. *N Engl J Med*. 2007;357(6):580-7.
- Motohashi H, Kimura M, Fujita R, Inoue A, Pan X, Takayama M, et al. NF-E2 domination over Nrf2 promotes ROS accumulation and megakaryocytic maturation. *Blood*. 2010;115(3):677-86.
- Segal JB, Powe NR. Prevalence of immune thrombocytopenia: analyses of administrative data. *J Thromb Haemost*. 2006;4:2377-83.