



Uterine Arteriovenous Fistula: Final Surgical Treatment - A Case Report

Martha Esmeralda Espinosa Esparza¹, Oscar Huerta Jiménez² and María Valeria Jiménez Báez^{3*}

¹Mexican Institute of Social Security, Hospital General Regional Lic Ignacio Garcia Tellez, Mexico

²Mexican Institute of Social Security Regional General Hospital Number 17, Mexico

³Head of Medical Services Services, IMSS Quintana Roo, Mexico

Abstract

Patient 30 years with uterine arteriovenous fistula secondary to placental polyps associated with obstetrical surgical procedures such as curettage instrumented four weeks prior, cesarean. Have bleeding transvaginal three days glittering red evolution accompanied by pain type colic in area hypogastric, data low cardiac output is hospitalized and transfused packed red blood cells. E pelvic cografía with findings of endometrial thickening l about ovular remains. A surgical procedure is performed with instrumented uterine curettage and a pathological study is sent, which reports ovuloplacental remains with degenerative changes associated with retention. At three weeks she presented transvaginal bleeding and pelvic pain, as well as galactorrhea, a pelvic ultrasound was performed with the following findings; uterus enlarged with vascularity to the dop mode PLER in the background and with endometrial thickening, tomography abdominopelvic complementary to suggestive findings retention of products of conception associated with fistula arteriovenous uterine and diverticulosis colon, so it was decided to resolution and definitive treatment with surgical programming performing a total abdominal hysterectomy.

Keywords: Retention of products of conception; Total abdominal hysterectomy; Endometrial thickening

OPEN ACCESS

*Correspondence:

María Valeria Jiménez Báez, Head of Medical Services Services, IMSS Quintana Roo, Av, Politécnico Nacional s/n between Tepic and Kinic, CP. 77533, Cancun Quintana Roo, Mexico, E-mail: Valeria.jimenezb@gmail.com

Received Date: 10 Aug 2021

Accepted Date: 26 Aug 2021

Published Date: 02 Sep 2021

Citation:

Esparza MEE, Jiménez OH, Báez MVJ. Uterine Arteriovenous Fistula: Final Surgical Treatment - A Case Report. *Ann Clin Case Rep.* 2021; 6: 1978.

ISSN: 2474-1655

Copyright © 2021 María Valeria Jiménez Báez. This is an open access article distributed under the Creative Commons Attribution License, which permits unrestricted use, distribution, and reproduction in any medium, provided the original work is properly cited.

Background

Fistulas arteriovenous and Malformations Arteriovenous (MAV) correspond to two different conditions as the first considered acquired which are the most common and s second considered congenital. R represents 1% to 2% of bleeding, but generally severe due to the profuse bleeding that can cause n. They occur mainly between the ages of 15 to 49 years with a mean of 29 years [1].

Uterine arteriovenous fistulas have classically been related to chorioplacental affection such as molar disease, choriocarcinoma, extensive or focal placental accrete, as well as with previous uterine surgeries (myomectomy, uterine curettage or cesarean section), infections, as well as the association with diethylethyl bestrol, among others. Suelen presents multiple arteries food, a ball of vessels with histological, arterial, and venous characteristics, apart from numerous veins draining one. In cases where this entity is related to previous uterine surgery, the highest percentage of cases is related to uterine curettage instrumented secondary to a traumatic cause in its genesis [1]. It is associated with placental polyps which are defined as the coexistence of this trophoblastic, decidual, or fetal, retained after abortion, or cesarean birth [2]. Pregnancy plays an important role in the formation of uterine arteriovenous abnormalities, where abortion represents the most common risk factor associated with retention of placental tissue [2].

The clinic is usually associated with abnormal vaginal bleeding; that is, massive vaginal bleeding or hypermenorrhea. Its clinical symptoms are indolent and not very specific, its presentation can vary from dysfunctional uterine bleeding to infertility due to recurrent abortion (due to the hyper vascularization that alters embryo implantation), including death due to hypovolemic shock. Other less common symptoms include chronic pelvic pain and hematuria [1], so by both pathology should be suspected in any patient with boxes metrorrhagia abundant and persistent that continues after performing curettage uterine instrumented [2].

Once the possibility of pregnancy with human chorionic gonadotropin has been ruled out, a vaginal ultrasound is recommended, where heterogeneity will be observed, small irregular,

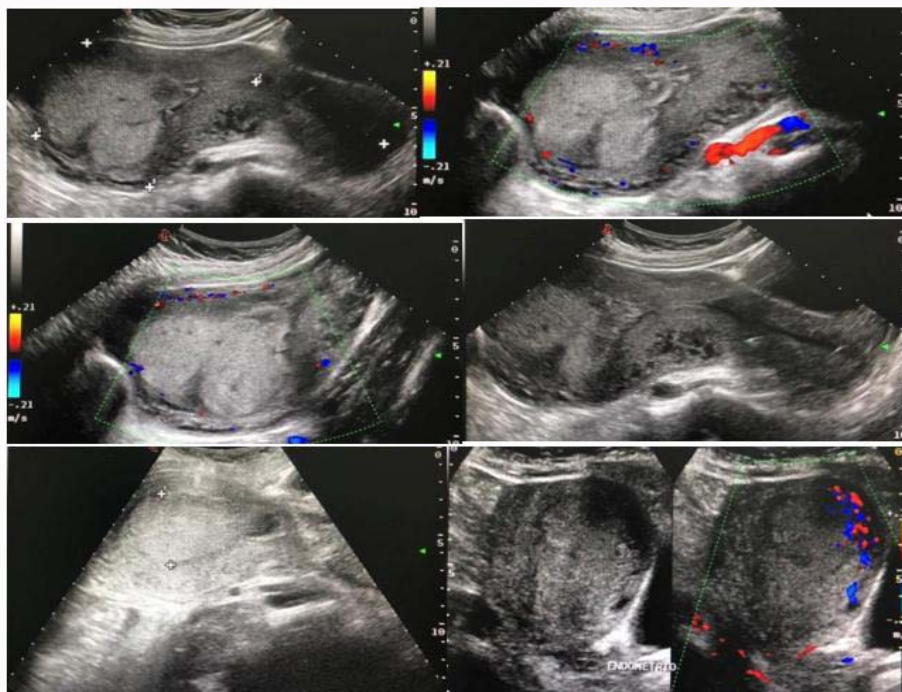


Figure 1: VA uterus measuring 135 mm × 57 mm × 76 mm, with regular borders, homogeneous myometrium without evidence of lesions. Central endometrium, maintains interface with the myometrium, thickening of up to 27 mm, it is observed heterogeneous, and predominantly hypoechoic with an anechoic area inside that, after the application of color Doppler at the level of the uterine fundus, vascularity is identified at the level of the endometrial myometrial junction.

poorly defined anechoic spaces, which are usually present in 65% of congenital AVMs and 35% of AVMs acquired [1]. The purpose of this manuscript is to present the case of a patient with a uterine arteriovenous fistula secondary to placental polyps associated with obstetric surgical procedures such as instrumented uterine curettage.

Clinical Case

The 30-year-old patient who underwent complementary instrumented uterine curettage for incomplete abortion in the 2nd trimester in October 2020, attending obstetric emergencies 4 weeks after the surgical procedure, referring to presenting transvaginal bleeding of 3 days of evolution of a glowing red type accompanied by pelvic pain (intensity 8/10 on the analogous pain scale), asthenia, adynamia, and lipothymia. Among your OB/GYN history stand out: Menarche at 11 years of age, regular rhythm (28 × 4 days), eumenorrhic.

On physical examination, the patient was alert, conscious, oriented with pale integuments and mucous membranes; abdomen

with peristalsis present, painful on palpation of the hypogastrium, without signs of peritoneal irritation. On vaginal examination, a eutermic vaginal cavity was found, a closed external cervical os lateralized to the left, uterus in introversion of 10 cm × 8 cm, painful bimanual touch, and moderate bleeding.

Paraclinical studies were carried out which reported Hemoglobin 6, hematocrit 18%, platelets 259 thousand, Usg pelvic or that reported uterus of 116 mm × 83 mm, the endometrium of 60 mm about ovular remains, with heterogeneous myometrial color Doppler vascularity. The patient was stabilized with fluid volume replacement and blood transfusions and diagnosed as probable abnormal uterine bleeding secondary to the retention of ovular remains, so instrumented uterine curettage was performed and a sample was sent to pathology which reported these ovule-placental degenerative changes associated with retention, it is decided high of service, without however the patient again presents bleeding transvaginal abundant that warrants hospitalization, is performed ultrasound reporting endometrium 27 mm with area anechoic inside located in fundal that after application of Doppler color, vascularity is identified at the level of the endometrial

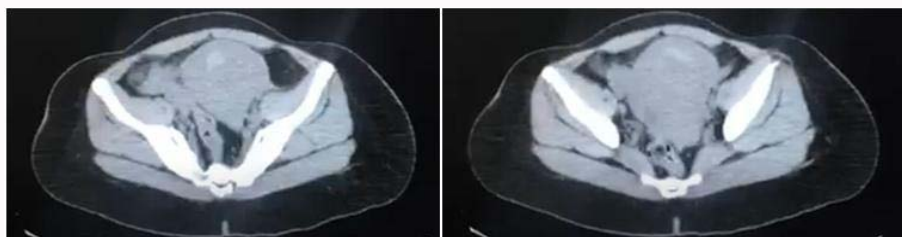

Figure 2: Uterus in Anteroverso bending 121 mm × 74 mm × 86 mm, myometrium anterior wall is observed thinned 13 mm concerning the rear, to background level is observed irregular loss of the interface with the endometrial cavity which presents strengthening the administration of contrast medium dependent of arcuate arteries towards the uterine fundus with two images of irregular morphology that together measure 16 mm 17 mm × 21 mm. Diagnostic impression: findings suggestive of retention of products of conception associated with uterine arteriovenous fistula.

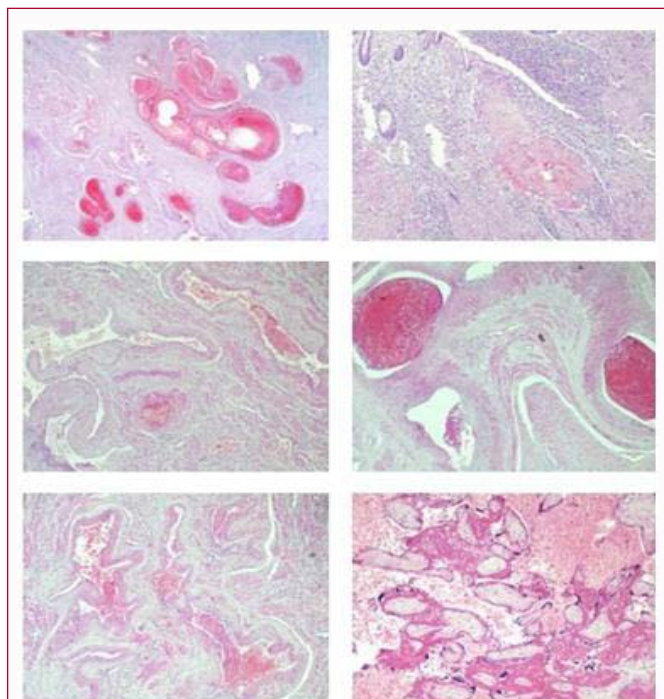


Figure 3: Ovulo placental remnants in the uterine fundus with ischemic changes and hemorrhage. A polypoid arteriovenous fistula in the endometrial cavity with extensive thrombosis. Basal endometrium. Cervicitis and chronic endocervicitis.

myometrial junction "ball image" (Figure 1).

Abdominopelvic CT was performed, which reported findings suggestive of retention of products of conception associated with uterine arteriovenous fistula (Figure 2), for which a total abdominal hysterectomy was performed as definitive treatment, reporting in the pathological study of the specimen ovuloplacental remains in the uterine fundus with Ischemic changes and hemorrhage, polypoid arteriovenous fistula in the endometrial cavity with extensive thrombosis, basal endometrium, cervicitis and chronic endocervicitis (Figure 3).

Discussion

Uterine arteriovenous fistulas are usually acquired and present in patients with a history of surgical intervention on the uterus as a curettage, or disorder such as trophoblastic disease as it appeared in this case with a history of instrumented uterine discharge complementary to an incomplete abortion of the uterus second trimester [2].

Among the most frequent symptoms of this pathology is abundant abnormal vaginal bleeding that does not refer to the usual treatment, which is produced by exposure of the vessels in the endometrium, so, frequently, it is associated with acute anemia and data of low cardiac output, symptoms that the patient presented in this case [2].

The suspected diagnosis of arteriovenous fistula uterine is difficult because initially you think the most common abnormal after an obstetrical surgical procedure causes uterine bleeding as they are remnants ovuloplacental or in the case of degrading uterine instrumented some quirúrgi complication AC it, however, the diagnostic suspicion begins when vaginal bleeding does not remit despite habitual treatment and expectant management. The incidence of this pathology is low and infrequent, therefore, in the event of any

suspicion of the same, imaging tests should be carried out before carrying out any intervention [2].

Regarding the diagnosis of uterine arteriovenous fistula, initially, pelvic ultrasound with color Doppler is considered a first-line study in which a vascular «mosaic» image will be visualized with yellow areas corresponding to the areas of maximum reverberation, typical of arteriovenous shunts and fistulas. The ball is concentrated and occupies the eco negative areas; is present in 95% of cases, the study of diagnostic confirmation is to angiografía which is considered the gold standard for the definitive diagnosis of AV fistulas [1,2]. CT (Computed Tomography) and MRI (nuclear magnetic resonance) is recommended, but not necessary [1]. There are also other diagnostic aids such as vaginal ultrasonography hidrosónografía and hysteroscopy with direct visualization and localization retained tissue [1,2].

It is common to consider the differential diagnosis between AV fistulas and incomplete abortion or retention of intrauterine remains. After a thorough review, in most of them the AV fistula at the intramyometrial level coexists with remnants at the intrauterine level, so establishing a differential diagnosis is complicated. The hysteroscopy can establish whether or not there remains intracavitary associated or not [1].

Currently, we can easily suspect this vascular lesion with the incorporation of color Doppler in ultrasound, which increases diagnostic sensitivity; represents a turbulent flow with high velocities and a low resistance index [3,4].

The definitive diagnosis is obtained by applying arteriography uterine arteries will show a tortuous arterial mass with direct communication hypertrophic veins [5-9].

Once the fistula has been diagnosed, initial treatment is usually expectant with or without administration of ergonovines [2]. Treatment of uterine AVM depends on the patient's symptoms, desire for fertility, and the location of the AVM lesion. The approach divides the asymptomatic and symptomatic cases. Stable asymptomatic cases are treated medically (controls, gestagens, etc.), since they may even disappear [1]. In those patients in whom symptoms persist or bleeding transvaginal is abundant conditioning hemodynamic instability should be considered treatment definitive with performing hysterectomy or embolization selective uterine artery [1,2] which nowadays is recommended as a treatment of choice its efficacy and preservation of fertility [1].

Hemostatic curettage is contraindicated as it can accelerate bleeding, life-threatening [1,2]. The follow-up by color Doppler can evaluate the resolution of the MAV, showing the decreased flow and increased resistance in the vasculature for its ability to detect even small lesions [1].

Treatment depends mainly on the patient's hemodynamic stability and the intensity of the bleeding curettage is contraindicated in ést as patients. H can be performed abdominal hysterectomy Total definitive treatment however nowadays treatment of choice is and mobilization uterine artery as it gives less surgical invasion, greater efficiency, and preserves fertility.

Conclusion

Uterine arteriovenous fistulas should be considered more frequent than documented and suspected in the presence of any

heavy bleeding in patients with a history of obstetric surgical procedure or trophoblastic disease. Doppler ultrasound is the most useful study initially in the event of a suspected diagnosis, which will report the vascular mosaic image or "ball" image, most of the time it is also associated with a significant increase in endometrial thickness. Angiography is the ideal and confirmatory study of this pathology, if feasible. The treatment of choice is currently the embolization of uterine arteries.

References

1. Rodríguez A, Díaz JD, Napoles S, Hernández M, Casián GA. Uterine arteriovenous malformation. *Rev Hosp Jua Mex.* 2018;85(2):100-4.
2. Sánchez RA, González JE, Romero S, Hurtado R, Bautista A. Uterine arteriovenous fistula-placental polyp: Hysteroscopic treatment. Report of a case. *Ginecol Obstet Mex.* 2017;85(1):27-31.
3. Manolitsas T, Hurley V, Gilford E. Uterine arteriovenous malformation—a rare cause of uterine hemorrhage. *AustNZJ Obstet Gynaecol.* 1994;34(2):197-9.
4. Majmudar B, Ghane N, Horowitz IR, Graham D. Uterine arteriovenous malformation necessitating hysterectomy with bilateral salpingo-oophorectomy in a young pregnant patient. *Arch Pathol Lab Med.* 1998;122(9):842-5.
5. Burrows PE. Vascular malformations involving the female pelvis. *Semin Interv Radiol.* 2008;25:347-60.
6. Malraux G, Timmerman D, Heye S, Wilms G. Acquired uterine vascular malformations: Radiological and clinical outcome after transcatheter embolotherapy. *Eur Radiol.* 2006;16(2):299-306.
7. Tullius TG Jr., Ross JR, Flores M, Ghaleb M, Kupesic Plavsic S. Use of three-dimensional power Doppler sonography in the diagnosis of uterine arteriovenous malformation and follow-up after uterine artery embolization: Case report and brief review of literature. *J Clin Ultrasound.* 2015;43(5):327-34.
8. O'Brien P, Neyastani A, Buckley AR, Chang SD, Legiehn GM. Uterine arteriovenous malformations. From diagnosis to treatment. *J Ultrasound Med.* 2006;25(11):1387-92.
9. Roach MK, Thomasee MS. Acquired uterine arteriovenous malformation and retained placenta increta. *Obstet Gynecol.* 2015;126 (3):642-4.