Annals of Clinical Case Reports

Case Report
Published: 14 Oct, 2022

Unintended Damage of a Right Parasternal Subcutaneous Implantable Cardioverter-Defibrillator Electrode in a Patient Undergoing Cardiac Surgery

*Juan Fiorda Diaz, Joseph Holecko, Kasey Fiorini and Katja R Turner**

Department of Anesthesiology, The Ohio State University Wexner Medical Center, USA

Abstract

Subcutaneous Implantable Cardioverter-Defibrillators (S-ICD®) are a novel approach for primary and secondary prevention of sudden cardiac death in patients in whom intravascular or epicardial leads are not indicated. We described a case of a 47-year-old-male with multiple cardiovascular and renal comorbidities undergoing mitral valve surgery. Past medical history included an S-ICD® electrode implanted along the right parasternal border. Adhesion's dissection of the subcutaneous electrode during surgery was challenging and resulted in an unintended damage of the subcutaneous electrode by electrocautery. Proper positioning of the device components is crucial for appropriate functioning. Prompt perioperative recognition of positioned components by surgeon and anesthesiologist may mitigate potential complications including ineffective/inappropriate shock therapy and damage to the device components (i.e., surgical dissection).

Keywords: Sudden cardiac death; Subcutaneous implantable cardioverter-defibrillator; Transvenous implantable cardioverter-defibrillator; Shock therapy; Cardiac surgery

OPEN ACCESS

Correspondence:
Katja R Turner, Department of Anesthesiology, The Ohio State University Wexner Medical Center, N411 Doan Hall, 410W 10th Ave, Columbus, Ohio, 43210, USA, Tel: +1 (614) 293-8487; Fax: +1 (614) 293-8153;
E-mail: Katja.Turner@osumc.edu

Received Date: *20 Sep 2022*
Accepted Date*: 07 Oct 2022*
Published Date*: 14 Oct 2022*

Citation:
Fiorda Diaz J, Holecko J, Fiorini K, Turner KR. Unintended Damage of a Right Parasternal Subcutaneous Implantable Cardioverter-De ibrillator Electrode in a Patient Undergoing Cardiac Surgery. Ann Clin Case Rep. 2022; 7: 2317. ***ISSN: 2474-1655****.*

Introduction

Sudden Cardiac Death (SCD) remains a significant cause of mortality worldwide. In the United States, over 350,000 individuals experience an out-of-hospital sudden cardiac arrest each year [1] making early defibrillation therapy crucial for survival. Transvenous Implantable Cardioverter-Defibrillator (TV-ICD) systems have been successfully utilized for decades for primary and secondary prevention in patients at high risk of SCD (e.g., unsustained ventricular tachyarrhythmia, ischemic cardiomyopathies, ion channelopathies, hypertrophic cardiomyopathy, and heart failure with low ejection fraction) [2,3]. However, TV-ICDs have well-established complications such as systemic infections, pneumothorax, central venous occlusions, lead dislodgement, lead malfunction, and cardiovascular perforation [4]. Inherently, many of these complications result from lead placement in the central venous system and cardiac chambers. Furthermore, extraction of a TV-ICD system due to infection or lead malfunction has been associated with significant morbidity and mortality [4]. The Subcutaneous Implantable Cardioverter-Defibrillator (S-ICD;® Boston Scientific, Marlborough, MA, USA) has emerged as an attractive alternative to TV-ICDs. All S-ICD system components are extra-thoracic, which mitigates the risk of many of the complications linked to the use of the TV-ICD system. The S-ICD® system uses a pulse generator and a single electrode for sensing, detection, and defibrillation therapy (biphasic shock of 80 Joules) of life-threatening ventricular arrhythmias (e.g., ventricular tachycardia and ventricular fibrillation) [5,6]. Correct positioning of the S-ICD® system components is of utmost importance for the device's proper functioning. Although the manufacturer recommends electrode positioning along the Left Parasternal (LP) border, studies have found that certain patients may benefit from Right Parasternal (RP) lead positioning [7,8]. The S-ICD® system is approved for primary and secondary prevention of SCD in patients at high risk of life-threatening ventricular tachyarrhythmias. However, the lack of sustained pacing capabilities precludes S-ICD® use in patients with pacing indications [4,5]. We present a case of unintended RP lead damage in a patient with past surgical history of Coronary Artery Bypass Graft (CABG) and S-ICD® implantation undergoing mitral valve surgery. In addition, a framework for the perioperative management of patients with S-ICD® will be discussed.

Case Presentation

Patient Information

A 47-year-old-male with multiple medical comorbidities including heart failure with reduced

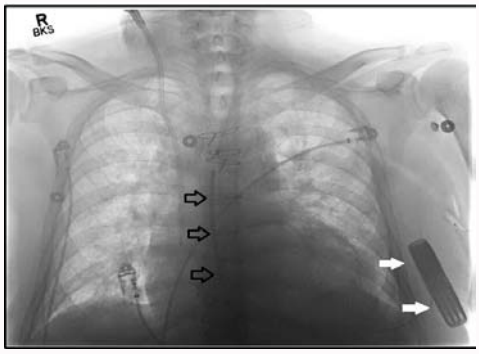

Figure 1: Chest radiograph demonstrating displacement of the S-ICD electrode along the right parasternal border. Black arrows = Electrode; White arrows = Pulse generator.

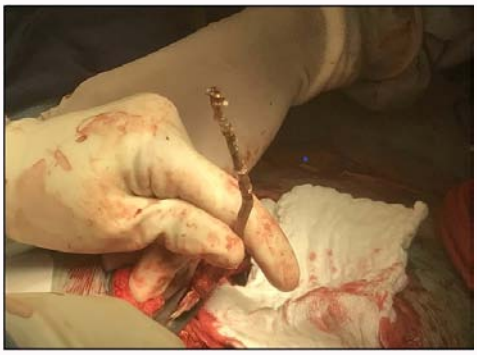

Figure 2: Photograph showing the damaged S-ICD electrode after sternotomy.

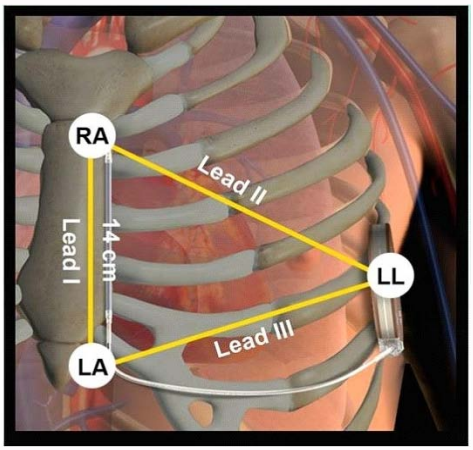

Figure 3: Image showing the S-ICD system sensing vectors. Image reproduced with permission from Boston Scientific.

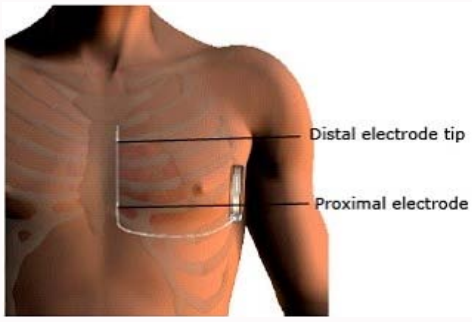

Figure 4: Image showing optimal placement of the S-ICD system, with the electrode tunneled from the pulse generator to the xiphoid process, and along the left parasternal border. Image reproduced with permission from Boston Scientific.

ejection fraction, coronary artery disease status post CABG, atrial fibrillation, end-stage renal disease, and severe mitral regurgitation secondary to endocarditis, presented for mitral valve surgery. A preoperative transesophageal echocardiogram revealed a left ventricular ejection fraction of 20% to 25%, vegetations on the posterior mitral leaflet with leaflet perforation, severe mitral regurgitation, and mitral annular calcification. A review of the preoperative chest radiograph showed the S-ICD® electrode along the right parasternal border (Figure 1). Device interrogation revealed no evidence of recent arrhythmias or therapies. Anti-tachycardia capability of the S-ICD® was disabled before surgery in order to avoid inappropriate shocks. Intraoperatively, mobilization of the electrode was deemed necessary for median sternotomy. The dissection of the subcutaneous electrode was difficult due to adhesions formed after the initial sternotomy, which resulted in unintended damage of the subcutaneous electrode by electrocautery (Figure 2). Following successful mitral valve surgery, the S-ICD® system was extracted. A new S-ICD® system was successfully implanted a week later. After appropriate screening, proper function of the system was achieved with the electrode now positioned along the left sternal border and an uneventful recovery.

Discussion

Approved by the U.S. Food and Drug Administration in 2012, the S-ICD® system's extra-thoracic location is appealing for treating malignant ventricular arrhythmias [5]. The S-ICD® is the only ICD that does not require a direct intra- or extra-cardiac lead, mitigating the risk of complications associated with transvenous and epicardial leads. However, abnormal detection of supraventricular arrhythmias (with subsequent inappropriate shock therapy), inability for bradycardia and anti-tachycardia pacing, and increased time to deliver therapeutic shocks remain as the main concerns linked to its use [9,10]. Currently, an electrocardiographic screening test is scheduled in patients under consideration for an S-ICD®. This process includes surface electrodes being placed along the left sternal border in a configuration that mimics the sensing vectors within the S-ICD® system (i.e., 1 cm left lateral to the xiphoid process, 14 cm cranial to the xiphoid process along the left sternal border, and in a lateral position at the left 5th intercostal space; Figure 3). Sensing vectors obtained from the three surface electrodes in both the supine and standing position are analyzed with the Boston Scientific Patient Screening Tool at gains of 5 mV, 10 mV, and 20 mV. The screening tool specifically assesses the QRS complexes' stability at any gain and in any patient position and screens for elevated baseline T-wave amplitudes [11,12]. Patients with elevated baseline T-wave amplitudes are at higher risk for T-wave oversensing, which may result in inaccurate determination of ventricular tachyarrhythmia's by the S-ICD and subsequent inappropriate shock therapy [11,12]. A recent prospective study by Okamura et al. determined that a subset of patients who failed screening, benefited from RP implantation of the lead, with appropriate T-wave to R-wave ratio for proper functioning of the device [7]. Several implantation techniques have been described for the S-ICD® system. Traditionally, the pulse generator component is implanted along the left lateral chest wall through an inframammary incision with creation of a subcutaneous

pocket (Figure 4). However, other implantation techniques involving intermuscular and submuscular placement have been linked to operative and cosmetic advantages [13,14]. Once the pulse generator is in place, the electrode is tunneled to an incision to the left or right of the xiphoid process (depending on testing) and the lead is tunneled cranially along the sternal border. Care must be taken to tunnel the lead directly over bone tissue of the sternum to ensure proper lead placement and avoidance of high defibrillation energy requirements from high tissue impedance [13]. Additionally, the manufacturer recommends Defibrillation Testing (DT) immediately following implantation of the S-ICD®. The benefits of DT include, but are not limited to, confirmation of the system's integrity, high defibrillation thresholds that may require procedural revision, and lower initial shock energy programming [15]. Nevertheless, there is an increased risk of hemodynamic instability precipitated by the induction of ventricular fibrillation during this procedure. In a recent systematic review, Chue described the outcomes of S-ICD patients included in 16 clinical trials. The authors reported that only 77% of patients underwent DT following S-ICD® implantation, with 2% of these patients requiring repositioning of the pulse generator before successful DT, and 0.4% having their device explanted due to high defibrillation thresholds [16]. Patients with S-ICD"s presenting for surgery should be screened for the position of the S-ICD electrode and pulse generator. An anteroposterior chest radiograph will aid in device recognition and reveal the positioning of the parasternal electrode (Figure 1). Any deviation from left parasternal positioning should prompt further evaluation and planning, especially if a sternotomy is planned. The device interrogation in the preoperative setting can offer valuable information including implant date, remaining battery life, detected episodes of both treated and untreated ventricular tachyarrhythmia's, and electrode impedance status [6]. Finally, time permitting, preoperative consultation with an electrophysiologist can offer additional guidance on perioperative management. When proceeding to surgeries requiring a median sternotomy, the S-ICD® may be programmed off, and an alternate system to externally defibrillate should be used. External defibrillator pads should be placed on the patient and remain on until postoperative device interrogation and an electrophysiologist evaluation is completed. This is important in patients at high risk for developing perioperative arrhythmias such as those undergoing major cardiac or thoracic surgery, and those for which the device was placed for secondary prevention of ventricular tachyarrhythmia's. A recent case report by Angel described the successful management of a patient with an LP-positioned S-ICD presenting for primary cardiac surgery. The authors described an easy exposure, mobilization, and protection of the S-ICD® lead during the surgical intervention. Likewise, avoidance of contact between lead electrodes and sternal wires upon chest closure (which could lead to interference in S-ICD® electrodes) was mentioned [17]. In our case, the fact that the patient's prior sternotomy altered the tissue composure surrounding the lead, made the dissection more difficult than expected. Moreover, the need to perform a sternotomy across the plane of the existing S-ICD® electrode was even more challenging. Based on our experience, we suggest a perioperative multidisciplinary team approach for patients with S-ICD's undergoing cardiac or thoracic surgery, which should include the surgeon, anesthesiologists, and electrophysiologists. This systematic approach should aim at evaluating the functionality of the S-ICD® system components and minimizing the risk of intraoperative damage. Unintended surgical dissection or electrocautery-related damage to the structural integrity of the S-ICD® electrode as described in our case, could have led to ineffective and inappropriate shock therapy. Hence, damage to the S-ICD components often requires removal and surgical revision, which may increase perioperative morbidity and resource expenditures.

References

1. Members WG, Mozaffarian D, Benjamin EJ. Executive summary: Heart disease and stroke statistics--2016 update: A report from the American Heart Association. Circulation. 2016;133(4):447-54.
2. Buxton AE, Lee KL, Fisher JD. A randomized study of the prevention of sudden death in patients with coronary artery disease. N Engl J Med. 1999;341(25):1882-90.
3. Bennett M, Parkash R, Nery P. Canadian Cardiovascular Society/Canadian Heart Rhythm Society 2016 implantable cardioverter-defibrillator guidelines. Can J Cardiol. 2017;33(2):174-88.
4. Lewis GF, Gold MR. Safety and efficacy of the subcutaneous implantable defibrillator. J Am Coll Cardiol. 2016;67(4):445-54.
5. Essandoh MK, Portillo JG, Weiss R, Otey AJ, Zuleta-Alarcon AN, Humeidan ML, et al. Anesthesia care for subcutaneous implantable cardioverter/defibrillator placement: A single-center experience. J Clin Anesth. 2016;31:53-9.
6. Cronin B, Birgersdotter-Green U, Essandoh MK. Perioperative interrogation of Boston Scientific cardiovascular implantable electronic devices: A guide for anesthesiologists. J Cardiothorac Vasc Anesth. 2019;33(4):1076-89.
7. Okamura H, McLeod CJ, DeSimone CD. Right parasternal lead placement increases eligibility for subcutaneous implantable cardioverter defibrillator therapy in adults with congenital heart disease. Circ J. 2016;CJ-16-0153.
8. Bettin M, Dechering D, Frommeyer G. Right versus left parasternal electrode position in the entirely subcutaneous ICD. Clin Res Cardiol. 2018;107(5):389-94.
9. Nordkamp LRO, Knops RE, Bardy GH. Rationale and design of the PRAETORIAN trial: A Prospective, Randomized comparison of subcutaneous and transvenous implantable cardioverter-defibrillator therapy. Am Heart J. 2012;163(5):753-60.e2.
10. Patel KHK, Lambiase PD. The subcutaneous ICD—current evidence and challenges. Cardiovasc Diagn Ther. 2014;4(6):449-59.
11. User Manual Emblem S-ICD.
12. Groh CA, Sharma S, Pelchovitz DJ. Use of an electrocardiographic screening tool to determine candidacy for a subcutaneous implantable cardioverter-defibrillator. Heart Rhythm. 2014;11(8):1361-6.
13. Brouwer TF, Miller MA, Quast A-FB. Implantation of the subcutaneous implantable cardioverter-defibrillator: An evaluation of 4 implantation techniques. Circ Arrhythm Electrophysiol. 2017;10(1):e004663.
14. Migliore F, Allocca G, Calzolari V. Intermuscular two-incision technique for subcutaneous implantable cardioverter defibrillator implantation: Results from a multicenter registry. Pacing Clin Electrophysiol. 2017;40(3):278-85.
15. Bandar Al-Ghamdi AS, Alruwaili N, Emmanual S, Shoukri M, Mallawi Y. Subcutaneous implantable cardioverter defibrillators implantation without defibrillation threshold testing: A single center experience. Cardiol Res. 2017;8(6):319-26.
16. Chue CD, Kwok CS, Wong CW. Efficacy and safety of the subcutaneous implantable cardioverter defibrillator: A systematic review. Heart. 2017;103(17):1315-22.
17. Angel B, Overcash J, Fischer W, Fontaine JM. Surgical and electrophysiological considerations in the management of a patient with a subcutaneous implantable cardioverter-defibrillator undergoing coronary artery bypass surgery. HeartRhythm Case Rep. 2016;3(1):58-62.