Annals of Clinical Case Reports

Research Article
Published: 24 Jan, 2022

Two Cases of Application of PICC in Infants through Lower Limb and Literature Review

Danping Zhu[1], Yongzhi Lin[2], Liling Wang[2], Mingjiang Zhu[3,4#] and Xiaoxiao Ruan[5#]*

[1]Department of Intensive Care, Taizhou Central Hospital (Taizhou University Hospital), PR China

[2]Department of Pediatric Surgery, Taizhou Central Hospital (Taizhou University Hospital), PR China

[3]Laboratory of Lipid Metabolism in Human Nutrition and Related Diseases, Institute for Nutritional Sciences, Shanghai Institutes for Biological Sciences, Chinese Academy of Sciences, China

[4]Key Laboratory of Nutrition and Metabolism, Institute for Nutritional Sciences, Shanghai Institutes for Biological Sciences, Chinese Academy of Sciences, China

[5]Day-Time Ward of Taizhou Central Hospital (Taizhou University Hospital), PR China

[#]These authors equally contributed to this work

Abstract

PICC is difficult and has many side factors. The aim of this paper is to report two infant cases of application PICC through lower extremity insertion sites. It is important for infants with lower extremity. Peripherally Inserted Central Catheters (PICC) are being increasingly used in critical care setting. However, PICCs are associated with a number of complications, particularly Upper Extremity Venous Thrombosis (UEVT), leading to post-thrombotic syndrome, pulmonary embolism and increased risk of catheter-related infection. To review the literature surrounding PICCs and highlight the epidemiology, pathophysiology, diagnosis and management of PICC-related thrombosis in critically ill patients. We performed an electronic literature search of the databases PubMed, EMBASE and Google scholar using set search terms, from their commencement date to the end of January 2014. Our patient presented with lower extremity weakness and imaging confirmed the presence of air within the spinal canal. After conservative treatment, the strength deficit resolved and subsequent imaging revealed resolution of the air within the spinal canal. Decision to insert a PICC should be taken after careful risk stratification. There is lack of high-quality evidence assessing prevention strategies and management of PICC-related thrombosis in the ICU. Well-designed RCTs are required to estimate the prevalence of UEVT in ICU patients with PICCs and evaluate the efficacy and magnitude of clinical benefit and cost-effectiveness of therapeutic.

Keywords: PICC; Lower limb; Infant

OPEN ACCESS

Correspondence:
Xiaoxiao Ruan, Department of Intensive Care, Taizhou Central Hospital (Taizhou University Hospital), Zhejiang Province, PR China,
E-mail: 13819671803@163.com

Received Date: *01 Dec 2021*
Accepted Date*: 20 Jan 2022*
Published Date*: 24 Jan 2022*

Citation:
Zhu D, Lin Y, Wang L, Zhu M, Ruan X. Two Cases of Application of PICC in Infants through Lower Limb and Literature Review. Ann Clin Case Rep. 2022; 7: 2093.

ISSN: 2474-1655

Introduction

It is difficult to application PICC in infants, and sometimes needs some equipments to help the surgery [1]. The puncture fixation and nursing of Peripherally Inserted Central Catheters (PICCs) catheter indwelling via right lower limb vein are relatively simple, the position of vein is easy to determine, the success rate of puncture is very high [2], no restrictions on the importation of drugs, complications are very few, indwelling time is relatively long, and effective catheter maintenance can prevent mechanical phlebitis [3], catheter blockage, rupture, infection and fluid. The occurrence of complications such as exudation [4]. Wrightson [5] compare two ways of application PICC in infants. The way of indwelling PICC catheter through upper extremity vein exerts greater force, uneven exertion will stimulate and friction the intima of the blood vessel in children, causing the phenomenon of heterotopic end of the catheter, while indwelling PICC catheter through right lower extremity vein has less effect, and the force is more uniform, the stimulation and friction to the blood vessel is relatively small, so the vasoconstriction will not occur spasm and effectively reduce. Incidence of ectopic catheter [4,6,7]. PICC lines provide long-term venous access with increased flow rates and caloric concentration compared to peripheral Intravenous (IV) therapies. These lines are placed by using ultrasound to access a peripheral vein, placing an introducer sheath and manipulating the catheter to a central position. PICC lines have become prevalent due to their rapid and simple insertion and need for only mild sedation but are not without risk. In fact, a large prospective cohort study by Costa, et al. [8] found that 37.2% of PICC lines were removed due to complications. The

ascending lumbar vein originates from the common iliac vein and drains the epidural venous plexus. This anatomic configuration allows for the potential placement of central venous catheters within or immediately proximal to the epidural venous plexus when the ascending lumbar vein is inadvertently cannulated. Malposition of the PICC line tip into the ascending lumbar vein leading to serious neurological compromise in neonates has been well described in the literature [9,10]. A case series of six patients with inadvertent insertion of a central venous line into the epidural venous plexus *via* the ascending lumbar vein reported by Lavandosky et al. [11] showed that there are several warning signs to be cognizant of when inserting a central line that may indicate inadvertent insertion into the ascending lumbar vein: 1) no aspiration of blood after catheter placement, 2) lateral "hump" deviation of catheter at L4-L5 on abdominal flat plate radiograph, and 3) superimposed appearance of catheter tip on the spinal canal on abdominal cross-table lateral radiograph. We report here a complication of inadvertent placement of a PICC line into the ascending lumbar vein that has not been previously documented in the literature. In the following paragraph we discuss a case of pneumorrhachis after PICC line insertion in a neonate. Informed consent was obtained from the patient's parent/guardian for the treatment.

Materials and Methods

The Peripherally Inserted Central Catheter buy from BD company, cat No. 7717305, BD-Groshong three-valve PICC catheter, external diameter 3Fr, gravity flow rate 246 Ml, pre-alluvial volume 0.22 Ml [12].

The PICC puncture procedure

- Obtain the doctor's advice, sign the consent form of indwelling and prepare for it.
- Puncture personnel preparation: Standardize hand washing, wearing round caps, wearing masks, spare items and instruments.
- The puncture, assistant and patient should check their identity, allergy history and other relevant information before they can be executed.
- The patient should position himself and expose the puncture area. According to the patient's condition, the patient can wear a mask and hat.
- Choose suitable venous and puncture points.
- Puncture tourniquet above the anticipated puncture site. (Both cases were lower limbs without tourniquet tie.)
- Puncture veins were selected by using vascular ultrasound guidance system to check the blood flow, vessel wall and vessel diameter, so that the diameter of catheter and vessel accounted for less than 45% of menstrual ratio.
- Loosen tourniquet. (Both cases were lower extremities without tourniquet loosening.)
- Measurement and positioning.
- Superior vena cava measurements: the patient was in a supine position with 90 degrees of abduction of the upper arm and trunk. The arm and body were on the same horizontal plane. From the pre-puncture point along the vein to the right sternoclavicular joint and then down to the third rib space. Inferior vena cava measurement: from the pre-puncture point along the vein to the umbilical cord and then up to the lower xiphoid process.
- Measuring arm circumference: 10 cm above cubital fossa (5 cm in children). (Both cases are lower extremities, no measurement is required.)
- Record the measured values.
- Put a towel under the puncture site of the patient.
- Hand washing with no-washing disinfectant.
- Establishment of aseptic zone.
- Open PICC puncture bag and wear sterile gloves.
- Puncture point disinfection: Puncture point as the center of circular disinfection, 75% ethanol for three times, to dry, then 0.5% chlorhexidine alcohol solution or iodine for three times, to puncture point as the center, upper and lower arm diameter of 20 cm disinfection, to dry. The patient's arm was covered with aseptic treatment towel and aseptic pulse band.
- Take off gloves, wear sterile isolation clothes, and re-wear sterile powder-free gloves.
- Paving towels and preparing sterile articles.
- Paving treatment towel, cave towel and sterile large sheet only exposes the puncture site, covering the patient's whole body and puncture side arm.
- Assistants (wearing round caps and masks) deliver syringes, PICC puncture kits, intubation sheaths and B-mode ultrasound kits to sterile areas according to aseptic principles.
- Place aseptic probe cover: Apply a little coupling agent on the control head, cover the probe with aseptic cover, no air bubbles between the cover and probe, and fix firmly with rubber ring (operator should keep the gloves aseptic).
- Strip aseptic tourniquet.
- Apply a little sterile coupling agent to the attachment of the puncture point.
- Before puncture, the vascular ultrasound guidance system was used to re-locate the vessels, and the selected vascular images were fixed in the central position of the marker points, the probe was fixed in the left hand, and the probe position was kept perpendicular to the skin.

Note: During the whole exploration and operation, the probe and skin must be kept at a vertical angle of 90 degrees.

- Local anesthesia was performed at the puncture point and intradermal injection of 2% lidocaine was performed.
- Puncture needle was taken from the right hand. The needle tip was obliquely upward (i.e. to the side of the probe) for venipuncture. A white bright spot in the blood vessel or the route of puncture could be seen on the ultrasound display screen. Blood flowed slowly from the tail of the needle, that is, the puncture needle had entered the blood vessel.
- **Guiding wire:** After successful puncture, the fixed puncture needle remains motionless and the probe is moved carefully. The puncture needle was fixed in the left hand, and the guide wire was inserted into the puncture needle in the right hand. After the guide

wire was inserted into the blood vessel, the puncture angle was lowered, the guide wire was pushed forward and the tourniquet was loosened in the right hand. *In vitro*, the guide wire was retained for 10 cm to 15 cm. Note: Always see the end of the guide wire *in vitro*. The guide wire should not be pushed vigorously in case of resistance. If the guide wire is unsuccessful, the guide wire and the puncture needle must be pulled out together to avoid the broken catheter caused by the cutting of the guide wire by the puncture needle tip.

- Remove the puncture needle and retain the guide wire *in situ*.
- Anesthesia can be further given around the puncture point.
- Enlarged puncture point: The scalpel cuts the skin parallel to the guide wire above the guide wire in order to enlarge the puncture site, and pay attention not to cut the guide wire.
- Put the guide wire into the intubator along the guide wire, pay attention to fixing the guide wire, avoid the guide wire sliding into the vein, push the intubator into the same direction of blood vessels, while rotating the intubator, push forward continuously, so that the intubator fully into the blood vessels.
- Unlock the lock on the intubator, separate the dilator and the intubation sheath, press the front end of the intubation sheath with the index finger and middle finger of the left hand to stop bleeding, pull out the dilator and the guide wire with the right hand (pay attention to ensuring that the intubation sheath does not shift), and then block the sheath with the thumb of the left hand.
- Catheter insertion: Fixed the intubation sheath, put sterile gauze under the intubation sheath, and insert the catheter slowly, short distance and uniformly from the intubation sheath.
- Withdrawal of intubation sheath: After intubation to a predetermined length, the end of the sheath is compressed to stop bleeding and fix the catheter. The intubation sheath is withdrawn from the blood vessel to keep it away from the puncture and tear the intubation sheath.
- Withdraw the support guide wire in the catheter: After calibrating the length of the catheter, separate the catheter from the metal handle of the support guide wire, gently press the puncture point to maintain the position of the catheter, and slowly and straightly withdraw the support guide wire.
- Cut the length of the catheter: After cleaning the blood stain on the catheter with normal saline, trim the catheter, keep the external catheter for 5 cm, cut the catheter at right angle with sterile scissors and catheter, and pay attention not to cut out the inclined plane or ballast (even if the length of the catheter is less than 5 cm, the last 1 cm of the catheter must be cut off, otherwise the catheter and connector will not be fixed firmly).
- Install connectors: Install the decompression sleeve on the conduit, and then connect the conduit to the metal handle of the wing part of the connector. Be sure to push it to the end. The conduit cannot fold. Finally, align the inversion of the wing part with the groove on the decompression sleeve along the straight line and lock the two parts.
- Draw back blood and flush tube: Draw back blood, see return blood push back: then use 20 ml saline pulse mode to part tube, while injecting the last 0.5 ml saline, remove syringe while pushing the piston to achieve positive pressure sealing (saline dosage for adults is 20 ml, children is 6 ml).
- Install a heparin cap or positive pressure joint, remove the hole towel (keep the operator's gloves and field sterile), and clean the puncture point and blood stains on the surrounding skin.
- Fixed catheter: It is advisable for patients to feel comfortable and free from twists and turns in their daily activities.
- Tidy up the objects and place the patient in the position.
- Indicate the name of the puncturer, the date and time of puncture, and dress with elastic bandage as needed.
- Tripartite verification is conducted again to explain the matters needing attention to the patients.
- X-ray examination confirmed the position of the tip of the catheter.
- Seven-step hand washing.
- Record the PICC puncture records, register the product information, fill in the PICC Nursing Manual, and give the patient proper custody.

Ethical and regulatory oversight

Because the purpose of the Hospital Medicine Safety Consortium is to measure and improve the quality of existing care practices, the project has received a "Not Regulated" status by the University of Michigan Medical School's Institutional Review Board.

Results and Discussions

Catheter-related venous TE can be asymptomatic or can result in severe complications such as deep vein thrombosis, portal vein thrombosis, Budd Chiari, superior vena cava syndrome, intracardiac thrombosis, or pulmonary embolism [13]. Clinical manifestations of symptomatic catheter-related thrombosis in neonates depend on the site of the thrombosis. Catheter dysfunction, thrombocytopenia or persistent bacteremia/fungemia may be associated with vascular thrombosis at any site [2,14]. Apart from the loss of venous access owing to catheter related thrombosis, there is potential danger of injury to vital organs secondary to thrombus propagation, embolization, or infection. There are accepted guidelines to ensure safe placement and positioning of PICCs [15]. Increased complication rates have been documented with non central PICC tips; factors such as small vessel size, decreased blood flow rate, turbulent flow, and endothelial injury are thought to be causative [16-18]. Ideal procedure to place a PICC involves manipulating the catheter centrally, with the goal being a final tip position in the Superior Vena Cava (SVC) if placed from the head, neck or upper extremity and at junction of the Inferior Vena Cava (IVC) and right atrium when placed from the lower extremity [19]. Thus, the tip of an LL catheter should be at or above the level of the diaphragm. Importantly however, initial thrombus formation has been documented to occur within days of catheter insertion, therefore, even in higher flow areas, thrombosis may develop [20]. The incidence of VTE in the newborn depends on the zeal with which surveillance is performed, the timing and frequency of monitoring, and the diagnostic method used [2,21,22]. Assessment for VTE is variable and controversial: Use of clinical signs alone, plain XR, ultrasound or venography. Most authors do recommend periodic verification that the PICC tip is central to ensure repositioning occurs prior to the development of complications [23,24]. There are several limitations of the current study. This is a retrospective, descriptive

study and therefore it is vulnerable to bias. The true incidence of VTE is unknown as there was no routine monitoring in the patient population. Line tip position was also not regularly monitored, so it is difficult to know how much line position contributed to the development of VTE; migration may have occurred gradually or close in time to the identification of the thrombosis. Furthermore, bladder pressure monitoring is not routinely performed on infants at risk for intra-abdominal hypertension, making the diagnosis more reliant on the clinical assessment of abdominal pressure and clinical assessment is recognized to not be highly accurate [25].

Infants with abdominal surgical pathology who have LL PICCs placed during their NICU stay were at risk for major complications related to VTE in our study population. No major symptomatic VTEs were identified in any patient without abdominal pathology. Given that all the PICCs associated with a VTE were LL and non-central, routine monitoring of PICC tip position is recommended in this high risk population. With recognition of the multiple risk factors which predispose this group of complex neonates to major morbidity secondary to venous thromboembolism, even in the context of a well-positioned PICC tip, a vigilant approach is warranted. Further studies are required to more fully understand the risk of PICC associated VTE in infants with intra-abdominal pathology. PICCs are widely used in cancer patients and catheter migration is one of the uncommon complications [26,27]. Catheter migration usually occurs in a few days or months after catheterization, accompanied with catheter plugging, changing in drip speed, swelling on catheterized arm or neck pain and headache after infusion, and it was diagnosed by X-ray [28,29]. It is also associated with changing in intrathoracic pressure, occurrence of congestive heart failure, activity of upper limb or neck, positive pressure ventilation, high pressure injection, or catheter care technique. The first catheter migration was found by changing in infusion speed associated with the change of body position. The second catheter migration was found by headache complained by patient himself. He also complained of severe gastrointestinal reaction, frequently nausea, vomiting, and sneezes after chemotherapy. These all could cause the change of intrathoracic pressure [30]. The lumen of SVC is wide, and its flow speed is fast. However, PICC is light and soft, which is floating in the vessel. The entrance of SVC is located at strong counterforce between the left brachiocephalic vein wall and the vortical flow. When the patient coughed and vomited, it would cause strong contraction in diaphragm, abdominal and chest wall muscle. The volume and pressure of thoracic cavity were altered along with changing of central venous pressure and blood flow. Repeated altered blood flow also increased the probability of catheter migration. Catheter malposition is a major risk factor for PICC related venous thrombosis [17,18,20]. Development of internal jugular vein thrombosis is related to the migration of catheter into jugular vein. After PICC migrates to the internal jugular vein, because the direction of liquid medicine flow from catheter is opposite to venous return, and the medicine stays too long in partial vein will damage the intima and exposure vascular endothelial, platelet aggregation results in thrombosis. When the catheter tip migrates to the vein outside the SVC, due to diameter of other vascular lumen is smaller and it has less blood flow, the hemodynamics will be slow, the contact time of hypertonic liquid or chemotherapeutic drugs with intima extends, blood vessel wall damages, eventually leading to thrombosis [31].

Case Presentation

A three-day-old premature female infant born by emergent caesarean section at an outside institution was transferred to our NICU for evaluation of decreased lower extremity movement after insertion of a PICC line. The infant was born at 28 weeks due to maternal preeclampsia and decreased fetal movement. Her Apgar scores were six and nine. After birth, an umbilical artery catheter was placed. A PICC line was then placed in the left leg on Day of Life (DOL) one (Figure 1). After line placement, the infant exhibited minimal movement bilaterally in the lower extremities. Multiple imaging studies including an echocardiogram, a cranial ultrasound and plain film X-rays to evaluate line placement were performed on DOL two in an attempt to elucidate the etiology of this new onset of weakness. The PICC line was found to be malposition likely tracking into one of the lumbar veins. It was, therefore, removed on DOL three. Subsequent ultrasound demonstrated air within the spinal canal. A PICC line was placed in the right arm for IV access and the infant was transferred to our facility (Figure 2).

Figure 1: Supine abdominal radiograph, demonstrating the left femoral PICC line terminating possibly in a left lumbar vein (Arrow).

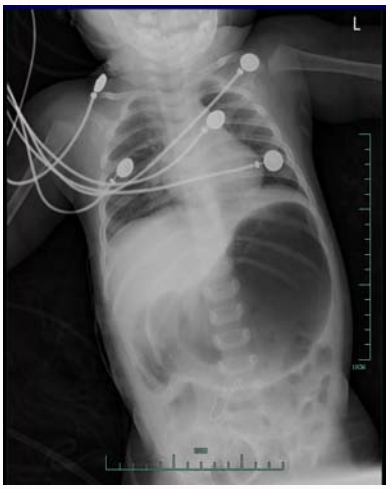

Figure 2: Chest X-ray demonstrating catheter tip migrated to the right internal jugular vein (white arrows).
PICC: Peripherally Inserted Central venous Catheter

Study Limitations

First, this is an observational study limited to general medical patients in non-ICU settings. Our findings are thus subject to confounding from unmeasured variables and limitations in external validity. Second, data regarding peripherally inserted central catheter

characteristics and care practices were not collected; thus, whether or how such elements influence the risk of venous thromboembolism is not known. Third, we defined peripherally inserted central catheter exposure as patients who were admitted with peripherally inserted central catheters and patients who received such devices during hospitalization. Although these represent clinically disparate populations, we adjusted for comorbidities and hospitalization before the index stay to account for confounding from preexisting illness.

Conclusion

In conclusion, the correct position of the catheter tip can ensure the normal use of PICC and reduce the complications. In clinical practice, we should pay more attention to the condition of PICC usage and listen to the patient's complaint carefully. For the migrated catheter, it should be removed as soon as possible, and when thrombosis has been developed, standard anticoagulant therapy should be given. Future studies that better define mechanisms for this association seem necessary. In the interim, mindful weighing of the thrombotic risks of peripherally inserted central catheters against their clinical benefits would be welcomed.

References

1. Subramanian S, Moe D C, Vo JN. Ultrasound-guided tunneled lower extremity peripherally inserted central catheter placement in infants. J Vasc Interv Radiol. 2013;24(12):1910-3.
2. Kisa P, Ting J, Callejas A. Major thrombotic complications with lower limb PICCs in surgical neonates. J Pediatr Surg. 2015;50(5):786-9.
3. Doellman D. Pediatric PICC insertions: Easing the fears in infants and children. J Vasc Access. 2004;9(2):68-71.
4. Bernasconi F, Zanaboni C, Dato A. Atypical use of picc in infants and small children: A unicentric experience. J Vasc Access. 2017;18(6):535-9.
5. Wrightson Daugherty D. Peripherally inserted central catheter complications in neonates with upper versus lower extremity insertion sites. Adv Neonatal Care. 2013;13(3):198-204.
6. KP, SS, DG. Picc Placement optimization in children with cancer[J/OL]. Am J Infect Control. 2011;39(5):E153.
7. Lawson BT, Zealley IA. Adult 'PICC' device may be used as a tunnelled central venous catheter in children. Cardiovasc Intervent Radiol. 2018;41(4):645-52.
8. Costa P, Kimura AF, Brandon DH. Predictors of nonelective removal of peripherally inserted central catheters in infants. Biol Res Nurs. 2016;18(2):173-80.
9. Payne R, Sieg EP, Choudhary A. Pneumorrhachis resulting in transient paresis after PICC line insertion into the ascending lumbar vein. Cureus. 2016;8(10):e833.
10. AA, RSB, LE. Central venous catheter-related tachycardia in the newborn: Case report and literature review[J/OL]. Case Rep Med. 2016;2016.
11. Lavandosky G, Gomez R, Montes J. Potentially lethal misplacement of femoral central venous catheters. Crit Care Med. 1996;24(5):893-6.
12. Moureau N, Gabriel J. Peripherally inserted central catheters. Central Venous Catheters. 2009:114-26.
13. MLL. Catheter-related thrombosis: Risks, diagnosis, and management[J/OL]. JNCCN. 2006;4(9):889-901.
14. Salonvaara M, Riikonen P, Kekomäki R. Clinically symptomatic central venous catheter-related deep venous thrombosis in newborns. Acta Paediatr. 1999;88(6):642-6.
15. Kelly L. A Practical guide to safe PICC placement. Br J Nurs. 2013;22(8):S13-4, S16, S18-9.
16. Jumani K, Advani S, Reich NG. Risk factors for peripherally inserted central venous catheter complications in children. JAMA Pediatr. 2013;167(5):429-35.
17. Lobo BL, Vaidean G, Broyles J. Risk of venous thromboembolism in hospitalized patients with peripherally inserted central catheters. J Hosp Med. 2009;4(7):417-22.
18. Latham GJ, Thompson DR. Thrombotic complications in children from short-term percutaneous central venous catheters: What can we do? Paediatr Anaesth. 2014;24(9):902-11.
19. Konstantinou EA, Mariolis Sapsakos TD, Katsoulas TA. Persistent left superior vena cava leads to catheter malposition during PICC port placement. J Vasc Access. 2016;17(2):e29-31.
20. VZ, NJ, IU. Peripherally Inserted Central Catheter (PICC)-related thrombosis in critically ill patients[J/OL]. J Vasc Access. 2014;15(5):329-37.
21. Chopra V, Ratz D, Kuhn L. PICC-Associated bloodstream infections: Prevalence, patterns, and predictors. Am J Med. 2014;127(4):319-28.
22. Oleti T, Jeeva Sankar M, Thukral A. Does ultrasound guidance for Peripherally Inserted Central Catheter (PICC) insertion reduce the incidence of tip malposition? A Randomized Trial. J Perinatol. 2019;39(1):95-101.
23. Qing XA, Sun J, Hui ZL. Effectiveness of intracavitary electrocardiogram-guided peripherally inserted central catheter tip placement in premature infants: A multicentre pre-post intervention study. Eur J Pediatr. 2020;179(3):439-46.
24. Glauser F, Breault S, Rigamonti F. Tip malposition of peripherally inserted central catheters: A prospective randomized controlled trial to compare bedside insertion to fluoroscopically guided placement. Eur Radiol. 2017;27(7):2843-9.
25. Li X, Ding X, Shi P. Clinical features and antimicrobial susceptibility profiles of culture-proven neonatal sepsis in a tertiary children's hospital, 2013 to 2017. Medicine (United States). 2019;98(12).
26. Song X, Lu H, Chen F. A Longitudinal observational retrospective study on risk factors and predictive model of PICC associated thrombosis in cancer patients. Scientific Rep. 2020;10(1).
27. Mielke D, Wittig A, Teichgräber U. Peripherally Inserted Central Venous Catheter (PICC) in outpatient and inpatient oncological treatment. Support Care Cancer. 2020;28(10):4753-60.
28. Baciarello M, Maspero G, Maestroni U. X(-Rays) Sometimes mark the spot: A case of occult central venous catheter embolization. J Vasc Access. 2020;21(5):795-8.
29. Acun C, Baker A, Brown LS. Peripherally inserted central cathether migration in neonates: Incidence, timing and risk factors. J Neonatal Perinatal Med. 2021;14(3):411-7.
30. Wang K, Sun W, Shi X. Upper extremity deep vein thrombosis after migration of Peripherally Inserted Central Catheter (PICC). Medicine (United States). 2017;96(51).
31. Yi XL, Chen J, Li J. Risk factors associated with PICC-related upper extremity venous thrombosis in cancer patients. J Clin Nurs. 2014;23(5-6):837-43.