Annals of Clinical Case Reports

Case Report
Published: 10 Feb, 2023

Robot-Assisted Repair of a Traumatic Hernia after a Pelvic Fracture: Case Report and Literature Review

De Troyer A, Allaeys M and Berrevoet F*

Department of General and HPB Surgery and Liver Transplantation, Ghent University Hospital, Belgium

Abstract

Traumatic Abdominal Wall Hernias (TAWH) are an uncommon clinical entity, accounting for less than 0.2% of all blunt trauma injuries. Due to its low incidence and high risk for associated injuries there is no consensus on their management and best method of repair. We report a case of a 46-year-old male with a delayed presentation of a traumatic hernia through a defect of the left iliac wing. To our knowledge, we describe the first robot-assisted transabdominal preperitoneal repair of a traumatic hernia with a pelvic fracture. We present our operative approach and an overview of the literature.

Introduction

Traumatic Abdominal Wall Hernia (TAWH) is an uncommon clinical entity, accounting for less than 0.2% of all blunt trauma injuries [1]. Management and operative technique are still a matter of debate and the role of the robotic surgical platform in these patients has not been reported on. We present a robot-assisted repair of a rare TAWH through a fracture of the left iliac wing. Our operative technique and review of the literature is described.

Case Presentation

A 46-year-old male with a history of a high energetic trauma presented at our department with a symptomatic swelling in the left lumbar region. He was involved in a traffic accident four years ago, suffering from multiple organ injuries and a fracture of the left iliac wing that were all treated conservatively. At time of presentation, he had an abdominal wall protrusion in the left lumbar region. He complained of decreased abdominal muscle strength with chronic discomfort during Valsalva maneuvers. A previous CT scan showed an important defect of the abdominal wall caused by a disruption of the iliac and gluteus muscles and non-union of the left iliac wing fracture. This caused a herniation of the descending colon through this bony defect of the left iliac wing (Figure 1). There were no signs of strangulation or incarceration. An elective operative management was scheduled.

A robot-assisted Transabdominal Preperitoneal hernia repair (TAPP) using the da Vinci Xi® (Intuitive Surgical, Sunnyville, CA, USA) robotic system was planned. The patient was positioned in right lateral decubitus. Pneumoperitoneum was established through an open 10 mm trocar introduction in the left paraumbilical position. Two additional 8 mm trocars were placed on the left pararectal side, with all 3 trocars on the same vertical line. Exploration confirmed a herniation of the descending colon through the bony defect (3 cm in transverse length and 5 cm in longitudinal length) of the left iliac wing (Figure 2). The content of the hernia was reduced after mobilization of the sigmoid. Subsequently a vertical incision was made in the peritoneum lateral to the left semilunar line to enter the preperitoneal space. The dissection was extended from preperitoneal to retroperitoneal with the medial edge of the psoas muscle as safety landmark that allowed us to avoid injuries to retroperitoneal structures, such as ureters, blood vessels, and nerves. We carefully preserved the entire hernia sac to ensure adequate tissue coverage of the mesh. Since the hernia was entirely bounded by bony structures, primary fascial hernia defect closure was unattainable. Therefore, we inserted a synthetic (20 by 20 cm) small pore polypropylene mesh (Bard mesh™, C.R. Bard, Inc., Covington, GA) in the created pocket. The mesh was positioned as such that the central part of the mesh covered the hernia defect (Figure 3). The mesh was fixed with absorbable Vicryl 2-0 (Ethicon, Inc., Somerville, NJ) sutures and fibrin glue (Tisseel® Baxter Corp., Deerfield, IL) onto the bone and the border of the psoas (Figure 3). We avoided mesh fixation with sutures, tackers or bone anchors in the iliac and psoas region to reduce the risk of chronic postoperative pain. The peritoneal sac was plicated at its base using a running absorbable suture (V-Loc®, Covidien, Mansfield,

OPEN ACCESS

Correspondence:
Annabelle De Troyer, Department of General and HPB Surgery and Liver Transplantation, Ghent University Hospital, Ghent, Belgium, Tel: +32 499 20 66,
E-mail: Annabelle.detroyer@ugent.be

Received Date: *12 Jan 2023*
Accepted Date*: 06 Feb 2023*
Published Date*: 10 Feb 2023*

Citation:
De Troyer A, Allaeys M, Berrevoet F. Robot-Assisted Repair of a Traumatic Hernia after a Pelvic Fracture: Case Report and Literature Review. Ann Clin Case Rep. 2023; 8: 2392.
ISSN: 2474-1655*.*

Copyright *© 2023 De Troyer A. This is an open access article distributed under the Creative Commons Attribution License, which permits unrestricted use, distribution, and reproduction in any medium, provided the original work is properly cited.*

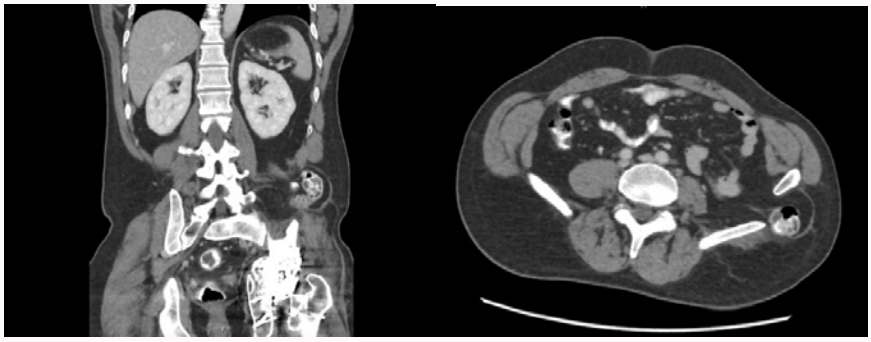

Figure 1: Coronal (left) and axial (right) CT view of the traumatic hernia.

Figure 2: Traumatic hernia.

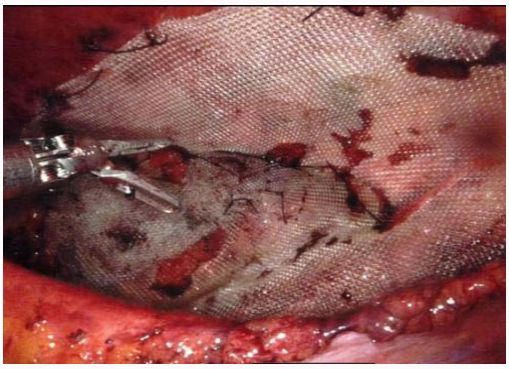

Figure 3: Mesh placement and fixation.

MA, USA). The postoperative course was uneventful, and the patient was discharged one day after surgery. At follow-up the patient showed no chronic pain or signs of recurrence. Clinical bulging was minimal. The follow-up period up to now is 6 months.

Discussion

TAWH is a rare and often difficult diagnosis in the trauma setting. Due to its low incidence and high risk for associated injuries there is no consensus on the management. The mechanism of injury following blunt trauma consists of a disruption or weakness of the underlying abdominal wall musculature or fascia with secondary herniation [1]. TAWH at the level of an associated pelvic fracture has been scarcely described in the literature. We report a case of a delayed presentation of a symptomatic large bowel herniation through a traumatic hernia defect of the left iliac wing, treated by mesh repair with the robotic platform.

Traditional management methods of TAWH focus on early exploration and hernia repair due to the high risk for concomitant intra-abdominal injuries [2]. With a reported incidence ranging from 18% to 60% of intra-abdominal and bowel injury, patients diagnosed with a TAWH are often referred for early exploration and hernia repair [3-5]. Considering the risk for contaminated field in the trauma setting, these patients are more likely to have a primary tissue repair instead of mesh repair. Data available from small case series show higher recurrence rates in TAWH after primary suture compared to a delayed mesh repair, respectively 26% to 50% and 8% [1,3-6]. Honaker et al. and Netto et al. note a decreased recurrence and complication rate in delayed mesh repairs [3,4]. However, in a large-scale multicenter retrospective study from Harrell et al. in 2021, there is no significant difference in hernia recurrence or surgical site infection between early and late hernia repair [7]. In the absence of hemodynamic instability or peritonitis, patients may safely be observed and referred for delayed hernia surgery [8].

Various methods for the repair of hernia defects in TAWH have been described. These include primary closure with non-absorbable monofilament sutures, fasciocutaneous flap reconstruction, bioprosthetic or prosthetic mesh repair [1,7]. The decision depends on clinical situation at the time of diagnosis, patient comorbidities, size, and location of the hernia defect. Without signs of gross contamination or bowel perforation, hernia repair with synthetic mesh is feasible in the acute setting. In the presence of peritonitis biologic meshes can be used or, alternatively, the patient can be referred for a delayed mesh repair. As we describe in our patient report, we performed a delayed elective mesh repair after a delay in diagnosis. The decision to perform surgery was based on the patients' symptoms of discomfort and the risk for incarceration/strangulation because of the presence of bowel herniation.

Location of the hernia defect matters in the decision-making process of the ideal method for repair. The atypical location through a non-union of the left iliac wing made fascial closure of this hernia defect impossible. To provide sufficient strength we used a small pore heavyweight polypropylene mesh (Marlex, C.R. Bard, Inc., Covington, GA) and provided extensive mesh overlap through a large preperitoneal dissection. In the literature, there is lack of evidence about the best surgical method to close this bony defect. Only two case reports by Delaune et al. and Moon et al. provide their surgical technique for the repair of an interfragmentary hernia through the iliac wing [9,10]. Moon et al. describes a repair with closure of the bony defect using two fibular strut allografts [9]. Delaune et al. uses a prosthetic monofilament polypropylene mesh, fixed from the iliac

crest to the subinguinal hiatus and to the anterior space of the left kidney [10]. However, no conclusive information about follow-up and outcomes are available.

Considering the surgical approach, there is no formal comparison between open, laparoscopic, and robotic approach in traumatic abdominal wall surgery. The open approach is most frequently used in both early and delayed repairs. Harrell et al. states that more than 90% of early repairs are performed open, compared with 68% of late repairs. The minority of reported TAWH are managed laparoscopic or robotic, respectively 7% and 0% for early repairs and 21% and 15% of late repairs [7]. In the last ten years, there is a tendency to perform abdominal wall surgery with minimal-invasive techniques to achieve less morbidity. Subsequent, there is also growing interest to manage TAWH in a delayed state with minimal-invasive techniques. Novitsky et al. describes the largest series of 14 patients who underwent laparoscopic mesh repair of traumatic flank hernias in an elective setting. No complications or recurrences occurred after an acceptable mean follow-up period of 35 months [11]. The literature concerning robotic repair in traumatic lateral hernia is still scarce. Only 2 retrospective case series report on 4 patients who had a delayed repair of lumbar traumatic hernia [7,12]. However, in both studies surgical procedural details are limited and no comparison has been made between the outcomes of robotic *vs.* open or laparoscopic technique. Wijerathne et al. reports a robotic TAPP procedure in a lumbar traumatic hernia. The authors recommend to perform a robotic repair if the hernia defect is larger than 4 to 5 cm to facilitate an extensive dissection and adequate mesh coverage in the lumbar region [12], especially when there is lack of adequate tissue to close the fascial defect and in the proximity of important neurovascular structures, as presented in our patient case. We believe that, in an elective setting, the robotic platform facilitates dissection and adequate mesh placement in the lumbar region. Furthermore, compared to the laparoscopic approach, it provides better ergonomics and less technical difficulties, particularly in lateral abdominal wall hernia surgery [13].

The available literature has several limitations, most importantly the small population and short-term follow-up duration. There is no conclusive evidence to support one operative method of repair over the other in TAWH surgery. Robotic repair has proven some evidence for feasibility in small case studies and is of growing interest. We found our robot-assisted approach to be safe and feasible for the management of this rare and challenging TAWH.

Conclusion

TAWH is rare and the management is still a matter of debate. There is a tendency towards mesh repair in a delayed setting with minimal invasive techniques. In difficult to reach areas of the abdomen, a robot-assisted repair of TAWH might be a valid approach. Larger studies are needed to confirm our initial experience in traumatic hernia surgery.

References

1. Chow KL, Omi EC, Santaniello J, Lee JK, Mcelmeel DP, Thomas YM, et al. Traumatic abdominal wall hernias: A single-center case series of surgical management. Trauma Surg Acute Care Open. 2020;5(1):e000495.
2. Liasis L, Tierris I, Lazarioti F, Clark CC, Papaconstantinou HT. Traumatic abdominal wall hernia: Is the treatment strategy a real problem? J Trauma Acute Care Surg. 2013;74(4):1156-62.
3. Honaker D, Green J. Blunt traumatic abdominal wall hernias: Associated injuries and optimal timing and method of repair. J Trauma Acute Care Surg. 2014;77(5):701-4.
4. Netto FACS, Hamilton P, Rizoli SB, Nascimento B, Brenneman FD, Tien H, et al. Traumatic abdominal wall hernia: Epidemiology and clinical implications. J Trauma. 2006;61(5):1058-61.
5. Coleman JJ, Fitz EK, Zarzaur BL, Steenburg SD, Brewer BL, Reed RL, et al. Traumatic abdominal wall hernias: Location matters. J Trauma Acute Care Surg. 2016;80(3):390-6.
6. Pardhan A, Mazahir S, Rao S, Weber D. Blunt traumatic abdominal wall hernias: A surgeon's dilemma. World J Surg. 2016;40(1):231-5.
7. Harrell KN, Grimes AD, Albrecht RM, Reynolds JK, Ueland WR, Sciarretta JD, et al. Management of blunt traumatic abdominal wall hernias: A Western Trauma Association multicenter study. J Trauma Acute Care Surg. 2021;91(5):834-40.
8. Ferris M, Pirko C, Nottingham J. Delayed laparoscopic repair of a traumatic flank hernia: A case report and review of the literature. Int J Surg Case Rep. 2018;51:372-5.
9. Moon CH, Lee G, Judd D, Johnson E, Morrison CA. Hernia development after traumatic injury to the pelvic ilium: Case report and novel approach to repair. J Trauma. 2008;65(1):231-3.
10. Delaune L, Steinmetz S, Heutschi-Öztürk H, Borens O. Traumatic abdominal wall hernias: disruptions of the abdominal wall muscles associated to pelvic bone fractures illustrated by two case reports. BMC Surg. 2020;20(1).
11. Novitsky YW. Laparoscopic repair of traumatic flank hernias. Hernia. 2018;22(2):363-9.
12. Wijerathne S, Malik S, Usmani F, Lomanto D. Minimally invasive repair for lateral ventral hernia: Tailored approach from a hernia centre at a tertiary care institution. Hernia. 2021;25(2):399-410.
13. Moreno-Egea A, Carrillo-Alcaraz A. Management of non-midline incisional hernia by the laparoscopic approach: Results of a long-term follow-up prospective study. Surg Endosc. 2012;26(4):1069-78.