Annals of Clinical Case Reports

Case Report
Published: 04 Oct, 2021

Pulmonary Thromboembolism Complicated with *Mycobacterium tuberculosis* Infection: A Case Report and Literature Review

Qiuyue Feng[1,2] and Zhaohui Tong[1]*

[1]*Department of Respiratory and Critical Care Medicine, Capital Medical University, China*

[2]*Beijing Huairou Hospital, China*

Abstract

Tuberculosis (TB) has a high prevalence and remains a worldwide health crisis especially in developing countries. Geriatric TB is a difficult problem in the course of diagnosis and treatment, and Pulmonary Thromboembolism (PTE) caused by *Mycobacterium tuberculosis* infection is rarely reported. An 85-year-old man with fever was hospitalized because of PTE and pneumonia; no one considered that he might be pulmonary tuberculosis. Particularly, one super-aged man manifested atypical symptoms during treatment in the emergency room. After routine anti-TB regimen and anticoagulation therapy, the patient was recovered and discharged. We should be alert to pulmonary embolism that complicated active tuberculosis in the geriatric population, early diagnosis and treatment can improve survival rate.

Keywords: Tuberculosis; PTE; Geriatric population; ATT

OPEN ACCESS

Correspondence:
Zhaohui Tong, Department of Respiratory and Critical Care Medicine, Capital Medical University, Beijing Institute of Respiratory Medicine, Beijing Chao Yang Hospital, NO. 8 GongTi South Road, Chaoyang District, Beijing, 100020, China, Tel: +86-13910930309;
E-mail: tongzhaohuicy@sina.com

Received Date: *07 Sep 2021*
Accepted Date*: 21 Sep 2021*
Published Date*: 04 Oct 2021*

Citation:
Feng Q, Tong Z. Pulmonary Thromboembolism Complicated with Mycobacterium tuberculosis Infection: A Case Report and Literature Review. Ann Clin Case Rep. 2021; 6: 2019.
ISSN: 2474-1655

Abbreviations

TB: Tuberculosis; VTE: Venous Thromboembolism; PTE: Pulmonary Thromboembolism; DVT: Deep Vein Thrombosis; NOAC: Novel Oral Anticoagulant; CTPA: Computer Tomography Pulmonary Angiography; ATT: Anti-Tuberculosis Treatment; AFB: Acid Fast Bacilli; LMWH: Low Molecular-Weight Heparin; INR: International Normalized Ratio; MTB: Mycobacterium Tuberculosis; CT: Computed Tomography

Introduction

Tuberculosis is an ancient and serious infectious disease that remains a worldwide health crisis, especially in developing countries [1]. TB can occur at any age for an individual and the incidence of TB is found to be the highest in the age group of 20 to 24 of any birth cohort. With the aging of the population, TB in older people becomes a major clinical and public health challenge [2]. As a chronic infectious disease, patients with TB may be showing a higher risk of developing Venous Thrombus Embolism (VTE) [3,4]. The first report of an association between tuberculosis and pulmonary thromboembolism was in 1950 [5]. Venous thrombosis is a rare complication which has been reported in 1.5% to 3.4% of TB infections. The incidence of thromboembolism in patients diagnosed with tuberculosis is higher than that in the general population of approximately 0.1% [6]. A meta-analysis suggests that patients with active tuberculosis had a higher risk for PE (OR: 3.58; 95% CI 2.54-5.05) [7].

Case Presentation

An 85-year-old man with cerebral infarction presented to the emergency department with a 2-day history of fevers (with temperatures as high as 38.8°C), chill, headaches, shortness of breath, cough, yellow sticky sputum, fatigue, muscle pain on September 23rd, 2019. The patient's medical history was otherwise notable for hypertension, upper gastrointestinal hemorrhage and syncope. He was a current smoker and consumed alcohol for 60 years. Emergency test was notable for Hemoglobin (HGB) 97 g/L, Blood Urea Nitrogen (BUN) 12.89 mmol/L, Creatinine (Cr) 149 umol/L, Lactate Dehydrogenase (LDH) 769 U/L, Na+ 132.9 mmol/L (Table 1). The C-Reactive Protein (CRP) level was elevated at 109.5 mg/L. A chest Computed Tomography (CT) scan taken on September 23rd, 2019 was shown in Figure 1 (a). Vascular ultrasound revealed deep venous thrombosis of the lower extremity. The patient was treated with Lysine Acetylsalicylate, cefazoxime, ambroxol and Low

Table 1: Laboratory Data.

Variable	Reference Range, adults	Before Admission	Hospital Day 1	Discharge Day 1	Day 10	Day 30	Day 60	Month 8
Red blood cell (10^{12}/L)	4.3-5.8	3.05	2.77	2.57	2.91	2.71	2.74	3.11
Hematocrit (%)	40-50	29.6	25.4	23.6	27.7	25.8	24.8	27.8
Hemoglobin (g/L)	130-175	97	84	80	91	85	81	94
White-cell count (10^9/L) Differential count (%)	3.5-9.5	8.03	6.51	4.75	6.87	5.27	1.86	1.52
Neutrophils Lymphocytes	40-75 20-50	80 6.8	85.04 6.52	71.94 13.54	78.81 11.12	69.14 18.64	25.34 68.34	30.92 52.01
Monocytes	03-10	12.8	8.3	11.64	9.3	9.14	1.64	12.5
Eosinophils Basophils	0.4-8 0-1	0 0.4	0.04 0.2	1.3 1.71	0.4 0.4	2.8 0.4	3.24 1.64	2.6 2.01
Platelet (10^9/L) Fibrinogen (g/L)	125-350 2-4	295 5.12	315 3.7	328 4.04	402 3.31	358 3.98	270 2.46	194 2.6
P(s)	11-14	10.7	12.4	15.5	15.3	12	11.3	11.6
APTT (s) D-dimer (mg/L)	24-39 0-1	39.4 36.56	67.4 9.09	40.5 6.41	30.3 8.44	26.7 6.63	28.4 6.5	27.9 9.78
BUN (mmol/L)	3.2-7.1	12.89	7.46	6.23	2.85	4.67	8.58	10.29
Cr (umol/L) ALB (g/L)	58-110 35-50	149 32	103.6 21.6	82 24.1	80.39 27.3	69.2 29.18	70.75 27.24	94.9 32
LDH(U/L)	313-618	769	374.5	335.6		229.07	171.9	332.1
CRP (mg/L) Oxygenation Index	0-6	129.8 313	88.45 358	30.25			18.7	4.22
PaO_2 (mmHg)		68.9	104					
$PaCO_2$ (mmHg)		28.2	31.2					
T3 (nmol/L) T4 (nmol/L)	1.01-2.48 69.97-152.52		0.33 35.1	0.59 40.87				1.77 66.52
FT3 (pmol/L)	3.28-6.47		2.6	2.22				4.77
FT4 (pmol/L)	7.64-16.03		4	3.87				5.44
TSH (uIU/ml) CEA (ug/L)	0.56-5.91 0-5		45.37 5.2	>46.6 4.92		 5.1		>49.1 3.09
NSE (ng/mL)	0-16.3		19.38	13.52		13.26		16.12
CYFRA211 (ng/mL) ProGRP (pg/ml)	0.1-3.3 <65.7		8.85 68.02	5.23 78.49		8.03 78.97		3.4 84.42
Ferritin (ng/ml)	30-400		867.1					
BNP (pg/ml) Iron (umol/L)	0-100 8-32	 3.4	238 3.58				<5	102 16
K (mmol/L)	3.6-5	3.66	3	3.13	4.32	4.28	3.6	4.04
Na (mmol/L) Cl (mmol/L)	135-145 96-110	132.5 96.3	132 98.9	135.4 100.7	134 100	138 105	137 105	137.5 107
PCT (ng/ml)	0-0.5	0.61	0.449	0.139				

Molecular-Weight Heparin (LMWH) for 3 days, but still had a fever and dyspnea. Arterial blood gas analysis (ambient air) indicated: pH 7.49, PaO_2 65.9 mmHg, $PaCO_2$ 28.2 mmHg, SaO_2 93.2%, oxygenation index 313 mmHg. D-dimer was 36.56 mg/L; renal function was BUN 10.48 mmol/L, Cr 109 umol/L. Then, Computer Tomography Pulmonary Angiography (CTPA) confirmed PTE Figure 1(b). The patient was hospitalized.

On admission, physical examination: BMI 16.7kg/m^2, Temperature 38.7°C, pulse 86/min, blood pressure 118/72 mmHg, SpO_2 92%. Lung auscultation showed no rales. The auxiliary test was shown in Table 1. D-dimer was 13.17 mg/L. Thyroid function showed hypothyroidism. Levothyroxine sodium tablets were given to correct thyroid insufficiency. The patient was prescribed with Piperacillin Sulbactam sodium and fluoroquinolones for infections, LMWH (0.1 mL/10 kg) for anticoagulation after admission. But the patient still had a fever of 38.8°C. *Mycobacterium tuberculosis Bacillus* was detected by sputum AFB staining after 3 days. *Sputum* gene X-pert MTB/RIF assay was reported as 'MTB detected, rifampicin sensitive' on the 7th day. Routine ATT was initiated, including isoniazid (300 mg/day), rifampin (450 mg/day), pyrazinamide (750 mg/day) and ethambutol (750 mg/day). After three days, the body temperature returned to normal, and the shortness was relieved. Due to warfarin treatment requires recurrent review, the patient decided to take rivaroxaban. He was discharged after 2 weeks of hospitalization. He reviewed at the outpatient clinic regularly. The blood routine of the patient showed leukopenia 2 months later after discharge. CTPA showed no signs of pulmonary embolism but no improvement of pulmonary lesions Figure 1(c). Chest CT appeared the absorption of pneumonia after 8 months Figure 1(d). The ATT and rivaroxaban were discontinued. During treatment, the patient's symptoms relieved and laboratory tests, including D-dimer was improved significantly and BUN fluctuated with days, although the white-cell count decreased and the RBC count did not change Figure 2. He is still alive now.

Discussion

We performed a retrospective search of patients in the PubMed database, with "tuberculosis" and "pulmonary thromboembolism" as keywords. We screened the articles in English from 2000 to 2019, only 13 cases of tuberculosis complicated with pulmonary thromboembolism are reported totally, another 7 cases were reported as TB complicated with DVT. The average age was 35.10 ± 15.33 years

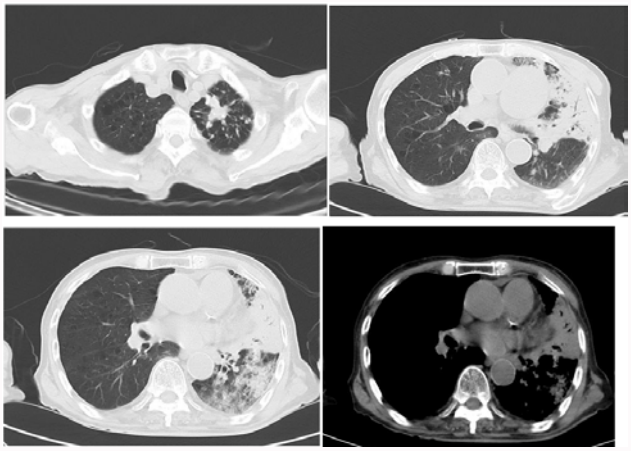

Figure 1a: Axial plane Chest CT (Sep 23rd, 2019) showing large patchy high-density shadow in the upper and lower lobes of the left lung, bilateral emphysema, dilation of the pulmonary artery, diameter 5.3 cm.

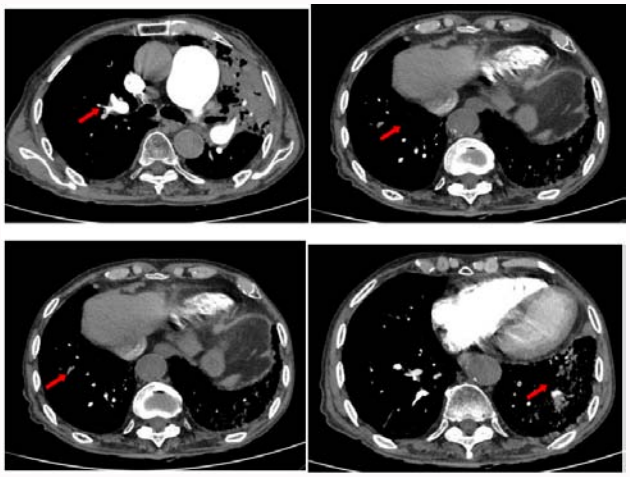

Figure 1b: PA (Sep 25th, 2019) demonstrated the presence of filling defects (red arrow) in the branches of the left lower pulmonary artery and branches of right pulmonary artery.

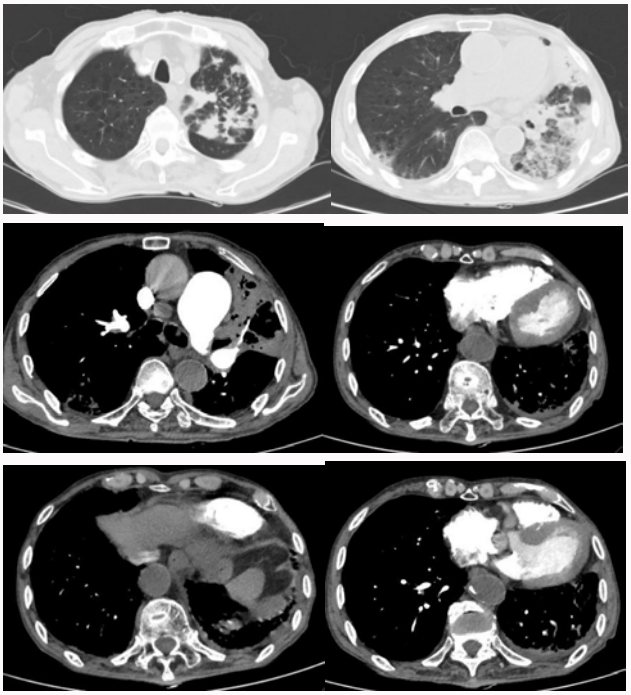

Figure 1c: CTPA (Nov 7th, 2019) showed no signs of pulmonary embolism and no improvement of pulmonary lesions.

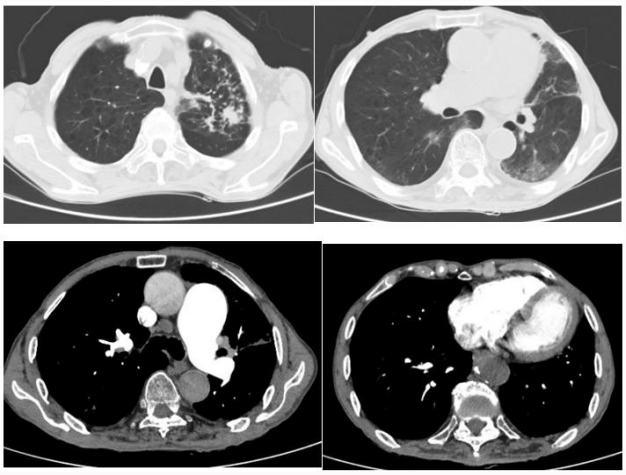

Figure 1d: CTPA (May 28th, 2020) showed no recurrence of pulmonary embolism and improvement of pulmonary lesions obviously.

old. Gender might be associated with DVT incidence in TB patients, 16 males and 4 females in this study, and our patient was also male. In these cases, there are 2 extrapulmonary TB cases (10%), none showed both pulmonary and extrapulmonary TB, the remaining 18 cases were severe pulmonary TB and one with tumor, of which, 13 cases were destruction of both lung lobes or complicated with multiple cavities; 3 cases had pleural effusion; 2 cases had military TB, 1 case had malignant mesothelioma of pleura. The majority of patients was in developing countries and had a longer disease history. These patients had dyspnea (75%), fever (45%), chest pain (45%) and hemoptysis (5%). Only one of the 20 patients with TB was positive for MDR-TB, and none had HIV. ECG showed typical $S_IQ_{III}T_{III}$ in 2 cases (10%). D-dimer was performed in 3 cases (15%). CTPA showed bilateral pulmonary thromboembolism in 6 cases (30%), right pulmonary artery embolization in 5 cases (25%), left pulmonary artery embolism in 1 case (5%). CT venography of chest and abdomen showed multiple deep vein thrombosis in 1 case (5%). In the course of anticoagulant therapy, 2 patients (10%) were adjusted warfarin due to the difficulty of acenocoumarol treatment, 1 patient stopped warfarin and only used LMWH due to difficulty in attaining target INR, and 1 patient was treated with dabigatran after discontinuation of warfarin. The remaining 18 patients all required large dose warfarin maintenance treatment range INR value, a high dose of acenocoumarol (8 mg day1) was needed to obtain a therapeutic INR. The development of VTE in all 20 patients was not coincident with the time of TB diagnosis, 12 patients developed DVT soon after TB diagnosed, and in 8 patients, the DVT event had preceded TB diagnosis.

In our report, the patient was the oldest among those mentioned above, 85-year-old. PTE which associated with TB was a rare occurrence, and very few cases have been reported in literature [8]. PTE can be the presenting feature of TB, occurring a few days after the diagnosis or late in the course of the disease [9]. In our study, the patient developed pulmonary embolism before TB diagnosed, but pulmonary embolism was still a complication of active tuberculosis. The prevalence of VTE among TB patients was 1.5% to 3.4% [10]. In

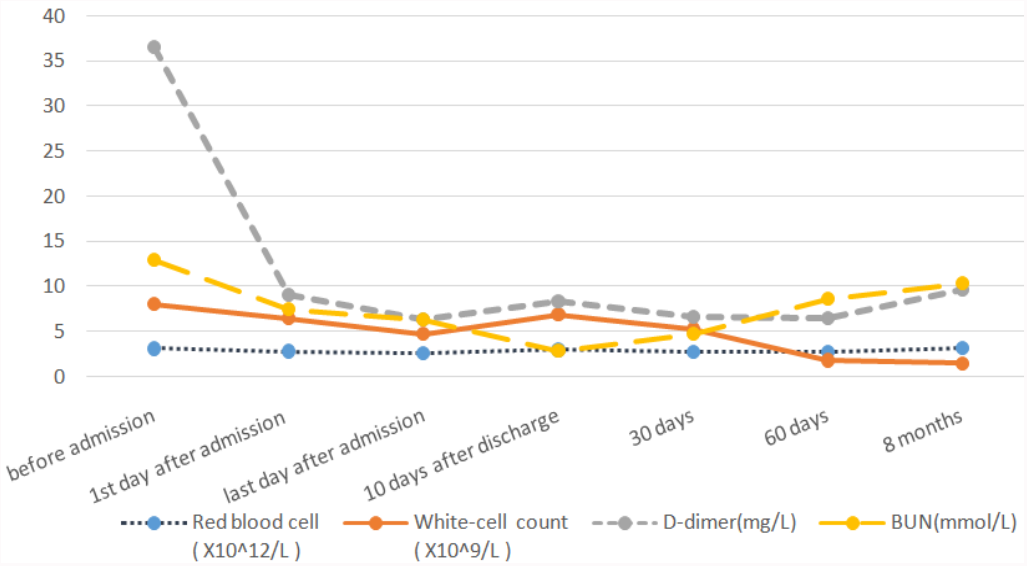

Figure 2: The level of D-dimer was improved significantly, and the BUN fluctuated, and the white-cell count decreased, and the RBC count did not change during the treatment.

a multivariate analysis model, adults with active TB had a greater risk of VTE than those without (P<0.001), close to the previously reported risk associated with neoplasia [11].

Severe TB can result in a hypercoagulable state and thromboembolic complications. TB, as a chronic inflammatory state, in the lung activates the coagulation cascade and leads to pulmonary and systemic thrombin generation [12,13], it intervenes all the three parts of Virchow's triad, may play a role in pathogenesis of the disease. The presence of a hypercoagulable state in TB patients was considered as a consequence of elevated plasma fibrinogen with impaired fibrinolysis, along with a decrease in factor III, protein C, increased platelet aggregation, and direct endothelial damage promoted by the mycobacterium tuberculosis [14,15]. White et al. also demonstrated a possible association between DVT in patients with pulmonary tuberculosis and the use of rifampicin with a relative risk of 4.74 in patients treated with rifampicin-containing regimens [8]. In addition, the hypercoagulable state persists for 2 weeks after the initiation of anti-tuberculosis medication and improves while continuing the treatment [4,16]. Our patient also chose rifampicin in the ATT regimen because it is used as a bactericidal agent and is often included in first-line anti-TB drug therapy. Rifampin not only increases the occurrence of thrombus, but also has a great influence on warfarin. The metabolism of warfarin increases in the presence of rifampicin, and the doses of warfarin sometimes have to be increased to more than double the recommended level [17,18]. During warfarin is added for treating thromboembolism, bleeding is common and sometimes fatal. Novel Oral Anticoagulant (NOAC) agents are ideal choice for control of PTE/DVT in patients receiving anti tuberculosis medication. Our patient chose rivaroxaban for the treatment of PTE. Finally, he discharged successfully.

In conclusion, active TB has been considered as a risk factor for PTE. Early initiation of anticoagulant therapy along with Anti Tuberculosis Treatment (ATT) can obtain the maximum benefit when contraindications are excluded.

Authors' Contributions

QYF conducted the literature review and wrote the draft. ZHT conceived the study and revised the manuscript. All authors have read and approved the manuscript.

References

1. Global tuberculosis report 2020. Geneva: World Health Organization; 2020. Licence: CC BY-NC-SA 3.0 IGO.
2. Yew WW, Yoshiyama T, Leung CC, Chan DP. Epidemiological, clinical and mechanistic perspectives of tuberculosis in older people. Respirology. 2018;23(6):567-75.
3. Gupta A, Dixit R. Pulmonary tuberculosis: A neglected risk factor for deep venous thrombosis. Int J Mycobacteriol. 2017;6(2):184-6.
4. Kager LM, Blok DC, Lede IO, Rahman W, Afroz R, Bresser P, et al. Pulmonary tuberculosis induces a systemic hypercoagulable state. J Infect. 2015;70(4):324-34.
5. Moran TJ. Autopsy Incidence Of Pulmonary Embolism In Tuberculosis. Dis Chest. 1950;18(2):171-3.
6. Silverstein MD, Heit JA, Mohr DN, Petterson TM, O'Fallon WM, Melton LJ 3rd. Trends in the incidence of deep vein thrombosis and pulmonary embolism: A 25-year population-based study. Arch Intern Med. 1998;158(6):585-93.
7. Danwang C, Bigna JJ, Awana AP, Nzalie RNT, Robert A. Global epidemiology of venous thromboembolism in people with active tuberculosis: A systematic review and meta-analysis. J Thromb Thrombolysis. 2021;51(2):502-12.
8. White NW. Venous thrombosis and rifampicin. Lancet. 1989;2(8660):434-5.
9. Gogna A, Pradhan GR, Sinha RS, Gupta B. Tuberculosis presenting as deep vein thrombosis. Postgrad Med J. 1999;75(880):104-5.
10. Azdaki N, Moezi S, Farzad M. Pulmonary tuberculosis: A differential diagnostic priority in unprovoked deep venous thrombosis patients with haemoptysis. Pan Afr Med J. 2018;29:57.
11. Gupta A, Mrigpuri P, Faye A, Bandyopadhyay D, Singla R. Pulmonary tuberculosis - An emerging risk factor for venous thromboembolism: A case series and review of literature. Lung India. 2017;34(1):65-9.
12. Mark PL, Ashok PP, Deshpande RB, Mahashur AA. A patient with hypercoagulable state due to tuberculosis. Indian J Chest Dis Allied Sci. 2009;51(1):49-51.

13. Schultz MJ, Millo J, Levi M, Hack CE, Weverling GJ, Garrard CS, et al. Local activation of coagulation and inhibition of fibrinolysis in the lung during ventilator associated pneumonia. Thorax. 2004;59(2):130-5.

14. Ambrosetti M, Ferrarese M, Codecasa LR, Besozzi G, Sarassi A, Viggiani P, et al. Incidence of venous thromboembolism in tuberculosis patients. Respiration. 2006;73(3):396.

15. El Fekih L, Oueslati I, Hassene H, Fenniche S, Belhabib D, Megdiche ML. Association deep veinous thrombosis with pulmonary tuberculosis. Tunis Med. 2009;87(5):328-9.

16. Turken O, Kunter E, Sezer M, Solmazgul E, Cerrahoglu K, Bozkanat E, et al. Hemostatic changes in active pulmonary tuberculosis. Int J Tuberc Lung Dis. 2002;6(10):927-32.

17. Lee CR, Thrasher KA. Difficulties in anticoagulation management during co-administration of warfarin and rifampin. Pharmacotherapy. 2001;21(10):1240-6.

18. Martins MAP, Reis AMM, Sales MF, Nobre V, Ribeiro DD, Rocha MOC, et al. Rifampicin-warfarin interaction leading to macroscopic hematuria: A case report and review of the literature. BMC Pharmacol Toxicol. 2013;14:27.