



Primary Retroperitoneal Extraskel-etal Mesenchymal Chondrosarcoma Involving the Colon: A Case Report and Literature Review

Jun Cheng¹, Zhijun He^{2,3}, Yining Li², Abira Afzal Choudhry⁴ and Youwen Deng^{1*}

¹Department of Spine Surgery, The Third Xiangya Hospital of Central South University, China

²Department of Liver Transplantation, The Second Xiangya Hospital, Central South University, China

³Department of Transplantation, Xiangya Hospital, Central South University, China

⁴Ziauddin University, Pakistan

Abstract

Background: Extraskel-etal Mesenchymal Chondrosarcoma (EMCS) is an extremely rare malignant tumor arising from soft tissues. It commonly occurs in the lower limbs, orbital cavity, and the central nervous system. Moreover, it is extremely rare for it to develop from a retroperitoneal location. In fact, there is no case about primary retroperitoneal ESMC involving the colon having been reported before.

Case Description: In the current study, we present a case about retroperitoneal extraskel-etal mesenchymal chondrosarcoma involving the colon in a 51 year old male patient, and discuss the major features of EMCS and make a review of the current knowledge about the rare tumor.

Conclusion: Primary retroperitoneal extraskel-etal mesenchymal chondrosarcoma is a very aggressive kind of chondrosarcomas, surgery is the primary treatment, which should be followed by adjuvant treatment, including chemotherapy and/or radiation therapy.

Keywords: Retroperitoneal; Extraskel-etal chondrosarcoma; Mesenchymal; Colon

OPEN ACCESS

*Correspondence:

Youwen Deng, Department of Spine Surgery, The Third Xiangya Hospital of Central South University, 138 Tongzipo Rd, Changsha, Hunan, 410013, China, E-mail: 314834962@qq.com

Received Date: 26 Jul 2021

Accepted Date: 06 Aug 2021

Published Date: 10 Aug 2021

Citation:

Cheng J, He Z, Li Y, Choudhry AA, Deng Y. Primary Retroperitoneal Extraskel-etal Mesenchymal Chondrosarcoma Involving the Colon: A Case Report and Literature Review. *Ann Clin Case Rep.* 2021; 6: 1962.

ISSN: 2474-1655

Copyright © 2021 Youwen Deng. This is an open access article distributed under the Creative Commons Attribution License, which permits unrestricted use, distribution, and reproduction in any medium, provided the original work is properly cited.

Abbreviations

EMCS: Extraskel-etal Mesenchymal Chondrosarcoma; CT: Computed Tomography; MRI: Magnetic Resonance Imaging

Background

Mesenchymal chondrosarcoma is a variant subtype of conventional chondrosarcomas, it is extremely rare and more aggressive, and it accounts for approximately 1% of all chondrosarcomas. It usually occurs in the bone, but around 30% to 40% of cases arise from extraskel-etal locations [1]. Extraskel-etal Mesenchymal Chondrosarcoma (EMCS) may occur in any location which contains mesenchymal cells, and it mainly arises in lower limbs, orbit and pia mater [2-4]. However, the retroperitoneum is extremely rare. To the best of our knowledge, there is no case about primary retroperitoneal ESMC involving the colon having been reported previously. In the study, we present a case of a 51-year-old male with primary retroperitoneal EMCS involving the colon, and discuss the major features of ESMC and make a review of the current knowledge about the rare tumor.

Case Presentation

A 51-year-old male admitted to the Third Xiangya Hospital, Central South University on December 05th, 2018 with a three-month history of left upper abdominal pain. The symptoms mainly presented as paroxysmal puffy pain in the upper abdomen, which got worse when he coughed or lay down, accompanied with a sense of distension in the left upper abdomen. The patient had no history of emesis, chest pain, fever, diarrhea and bloody stools, and the abdominal examination revealed left-upper abdominal tenderness and a hard lump with unclear boundary but not tenderness and rebound pain. The unenhanced transverse Computed Tomography (CT) scans revealed that a large mass (13 cm × 9.2 cm × 13 cm) was located in the left retroperitoneum. The tumor exhibited clear edge and multiple segmented areas with a large number of irregular calcification and patchy low-density areas (Figure 1A), while the left kidney was compressed and shifted (Figure 1C). The contrast-

Table 1: Characteristics of the retroperitoneal extra skeletal mesenchymal chondrosarcoma.

Author/Year	Sex	Age(years)	Treatment	Follow-up
D'Andrea G [12]	Female	25	Surgery	Follow up for 3.5 years and no recurrence and metastasis
Hu HJ [10]	Female	61	Surgery	NR
Fukuzawa M [13]	Male	9	Surgery and chemotherapy	Died of complications after 2 months
White DW [14]	Female	24	Chemotherapy and surgery	Died of recurrence on left humerus after 2.5 years
Guccion JG [15]	Male	61	Chemotherapy and radiotherapy	Died of lung metastasis after 2 years
Dhaliwal US [17]	Male	30	Biopsy, chemotherapy and radiotherapy	No follow-up
Doria MI Jr [16]	Male	23	Surgery	Died of lung metastasis after 6 months
Gonzalez-Campora R [11]	Female	27	Biopsy and chemotherapy	Died after 9 months
The present case	Male	51	Surgery and radiotherapy	Died of metastasis after 16 months

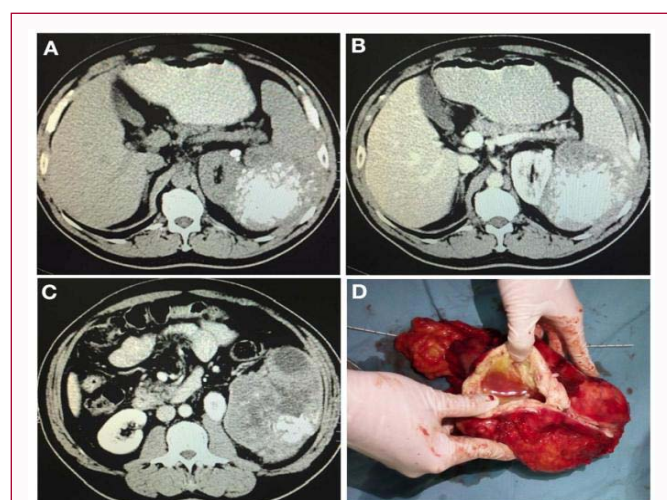


Figure 1: A large number of irregular calcification shadows and low-density shadows were in the mass, and the lump was closely associated with the pancreatic tail, the left kidney, and the spleen.

enhanced CT showed moderate enhancement in the parenchyma of the mass, but there is no significant enhancement in the low-density areas (Figure 1B). The patient underwent a successful operation and the abdominal tumor was resected completely. An intact fibrous capsule of the tumor was observed during the operation, in which the capsule could not be peeled off from the tumor (Figure 1D). The cut surface of the tumor was grayish-white and soft to rubbery. Since the left colic flexure, pancreatic tail and spleen were involved in the tumor, they were removed together with it. The histological examination of the tumor revealed pathological features of EMCS with both the undifferentiated oval or spindle-shaped cells and differentiated cartilaginous tissues (Figure 2). Additionally, immunohistochemistry result of tissues showed reactivity for CD99 (>90% ++), Vim (>90% ++), Ki67 (>90% ++), PDGFR α (20% +), bcl-2 (2+), but negative for CD117, Dog-1, CD34, S100, CD31, SMA, MyoD1, HMB45, EMA and GFAP. The pathological diagnosis was extraskeletal mesenchymal chondrosarcoma arising in retroperitoneal location with invasion extending to colon, pancreas and spleen. The patient was discharged from our hospital after 10 days, and received radiation therapy in the local hospital. A metastatic tumor was found after 10 months in a follow-up CT scan, and the patient felt depressed and refused further treatment, and died of tumor recurrence and cancer cachexia six months later. The lump was gray-white, with a small amount of viscous fluid found inside it, and the solid part was made up of bone-like tissue that could not be cut through with a scalpel.

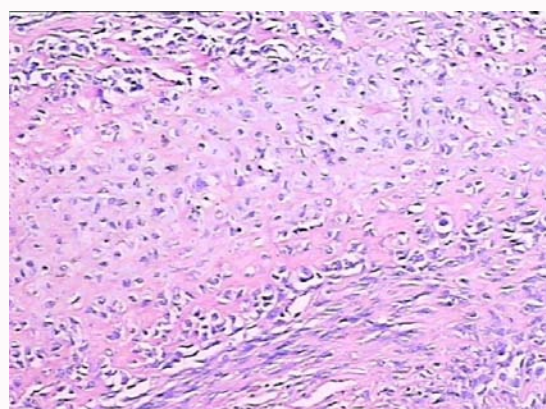


Figure 2: Small, benign-appearing cartilaginous tissue and undifferentiated oval or spindle-shaped cells were observed (HE x100).

Discussion

Mesenchymal chondrosarcoma is a variant subtype of conventional chondrosarcomas, and it is extremely rare and highly aggressive. Lichtenstein and Bernstein firstly reported the malignant chondrosarcoma in the bone in 1959 [5], and Dowling firstly reported it in the soft tissues in 1964 [6]. Mesenchymal chondrosarcoma may occur in any location which contains mesenchymal cells, and approximately 30% to 40% of it occurs in extraskeletal locations [7-8]. According to pathological features, chondrosarcomas can be divided into myxoid subtype, mesenchymal subtype, well-differentiated subtype, and the myxoid subtype, which is the most common subtype [9]. In contrast to conventional chondrosarcoma, extraskeletal mesenchymal chondrosarcoma only accounts for less than 1% of all chondrosarcomas [8], and the most ESMCs are located in the lower limbs, pia mater, and orbit [7]. The retroperitoneal ESMC is more rare and only 8 cases have been reported after a review of English literatures [10-17], and the characteristic of the reported cases of EMCS was shown in Table 1. Here, this is the first reported case of primary retroperitoneal ESMC invading to the colon. In adults, ESMC is easier to occur in two peak ages, depending on the location: The second and third decades of life for EMSC patients with central nervous system involvement, and the fourth and fifth decades of life for ESMC patients with muscular and/or soft-tissue involvement [18]. In the current study, the patient was 51-year-old. The preoperative radiological examination of ESMC should be utilized to determine the features of the tumor including the location, size, composition and metastasis of the tumor. Ultrasonography examination usually

manifests non-specific images as cystic solid mass composed of different components and partial calcification [18,19]. It has difficulty in distinguishing the mass from the normal surrounding tissue overlapping with the mass based on the B-ultrasound with its low density resolution. CT examination usually reveals a soft tissue mass accompanied with calcification, and the contrasted-enhanced CT usually shows a spot-like or spindle-shaped enhancement feature [8]. Hu et al. reported that the tumor appeared as ring- and arc-like, stippled and highly opaque calcifications under the CT scan [10]. Compared with B-ultrasound and CT, Magnetic Resonance Imaging (MRI) has more advantages in determining the shape and boundary of soft tissue mass and the relationship between tumors and their surrounding tissues. In terms of MRI imaging, the tumors present low mixed signals on T1WI and high signals on T2WI, which can be significantly enhanced by enhanced scanning [8]. Pathological examination is required to make a diagnosis of ESMC, which is characterized by two types of cells: Both of the poorly differentiated round, oval and spindle stromal cells and well-differentiated benign chondrocytes [8]. Immunohistochemical markers of ESMC are often helpful for diagnosis. CD99 and Vim proteins in mesenchymal cells are positive [8] and it has even been reported that in mesenchymal chondrosarcomas, CD99-positive can be used as a potential positive marker [20]. In chondroid tissue, S100 is usually positive, however the positive rate is less than 20% [21]. The patient in this case is positive for CD99 and Vim proteins and negative for S100, and a high Ki-67 index, indicating a less differentiation and high aggression of the tumor. Retroperitoneal ESMCs lack specific clinical characteristics in the early stage of the disease, and the patients do not present to the hospital until the tumor has grown to a certain extent, resulting in obvious abnormal body shape, pain or compression symptoms. Mesenchymal chondrosarcoma has a high-grade malignancy with strong tendency for hematopoietic metastasis and lymph metastasis, and surgery is the primary treatment [8]. If the tumor invades surrounding organs, the invaded organs should be resected together. Meanwhile, tumor rupture or contact with healthy tissues should be avoided as far as possible during the surgical operation. Postoperative radiotherapy or chemotherapy can be given to prevent recurrence and metastasis of the disease. If the tumor is too huge to be completely removed, or it has been metastasized to other organs or tissues, chemotherapy or radiotherapy should be considered after surgery [8]. However, it is still difficult to evaluate the curative effect of radiotherapy and/or chemotherapy, because there are no clinical trials and related data to evaluate these two therapies in EMCS. Even patients, who received postoperative radiotherapy or chemotherapy, are also easily at risk of recurrence or metastasis after surgery in a short time [12]. Nakashima reported that the current 5-year and 10-year survival rates for mesenchymal chondrosarcoma were 54% and 27%, respectively [22], but another study reported that the overall survival rate was worse for mesenchymal chondrosarcomas in axial locations compared to those tumors in cranial and appendicular locations [23].

Conclusion

Primary retroperitoneal extraskeletal mesenchymal chondrosarcomas are extremely rare and highly aggressive tumors, surgery is the primary treatment, which should be followed by adjuvant treatment, including radiation therapy and/or radiation therapy.

References

- Bertoni F, Picci P, Bacchini P, Capanna R, Innao V, Bacci G, et al. Mesenchymal chondrosarcoma of bone and soft tissues. *Cancer*. 1983;52(3):533-41.
- Johnson DB, Bredahl W, Newman JS, Devaney K, Yahanda A. Extraskeletal mesenchymal chondrosarcoma of the rectus sheath. *Skeletal Radiol*. 1997;26(8):501-4.
- Hashimoto N, Ueda T, Joyama S, Araki N, Beppu Y, Tatzaki S, et al. Extraskeletal mesenchymal chondrosarcoma: An imaging review of ten new patients. *Skeletal Radiol*. 2005;34(12):785-92.
- Yu L, Li M, Lin R, Mu Y, Zhao J. Mesenchymal chondrosarcoma of the right buccal region: A case report and review of the literature. *Oncol Lett*. 2014;8(6):2557-60.
- Lightenstein L, Bernstein D. Unusual benign and malignant chondroid tumors of bone. A survey of some mesenchymal cartilage tumors and malignant chondroblastic tumors, including a few multicentric ones, as well as many atypical benign chondroblastomas and chondromyxoid fibromas. *Cancer*. 1959;12:1142-57.
- Dowling EA. Mesenchymal chondrosarcoma. *J Bone Joint Surg Am*. 1964;46:747-54.
- Lockhart R, Menard P, Martin JP, Auriol M, Vaillant JM, Bertrand JC. Mesenchymal chondrosarcoma of the jaws. Report of four cases. *Int J Oral Maxillofac Surg*. 1998;27(5):358-62.
- Arora K, Riddle ND. Extraskeletal mesenchymal chondrosarcoma. *Arch Pathol Lab Med*. 2018;142(11):1421-4.
- Chow WA. Update on chondrosarcomas. *Curr Opin Oncol*. 2007;19(4):371-6.
- Hu HJ, Liao MY, Xu LY. Primary retroperitoneal extraskeletal mesenchymal chondrosarcoma involving the *vena cava*: A case report. *Oncol Lett*. 2014;7(6):1970-4.
- González-Cámpora R, Otal Salaverri C, Gomez Pascual A, Hevia Vazquez A, Galera Davidson H. Mesenchymal chondrosarcoma of the retroperitoneum. Report of a case diagnosed by fine needle aspiration biopsy with immunohistochemical, electron microscopic demonstration of S-100 protein in undifferentiated cells. *Acta Cytol*. 1995;39(6):1237-43.
- D'Andrea G, Caroli E, Capponi MG, Scicchitano F, Osti MF, Bellotti C, et al. Retroperitoneal mesenchymal chondrosarcoma mimicking a large retroperitoneal sacral schwannoma. *Neurosurg Rev*. 2008;31(2):225-9.
- Fukuzawa M, Kusafuka T, Oue T, Komoto Y, Tuji H, Okada A. "Mesenchymal chondrosarcoma of the retroperitoneum". *Med Pediatr Oncol*. 1998;30(3):196-7.
- White DW, Ly JQ, Beall DP, McMillan MD, McDermott JH. Extraskeletal mesenchymal chondrosarcoma: Case report. *Clin Imaging*. 2003;27(3):187-90.
- Guccion JG, Font RL, Enzinger FM, Zimmerman LE. Extraskeletal mesenchymal chondrosarcoma. *Arch Pathol*. 1973;95(5):336-40.
- Doria MI Jr, Wang HH, Chinoy MJ. Retroperitoneal mesenchymal chondrosarcoma. Report of a case diagnosed by fine needle aspiration cytology. *Acta Cytol*. 1990;34(4):529-32.
- Dhaliwal US, Singh A, Dhaliwal SS, Nagpal BL. Retroperitoneal mesenchymal chondrosarcoma. *J Indian Med Assoc*. 1985;83(2):62-4.
- Lange TA, Austin CW, Seibert JJ, Angtuaco TL, Yandow DR. Ultrasound imaging as a screening study for malignant soft-tissue tumors. *J Bone Joint Surg Am*. 1987;69(1):100-5.
- Johnson DB, Bredahl W, Newman JS, Devaney K, Yahanda A. Extraskeletal mesenchymal chondrosarcoma of the rectus sheath. *Skeletal Radiol*. 1997;26(8):501-4.

20. Müller S, Söder S, Oliveira AM, Inwards CY, Aigner T. Type II collagen as specific marker for mesenchymal chondrosarcomas compared to other small cell sarcomas of the skeleton. *Mod Pathol.* 2005;18(8):1088-94.
21. Lucas DR, Fletcher CD, Adsay NV, Zalupski MM. High-grade extraskeletal myxoid chondrosarcoma: A high-grade epithelioid malignancy. *Histopathology.* 1999;35(3):201-8.
22. Nakashima Y, Unni KK, Shives TC, Swee RG, Dahlin DC. Mesenchymal chondrosarcoma of bone and soft tissue. A review of 111 cases. *Cancer.* 1986;57(12):2444-53.
23. Schneiderman BA, Kliethermes SA, Nystrom LM. Survival in mesenchymal chondrosarcoma varies based on age and tumor location: A survival analysis of the SEER database. *Clin Orthop Relat Res.* 2017;475(3):799-805.