Annals of Clinical Case Reports

Case Report
Published: 08 Apr, 2019

Paranasal Sinus Metastases of Renal Cell Carcinoma: A Case Report and Comprehensive Literature Review

Petruzzelli GJ[1], Shook T[2], Campbell WJ[3] and Gupta S[4]*

[1]Anderson Cancer Institute, Memorial Health-Savannah, USA

[2]Urological Associates of Savannah, USA

[3]The Georgia Institute for Plastic Surgery, USA

[4]Mercer University School of Medicine, USA

Abstract

Metastasis of Renal Cell Carcinoma (RCC) to the paranasal sinuses is extremely rare, with approximately 100 cases reported in the literature. We report the case of a 60-year-old man with a history of clear cell RCC, who presented 30 months after nephrectomy for his primary tumor. His symptoms included right-sided facial asymmetry, severe facial pain, and right-sided nasal airway obstruction. CT and gadolinium enhanced magnetic resonance images showed opacification of the right maxillary sinus with a large sinus mass filling the antrum with destruction of the horizontal process of the maxilla and invasion of the alveolar ridge (Figure 1). The tumor was biopsied through a transantral approach and histological examination was consistent with clear cell RCC. There were no additional metastases present upon investigation with CT of the chest, abdomen, and pelvis. The patient underwent a standard right globe sparing radical maxillectomy and reconstruction with an anterior-lateral thigh microvascular free tissue transfer. Pre-operatively, the tumor was embolized in an effort to reduce intraoperative blood loss. Final histopathology confirmed metastatic renal cell carcinoma-clear cell variety with negative surgical margins. Although rare, metastatic renal cell carcinoma must always be considered during evaluation of new sinonasal lesions, with or without a prior history of nephrectomy, especially if systemic signs such as hematuria or suspicious CT findings such as bone erosion are present. Epistaxis and nasal obstruction are the most common presenting signs but several atypical presentations have been reported. A correct diagnosis requires a thorough clinical history, radiological evaluation, and biopsy with consideration of propensity for bleeding during both biopsy and surgery. Prompt evaluation and treatment of metastatic RCC can considerably improve quality of life and survival in select patients.

Introduction

Renal Cell Carcinoma (RCC) is the most common histologic type of kidney malignancy and upon diagnosis, 30% of patients already have metastasis to a distant site [1]. The most common sites of metastasis of RCC are the abdomen, brain, liver, lungs, bones, and adrenal glands [19] and compared to these sites, metastasis to the sinonasal region is extremely rare. However, RCC is known to metastasize to unusual sites and is the most common malignant tumor to metastasize to the paranasal sinuses, with approximately100 cases reported in the literature. Metastasis to these sites has been reported even years after curing with primary surgery [8]. We report a case of clear cell renal cell carcinoma with metastasis to the maxillary sinus treated with preoperative embolization and radical maxillectomy and include a comprehensive review of the literature (Table 1) regarding metastasis of this rare malignancy to the paranasal sinuses.

Case Presentation

A 60-year-old man presented for the evaluation of right-sided facial asymmetry, severe facial pain and right side nasal airway obstruction. There were no vision changes, diplopia, epistaxis or epiphora. Imaging studies revealed opacification of the right maxillary sinus with a mass filling the antrum with destruction of the horizontal process of the maxilla and invasion of the alveolar ridge (Figure 1). The patient's past medical history remarkable for a T3a, NX, M0, Grade 2 renal cell carcinoma-clear cell variety treated by left radical nephrectomy performed 30 months prior. Histopathology at that point showed an 8.9 cm unifocal renal mass limited to the kidney extending into a major vein. Resection margins and the attached left adrenal gland were negative

OPEN ACCESS

Correspondence:
Petruzzelli GJ, Anderson Cancer Institute, Memorial Health-Savannah, 4700 Waters Ave, Savannah, GA 31404, USA,
E-mail: guy.petruzzelli@hcahealthcare.com

Received Date: *08 Jan 2019*
Accepted Date*: 04 Apr 2019*
Published Date*: 08 Apr 2019*

Citation:
Petruzzelli GJ, Shook T, Campbell WJ, Gupta S. Paranasal Sinus Metastases of Renal Cell Carcinoma: A Case Report and Comprehensive Literature Review. Ann Clin Case Rep. 2019; 4: 1642.

ISSN: 2474-1655

Table 1: Paranasal sinus metastases of RCC: Summary of cases and review of the literature.

Sex/Age at diagnosis	Location	Diagnosis of metastasis before primary treatment	Interval between diagnosis of primary tumor and metastasis	Treatment of primary tumor	Presenting symptoms	Survival after discovery of metastasis to sinus	Reference #
76/M	Sphenoid sinus	NA	NA	NA	Diplopia, ptosis, facial pain	NA	[3]
62/M	Ethmoid sinus	Yes	Metastasis first	-	Epistaxis and anemia	Disease free at 5 months	[4]
60/M	Maxillary sinus	No	6 years	Nephrectomy	Epistaxis and nasal obstruction	Disease free at 1 year	[5]
61/M	Ethmoid sinus	Yes	Metastasis first	-	NA	Disease free at 1 year	[6]
65/M	Maxillary sinus	No	7 years	Nephrectomy	Nasal obstruction, post nasal drip, cough, and pressure sensation	NA	[7]
58/M	Maxillary sinus	No	11 years	Nephrectomy	Epistaxis	NA	[8]
60/F	Maxillary sinus	No	10 years	Nephrectomy	Hyposmia, pain	NA	[8]
87/F	Maxillary sinus	No	8 years	Nephrectomy	Epistaxis, nasal obstruction	NA	[8]
73/M	Ethmoid sinus	Yes	Metastasis first	-	Epistaxis	NA	[8]
60/M	Maxillary sinus	No	6 months	Nephrectomy	NA	NA	[8]
62/M	Ethmoid sinus	No	6 years	Nephrectomy	Epistaxis	Recurrence 8 years after surgery	[9]
	Sphenoid sinus	No	14 years	Nephrectomy	Epistaxis	Recurrence 1 year after surgery	
	Maxillary sinus	No	15 years	Nephrectomy	Lesion noticed on physical exam	No recurrence at 5 year follow up	
53/M	Sphenoid sinus	No	10 years	Nephrectomy	Nasal obstruction and facial pressure	No recurrence at 18 month follow up	[10]
67/M	Ethmoid and Sphenoid sinuses	No	3 years	Nephrectomy	Epistaxis and nasal obstruction	NA	[10]
78/NA	Frontal sinus	No	5 years	Nephrectomy	NA	Death after 2 months	[11]
73/NA	Ethmoid sinus	No	17 years	Nephrectomy	Epistaxis	NA	[12]
58/NA	Maxillary sinuses	No	11 years	Nephrectomy	Nasal obstruction	NA	[13]
60/NA	Ethmoid and maxillary sinus	Yes	Metastasis first	-	Ptosis, frontal swelling, headaches, and epistaxis	No recurrence at 3 months	[14]
72/M	Ethmoid sinus	Yes	Metastasis first	-	Epistaxis	Death after 4 months	[15]
74/M	Sphenoid sinus	No	12 years	Nephrectomy	Numbness of the left side of the face, reduced visual acuity, and ptosis	NA	[16]
58/M	Frontal sinus	Yes	Metastasis first	-	Frontal swelling	NA	[17]
57/M	Ethmoid sinus	Yes	Metastasis first	-	Headache and epistaxis	No recurrence at 30 months post treatment	[18]
79/F	Ethmoid and Frontal sinus	Yes	Metastasis first	-	Epistaxis	No recurrence at 9 months	[19]
53/M	Sphenoid sinus	Yes	Metastasis first	-	Rhinorrhea	NA	[20]
65/M	Maxillary sinus	Yes	Metastasis first	-	Epistaxis, sinusitis, and proptosis	NA	[21]
56/M	Maxillary and ethmoid sinus	No	7 years	Nephrectomy	Epistaxis, facial pain, and headache	Poor prognosis so palliative radiotherapy provided	[22]
70/M	Sphenoid sinus	Yes	Metastasis first	-	Diplopia and visual disturbances	Lost to follow up	[23]
67/M	Ethmoid and sphenoid sinus	No	10 years	Nephrectomy	Nasal obstruction	No recurrence at 46 month follow up	[24]
47/M	Ethmoid sinus	No	17 years	Nephrectomy	Nasal obstruction and epistaxis	No recurrence at 9 months follow up	[25]
50/M	Maxillary sinus	Yes	Metastasis first	-	Nasal obstruction and snoring	Recurrence at 1 year	[26]
60/M	Maxillary sinus	No	6 months	Nephrectomy	Intermittent epistaxis and pain	NA	[27]
73/M	Ethmoid sinus	No	2 years	Nephrectomy	Epistaxis	NA	[28]
65/F	Ethmoid sinus	No	4 months	Nephrectomy	Epistaxis and nasal obstruction	Death after 8 months from brain metastases	[29]
85/M	Frontal sinuses and ethmoid sinuses	Yes	Metastasis first	-	Intermittent Epistaxis	NA	[30]
60/M	Frontal sinus	No	3 years	Nephrectomy	Nasal obstruction	NA	[31]

54/M	Maxillary sinus	No	7 years	Nephrectomy	Epistaxis	NA	[32]
42/M	Frontal and ethmoid sinuses	No	10 years	Nephrectomy	Epistaxis	NA	[33]
59/W	Ethmoid sinus	Yes	Metastasis first	-	Diplopia and discomfort	No recurrence at 2 years after diagnosis	[34]
58/M	Maxillary sinus	No	2 years	Interferon therapy	Nasal obstruction	No recurrence at 3 years after diagnosis	[35]
73/M	Maxillary sinus	Yes	Metastasis first	-	Epistaxis	Recurrence in 2 years to contralateral sinus	[36]
	Maxillary sinus	No	15 months	Nephrectomy	Nasal obstruction and epistaxis	No recurrence at 1 year follow up	
48/M	Maxillary and ethmoid sinuses	Yes	Metastasis first	-	Epistaxis	Death after 1 year from general metastases	[36]
73/M	Ethmoid sinus	Yes	Metastasis first	-	Epistaxis	No recurrence at 3 years follow up	[37]
58/M	Ethmoid and maxillary sinus	Yes	Metastasis first	-	Proptosis and headaches	No recurrence at 62 months follow up	[38]
50/M	Ethmoid sinus	No	6 years	Nephrectomy	Exophthalmos; ocular and nasal stiffness	No recurrence at 6 years follow up	[39]
63/M	Ethmoid sinus	No	2 years	Nephrectomy	Epistaxis	No recurrence at 1 year after surgery	[40]
66/M	Ethmoid and sphenoid sinuses	No	5 years	Nephrectomy	Nasal obstruction and headaches	No recurrence at 1 year after surgery	[41]
50/W	Maxillary sinus	No	10 years	Nephrectomy	Nasal obstruction, hyposmia, sinus pain	NA	[42]
35/M	Maxillary sinus	Yes	Metastasis first	-	Mass in maxillary region	Death 2 years after primary diagnosis	[43]
65/M	Ethmoid sinus	No	15 years	Nephrectomy	Swelling and proptosis	Lost to follow up after 2 months	[44]
58/F	Ethmoid and sphenoid sinuses	No	10 years	Nephrectomy	Epistaxis	No recurrence at 4 months follow up	
40/F	Ethmoid sinus	No	12 years	Nephrectomy	Swelling in frontal region	Symptomatically improved at 6 months follow up	
79/F	Ethmoid and frontal sinuses	Yes	Metastasis first	-	Epistaxis	Asymptomatic 9 months after initial diagnosis	[45]
NA	Maxillary sinus	NA	NA	NA	Epistaxis	NA	[46]
NA	Maxillary sinus	NA	NA	NA	Epistaxis and pain	NA	[47]
70/M	Sphenoid sinus	Yes	Metastasis first	-	Diplopia and visual disturbances	Lost to follow up after 3 months	[48]

F: Female; M: Male; NA: Not Available

Table 2: Presenting symptoms of RCC metastases to the paranasal region (52 cases).

Presenting complaint	Frequency	Percentage
Epistaxis	32	55.20%
Nasal obstruction	16	27.60%
Visual disturbances (diplopia, ptosis, reduced visual acuity, proptosis)	8	13.80%
Other	20	34.50%

Table 3: Involved sites of paranasal sinus metastases of RCC (52 cases).

Involved site	Frequency	Percentage
Ethmoid sinus	29	50.00%
Maxillary sinus	23	39.60%
Sphenoid sinus	11	19.00%
Frontal sinus	6	10.30%

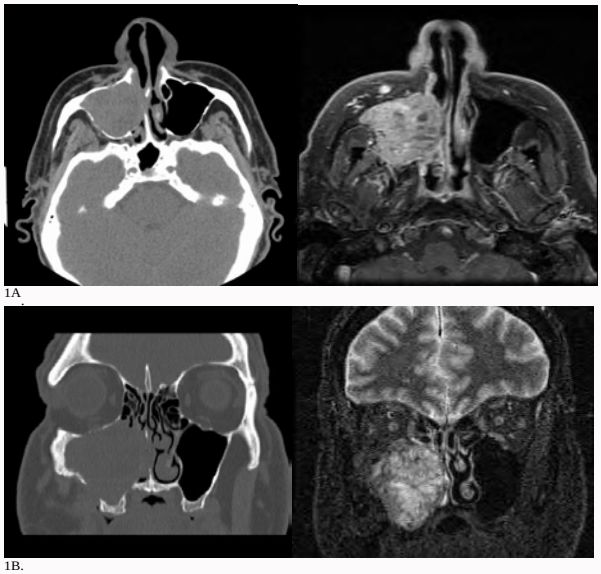

Figure 1: Companion axial (A) and coronal (B) non-contract computed tomography and gadolinium enhanced magnetic resonance images of the large right maxillary sinus mass with bone erosion.

for malignancy. The right maxillary sinus tumor was biopsied *via* a transantral approach and a diagnosis of renal cell carcinoma-clear cell variety was obtained. CT scan of the chest abdomen and pelvis showed no evidence of additional metastases and the patient underwent a standard right globe sparing radical maxillectomy and reconstruction with an anterior-lateral thigh microvascular free tissue transfer. Preoperatively the tumor was embolized with Gelfoam™ powder (Pharmacia & Upjohn Co, New York) which significantly reduced intraoperative blood loss and obviated the need for blood transfusion (Figure 2). Radical maxillectomy specimen showed a lateral surface with intact turbinate and nasal wall and superior surface with an intact orbital floor thinned by tumor (Figure 3). Final histopathology of the maxillary specimen revealed metastatic renal cell carcinoma-clear cell variety with negative surgical margins (Figure 4). The patient

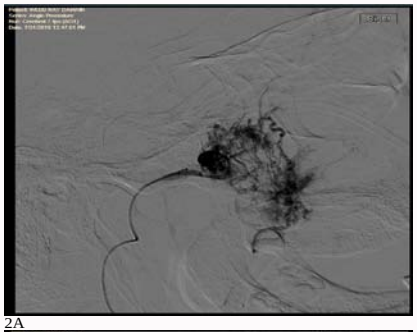

2A

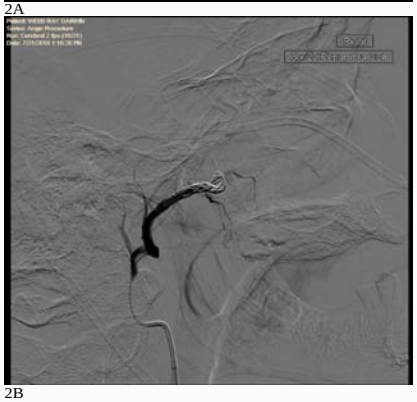

2B

Figure 2: Pre (A) and post (B) embolization images of the preoperative embolization of the large hyper-vascular maxillary sinus tumor. Note the coils deployed in the proximal internal maxillary to assure maximum reduction in arterial flow into the tumor.

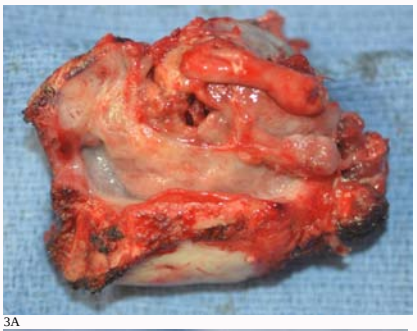

3A

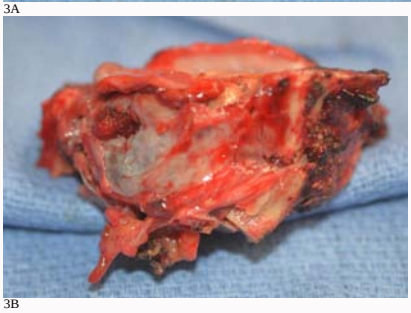

3B

Figure 3: A. Radical maxillectomy specimen lateral surface with intact turbinate and lateral nasal wall. B. Superior surface with intact orbital floor thinned by tumor.

recovered well and was discharged from the hospital tolerating a mechanical soft diet and continues to be followed closely.

Discussion

Renal cell carcinoma is relatively rare and represents only 3% of all malignant tumors. It is slow growing and only 10% of patients have the classical presentation of flank pain, palpable abdominal mass and hematuria [49]. Although hematuria is present in 90% of patients, it is typically intermittent and microscopic, which prevents early detection [34]. Many times the metastasis is detected before the primary tumor and a third of patients with RCC have metastasis at diagnosis. Of the remaining two thirds, 50% have recurrence of the disease even after treatment of the initial lesion [21]. RCC has a predilection for metastasis to the lungs (75%), lymph nodes (65%), bone (40%), and liver (40%), with metastasis to the head and neck region only accounting for 15% of cases. Within the head and neck, the most common locations for metastasis are the paranasal sinus, throat, oropharynx, temporal bone, thyroid and parotid gland, in order of decreasing frequency [15]. Though metastasis to paranasal sinuses is relatively rare, RCC is the most common infraclavicular tumor to metastasize to the paranasal sinuses and accounts for 49% of cases, followed in order of decreasing frequency by bronchus, urogenital ridge, breast, and GI tract metastases [16].

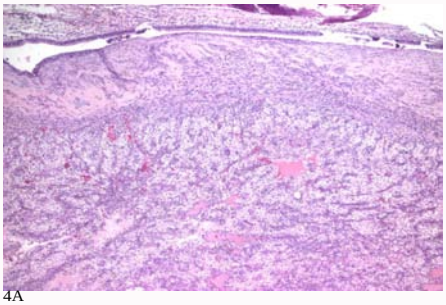

4A

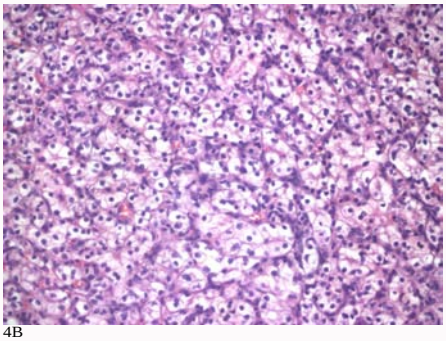

4B

Figure 4: A. Final pathology specimen showing metastatic clear cell renal cell carcinoma replacing bone in the wall of the maxillary sinus deep to intact maxillary sinus mucosa (H&E 40x). B. High power identification of classical renal cell carcinoma (H&E 200x).

The methods of renal cell carcinoma metastasis described in the literature are both hematogenous and lymphatic. One route that has been described is through the inferior vena cava, heart, lungs, and maxillary artery, in which case concurrent metastases to the brain and lung are possible. However, RCC potentially bypassing the lungs through the fine pulmonary filter beds has been described in the literature [52], along with regression of microscopic seeding of the lung parenchyma through an immunological mechanism [22]. Another potential hematogenous route of spread is retrograde flow through the valveless vertebral venous plexus, intracranial venous plexus, and cavernous venous plexus to the paranasal sinuses [19,40]. The lymphatic route that has been hypothesized is retrograde flow through the intercostal, mediastinal, or supraclavicular lymph nodes to the head and neck region [22]. Several of these methods bypass the heart and lungs and create an opportunity for an isolated sinonasal metastasis, as seen in our case report.

The most common presenting signs of RCC metastasis to the paranasal sinus from our evaluation of 58 cases in the literature demonstrated in Table 2 and include epistaxis (55%) and nasal obstruction (28%) [3-48]. However other presentations including diplopia [3,23,34,48], proptosis [21,38,44], pain [8], hyposmia [8,42], headache [14,18,22,38,41], numbness of the face [16], and facial swelling have also been reported [14,17,44]. These symptoms often lead to radiological examination that shows a hypervascular mass in the nasal cavity or paranasal sinuses, and a primary sinonasal tumor such as angiofibroma, hemangiopericytoma, hemangioma, or sinonasal glomus tumors is usually first suspected [50]. CT scan is helpful in assessing characteristics of the lesion that hint towards it being benign or malignant, such as bone erosion, remodeling, and hypervascularity. However, the literature supports the use of MRI when the extent of the lesion is too large to confirmed by CT alone [9,19]. RCC metastases can have similar radiological appearances to primary malignant lesions of the sinonasal cavities so it is important to consider a renal origin when indicators such as enhancement, destruction, and lack of tumoral calcification are observed [15]. Surgical removal of the metastatic tumor and histologic examination supported by immunohistochemical staining is necessary to confirm presence of the primary renal cell carcinoma [51]. Risks of the biopsy include hemorrhage and selective embolization has been advocated by some authors, especially in individuals with a known history of nephrectomy, due to the hypervascular nature of the tumor [19]. Once pathology results suggest RCC, the renal system and other areas prone to RCC metastasis such as the lungs, bone, and brain should also be examined [19], with urinalysis, ultrasonography, and total body CT being cited in the literature as vital portions of the diagnostic workup [15,33]. One author also advocates for the use of PET-CT as a preferred modern imaging modality, citing its ability to detect both anatomical and physiological presence of the disease [33].

Based on our review of 58 cases in the literature, the most commonly involved metastatic sites of the paranasal sinuses are demonstrated in Table 3 and include the ethmoid sinus (29 cases, 50%), maxillary sinus (23 cases, 39.6%), sphenoid sinus (11 cases,19%), and frontal sinus (6 cases, 10.3%). Cases in the literature have also described metastasis to the orbit, nasopharynx, nasal septum, nasal tip, and pterygopalatine fossa [9]. Metastatic lesions of RCC can present themselves before the primary renal tumor has been detected and of the cases analyzed, 21 (36.2%) had diagnosis of the metastasis before the primary tumor. It is also possible that the primary renal tumor is not detectable during initial investigations of the metastatic lesion. Matsumoto et al. [36] describe a case where a renal source for the metastatic RCC lesion could not be found initially but was detected 8 months later, after the patient had already undergone a total maxillectomy.

Metastatic RCC to the paranasal sinuses can present many years after nephrectomy for the primary tumor and our literature review revealed that 13 cases (23%) had confirmed metastases 10 years or more after undergoing nephrectomy for the primary tumor. Two separate cases describe metastatic RCC, both to the ethmoid sinus, presenting 17 years after nephrectomy for the primary tumor [12,25]. Consecutive metastases to the ethmoid, sphenoid, and maxillary sinus in the same individual have also been reported presenting 6 years, 14 years and 15 years respectively after nephrectomy for the primary tumor [9]. Therefore a strong element of clinical suspicion must always be present when evaluating new sinonasal tumors in patients that have a history of renal cell carcinoma, even after successful nephrectomy for the primary renal tumor or successful treatment for a past RCC paranasal sinus metastasis.

The prognosis of metastatic RCC is generally poor, with a median survival of only 7-11 months [4]. However, an early-stage diagnosis with resection of a solitary metastatic lesion following nephrectomy has been reported to increase survival rate considerably, with a two year survival rate of 41% and a 5 year survival rate of 13%. Survival is much lower when multiple organ metastases are present, with 5 year survival rates of 0% to 7% reported [15,33]. Treatment of the metastatic lesion is controversial and survival of patients treated with surgery has not shown to be considerably greater than full dose radiotherapy [22]. However, some authors have argued that preoperative embolization followed by endoscopic resection is extremely safe and effective in patients with isolated lesions, while also providing an opportunity for significant symptom relief during administration of systemic adjuvant therapy in those with widely disseminated disease [10].

Conclusion

RCC is a relatively rare tumor but must always be considered during evaluation of new sinonasal lesions, with or without a prior history of nephrectomy. RCC metastasis to the paranasal sinuses has an unpredictable timeline that does not necessarily have to include seeding of other sites, and the maxillary and ethmoid sinuses are the most commonly involved locations. Epistaxis and nasal obstruction are the most common presenting signs and may be the only clue to the presence of the disease, but many atypical presentations have been reported. A thorough clinical history, radiological evaluation, and biopsy are required to establish a diagnosis and propensity for bleeding during both biopsy and resection of the lesion must always be considered. Several factors play a role in prognosis but prompt evaluation and treatment can considerably improve quality of life and survival in select patients.

References

1. Motzer RJ, Hutson TE, Tomczak P, Michaelson MD, Bukowski RM, Rixe O, et al. Sunitinib versus interferon alfa in metastatic renal-cell carcinoma. N Engl J Med. 2007;356(2):115-24.
2. Bianchi M, Sun M, Jeldres C, Shariat SF, Trinh QD, Briganti A, et al. Distribution of metastatic sites in renal cell carcinoma: a population-based analysis. Ann Oncol. 2012;23(4):973-80.
3. Mickel RA, Zimmerman MC. The sphenoid sinus- a site for metastasis. Otolaryngol Head Neck Surg. 1990;102(6):709-16.
4. Lee SM, Kim YM, Kim BM. Epitasis as the first manifestation of silent renal cell carcinoma: A case report with relevant literature review. Iran J Radiol. 2016;13(1):e31208.
5. Mahajan R, Nagaraj M, Prashanth V. Metastatic renal cell carcinoma presenting as nasal mass : case report and review of literature. Indian J Otolaryngol Head Neck Surg. 2016;68(3):374-6.
6. Berkiten G, Kumral T, Yildirim G, Atar Y, Salturk Z, Dogan M, et al. Metastasis of renal cell carcinoma to head and neck region. Otolaryngol Online J. 2016;6(3):133.
7. Wong EHC, Tetter N, Glatz K, Brand Y. Renal cell carcinoma metastases to the maxillary sinus. BMJ Case Reports. 2017:2017.
8. Sountoulides P, Metaxa L, Cindolo L. Atypical presentations and rare metastatic sites of renal cell carcinoma: A review of case reports. J Med Case Rep. 2011;5:429.
9. Zhang N, Zhou B, Huang Q, Chen X, Cui S, Huang Z, et al. Multiple metastases of clear-cell renal cell carcinoma to different region of the nasal

cavity and paranasal sinus 3 times successively: A case report and literature review. Medicine (Baltimore). 2018;97(14):e0286.

10. Remenschneider A, Sadow P, Lin D, Gray S. Metastatic renal cell carcinoma to the sinonasal cavity: A case series. J Neurol Surg Rep. 2013;74(2):67-72.

11. Lieder A, Guenzel T, Lebentrau S, Schneider C, Franzen A. Diagnostic relevance of metastatic renal cell carcinoma in the head and neck: An evaluation of 22 cases in 671 patients. Int Braz J Urol. 2017;43(2):202-8.

12. Álvarez-Múgica M, Vázquez Bulnes V, JalónMonzón A, Gil A, Rodríguez Robles L, Miranda Aranzubía O. Late recurrence from a renal cell carcinoma: solitary right maxilar mass 17 years after surgery. Arch Esp Urol. 2010;63(2):147-50.

13. Sawazaki H, Segawa T, Yoshida K, Kawahara T, Inoue T, Soda T, et al. Bilateral maxillary sinus metastasis of renal cell carcinoma: a case report. Hinyokika Kiyo. 2007;53(4):231-4.

14. Hainăroșie R, Anghelina F, Ioniță IG, Zoican OI, Pietroșanu C, Pițuru SM, et al. Rare metastasis of renal carcinoma in the frontoethmoid- orbital region – case report and review of the literature. Rom J Morphol Embryol. 2017;58(4):1497-1504.

15. Ralli M, Altissimi G, Turchetta R, Rigante M. Metastatic renal cell carcinoma presenting as a paranasal sinus mass: the importance of differential diagnosis. Case Rep Otolaryngol. 2017;1-5.

16. Evgeniou E, Menon KR, Jones GL, Whittet H, Williams W. Renal cell carcinoma metastasis to the paranasal sinuses and orbit. BMJ Case Rep. 2012;2012:2-5.

17. Ikeuchi T, Hori T, Hirao N, Tozawa K, Yamada Y, Kori K. Renal cell carcinoma detected by metastasis to the frontal sinus: a case report. Hinyokika Kiyo. 1998;44(2):89-92.

18. Maheshwari G, Baboo H, Patel M, Usha G. Metastatic renal cell carcinoma involving ethmoid sinus at presentation. J Postgraduate Med. 2003;49(1):96-7.

19. Fyrmpas G, Adeniyi A, Baer S. Occult renal cell carcinoma manifesting with epistaxis in a woman: A case report. J Med Case Rep. 2011;5:2-5.

20. Morvan JB, Veyrires JB, Mimouni O, Cathelinaud O, Allali L, Verdalle P. Clear-cell renal carcinoma metastasis to the base of the tongue and sphenoid sinus: Two very rare atypical ENT locations. European Ann Otorhinolaryngol Head Neck Dis. 2011;128(2):91-4.

21. Bechara GR, Anacleto J, Resende D, Gouveia HA. Metastasis to paranasal sinuses as the first presenting sign of renal cell carcinoma. Open J Eurol. 2012;2(1):28-31.

22. Nayak DR, Pujary K, Ramnani S, Shetty C, Parul P. Metastatic renal cell carcinoma presenting with epistaxis. Indian J Otolaryngol Head Neck Surg. 2006;58(4):406-8.

23. Nayak DR, Pujary K, Ramnani S, Shetty C, Parul P. Metastatic renal cell carcinoma presenting with epistaxis. Indian J Otolaryngol Head Neck Surg. 2006;58(4):406-8.

24. Heo SJ, Kwon TG, Kim JS. Metastatic renal cell carcinoma in the paranasal sinus: a case report and literature review. Korean J Otorhinolaryngol-Head Neck Surg. 2016;59(12):877-81.

25. Ziari, M, Shen S, Amato RJ, Teh BS. Metastatic renal cell carcinoma to the nose and ethmoid sinus. Urology. 2006;67(1):199.

26. Kokenek-Unal TD, Gumuskaya B, Ocal B, Alper M. A rare cause of nasal obstruction: metastatic renal cell carcinoma. Case Rep Pathol. 2016;2016:3.

27. Stieve M, Issing PR. Unusual metastasis of hypernephroma in the maxillary sinus. Laryngorhinootologie. 1997;76(6):374-8.

28. Arai Y, Ito K, Tachi K, Koga A, Shinchi Y, Masunga A, et al. Metastatic renal cell carcinoma in paranasal sinus for which periodic drug withdrawal schedule of axitinib was effective : A case report. Hinyokika Kiyo. 2016;62(9):465-71.

29. Larrosa F, Aguilar F, Traserra J. Ethmoidal metastasis of renal adenocarcinoma. Acta Otorrinolaringol Esp. 2000;51(1):76-9.

30. Sgouras N, Gamatsi I, Porfyris E, Lekka J, Harkiolakis G, Nikolopoulou SM, et al. An unusual presentation of a metastatic hypernephroma to the frontonasal region. Ann Plast Surg. 1995;34(6):653-6.

31. Nieto JT, Roy FF, García AU, Rodrigo JF, Obón JP, Gotor CY, et al. Hypernephroma metastasis in frontal sinus. Acta Otorrinolaringol Esp. 1994;45(5):375-8.

32. Ito R, Nishiike S, Tomiyama Y, Yoshii T, Yamamoto Y, Inohara H. Three cases of renal cell carcinoma metastasizing to the head and neck. Nihon Jibiinkoka Gakkai Kaiho. 2011;114(11):864-8.

33. Kumar R, Sikka K, Kumar R, Chatterjee P. Nephrogenic epistaxis. Singapore Med J. 2014;55(7):e112-3.

34. Homer JJ, Jones NS. Renal cell carcinoma presenting as a solitary paranasal sinus metastasis. J Laryngol Otol. 1995;109(10):968-9.

35. Simo R, Sykes AJ, Hargreaves SP, Axon PR, Birzgalis AR, Slevin NJ, et al. Metastatic renal cell carcinoma to the nose and paranasal sinuses. Head Neck. 2000;22(7):722-7.

36. Matsumoto Y, Yanagihara N. Renal clear cell carcinoma metastatic to the nose and paranasal sinuses. Laryngoscope. 1982;92(10 Pt 1):1190-3.

37. Lee HM, Kang HJ, Lee SH. Metastatic renal cell carcinoma presenting as epistaxis. Eur Arch Otorhinolaryngol Suppl. 2004;262(1):69-71.

38. Gottlieb MD, Roland JT Jr. Paradoxical spread of renal cell carcinoma to the head and neck. Laryngoscope. 1998;108(9):1301-5.

39. Jung JW, Yoon SC, Han DH, Chi M. Metastatic renal cell carcinoma to the orbit and the ethmoid sinus. J Craniofac Surg. 2012;23(2):e136-8.

40. Terada N, Hiruma K, Suzuki M, Numata T, Konno A. Metastasis of renal cell cancer to the ethmoid sinus. Acta Otolaryngol Suppl. 1998;537:82-6.

41. Vreugde S, Duttmann R, Halama A, Deron P. Metastasis of a renal cell carcinoma to the nose and paranasal sinuses. Acta Otorhinolaryngol Belg. 1999;53(2):129-31.

42. Muros BT, Romero JRS, Baró JGR, Parrilla RB. Maxillary sinus metastasis of renal cell carcinoma. Actas Urológicas Españolas. 2006;30(9):954-7.

43. He YF, Chen J, Xu WQ, Ji CS, Du JP, Luo HQ, et al. Case report metastatic renal cell carcinoma to the left maxillary sinus. Genet Mol Res. 2014;13(3):7465-9.

44. Parida PK. Renal cell carcinoma metastatic to the sinonasal region: Three case reports with a review of the literature. ENT J. 2012;91(11):E11-6.

45. Fyrmpas G, Adeniyi A, Baer S. Occult renal cell carcinoma manifesting with epitasis in a woman: A case report. J Med Case Rep. 2011;5(1):79.

46. Issing PR, Stöver T, Kempf HG, Heermann R, Lenarz T. Sonographic diagnosis of metastatic renal cell carcinoma to the head and neck region [in German]. Ultraschall Med. 1999;20(5):218-22.

47. Stieve M, Issing PR. Unusual metastasis of hypernephroma in the maxillary sinus [in German]. Laryngorhinootologie. 1997;76(6):374-8.

48. Singh I, Khaitan A. Diplopia an unusual primary manifestation of metastatic renal cell carcinoma. Urol Int. 2004;73(3):285-6.

49. Skinner DG, Vermillion CD, Pfister RC, Leadbetter WF. Renal cell carcinoma. Am Fam Physician. 1971;4:89-94.

50. Razek AA, Huang BY. Soft tissue tumors of the head and neck: imaging-based review of the WHO classification. Radiographics. 2011;31(7):1923-54.

51. Singh J, Baheti V, Yadav SS, Mathur R. "Occult renal cell carcinoma manifesting as nasal mass and epistaxis". Rev Urol. 2014;16(3):145-8.

52. Boles R, Cerny J. Head and neck metastases from renal carcinomas. Mich Med. 1971;70(16):616-8.