



Misdiagnosed Diplopia in a Patient with Neurosyphilis

Thersilla Oberbarnscheidt* and Esha Khurana

Department of Psychiatry, Western Psychiatric Hospital, University of Pittsburgh, USA

Abstract

Background: Syphilis is a sexually transmitted disease caused by the bacterium *Treponema pallidum* that affects in later stages the central nervous system.

Case Report: 37-year-old male with history of stimulant use disorder and depression with misdiagnosed blurred vision for one year duration. Syphilis serologies positive, cerebrospinal fluid positive for IgG and IgM syphilis. Treated with Penicillin G for 14 days.

Discussion: Neurosyphilis cases are currently on the rise and need to be considered as differential when presenting with atypical psychiatric or neurological symptoms. The diagnosis is based on serological markers in the blood and cerebrospinal fluids. Cerebral imaging studies are encouraged for early detection as well.

Introduction

Syphilis was first discovered in 1905 by the German zoologist Fritz Schaudinn and dermatologist Erich Hoffman [1]. The first outbreak of syphilis occurred in 1945 when Charles VII invaded Naples and his troops spread it through Europe. The disease is mostly spreads through sexual transmission [2]. Syphilis is caused by *Treponema pallidum* and involves multiple organ systems. In later stages of the disease, the Central Nervous System (CNS) is involved as well. The symptoms of neurosyphilis can present as meningitis, meningovascularitis and parenchymal neurosyphilis as Tabes dorsalis [3]. *Treponema pallidum* is very sensitive to the antibiotic penicillin [4]. However, even though penicillin is available, the diagnosis of neurosyphilis is not always easy to make and atypical presentations have been reported [5]. Syphilis cases have been rising over the last decade. 133,945 cases of syphilis of all stages were reported in 2020 while 41,655 cases are primary and secondary syphilis [6]. The rate of primary and secondary syphilis has increased by 147% in the window 2016-2020 and 21% 2019-2020 [6]. Acute syphilis can easily be misdiagnosed as primary psychiatric disorder as symptoms can mimic depression, anxiety, psychosis, delirium, cognitive changes with dementia [7]. The described case below illustrates the challenges in diagnosing neurosyphilis in a complex patient with mental health and co-occurring substance use disorder.

Case Presentation

A 37-year-old male was referred to the dual diagnosis treatment center after a psychiatric inpatient admission related to substance induced psychosis in January 2020 (Figure 3). The patient had been in recovery ever since his discharge from the hospital and free of perceptual abnormalities. He denied any illicit substance use, continued to smoke tobacco about one pack per day. The patient was followed monthly due to active co-occurring psychiatric symptoms consisting of depressed mood, insomnia, lack of energy and motivation with loss of appetite, mild weight loss and intermittent suicidal ideations. His medications were consistent of: Sertraline 250 mg daily, Aripiprazole 4 mg daily and Hydroxyzine 25 mg as needed up to three times a day for anxiety. The patient had initially reported the blurred vision during a visit in April 2021. He had described fuzzy outlines, at times with flashes of light and floaters. He was referred to an ophthalmologist with appointment being scheduled in July of 2021. He did attend the appointment and was informed to have dry eyes and was prescribed ophthalmic solutions. He did comply with the treatment and noticed only a minimal improvement. Due to persisting symptoms and his optic nerve appearing inflamed on examination, he received intraocular steroid injections. Over the course of the next several months his vision worsened to the point where he was unable to work and started having difficulties ambulating in his own apartment. At that time, he contacted his Primary Care Provider. In November 2021, he was found to have bilateral uveitis on exam and serum syphilis and Lyme testing were ordered and returned positive. He was referred to an infectious disease consult at the local hospital. Upon arrival at the hospital, the patient's chief complaint was solely the blurry vision. The patient denied headaches, confusion, or any other neurological symptoms. The patient on ophthalmological exam

OPEN ACCESS

*Correspondence:

Thersilla Oberbarnscheidt, Department of Psychiatry, Western Psychiatric Hospital, University of Pittsburgh, UPMC Health, Pittsburgh, PA, USA, Tel: 5178970917;

E-mail: Toberbarnscheidt@gmail.com

Received Date: 29 Sep 2022

Accepted Date: 28 Oct 2022

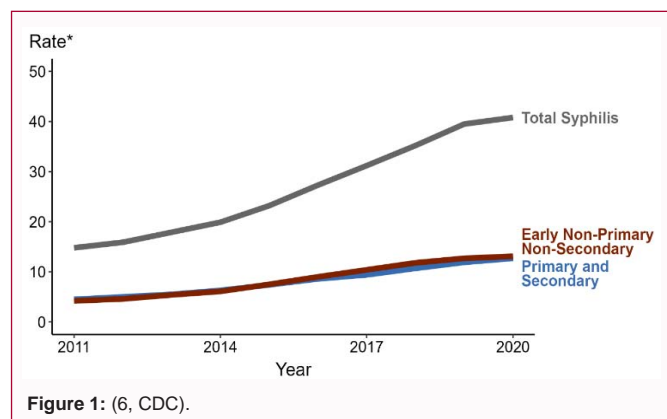
Published Date: 02 Nov 2022

Citation:

Oberbarnscheidt T, Khurana E. Misdiagnosed Diplopia in a Patient with Neurosyphilis. *Ann Clin Case Rep.* 2022; 7: 2330.

ISSN: 2474-1655.

Copyright © 2022 Thersilla Oberbarnscheidt. This is an open access article distributed under the Creative Commons Attribution License, which permits unrestricted use, distribution, and reproduction in any medium, provided the original work is properly cited.



had prolonged bilateral posterior uveitis and rash. There were no signs of otosyphilis, focal neurologic deficits, or syphilitic meningitis. The serum syphilis screen showed syphilis IgG/IgM positive, RPR reactive, RPR titer 128. HIV 1+2 neg, Hepatitis serology negative, *Chlamydia trachomatis*, *Neisseria gonorrhoeae* negative. The patient underwent lumbar puncture. The Cerebrospinal-Fluid (CSF) appeared clear and colorless. The CSF showed elevated protein (54 mg/dl), white blood cells were elevated at 35/mmE, lymphocytic predominance (80%) versus neutrophils 3%, HIV nonreactive, HCV negative. The patient's urine drug screening was positive for amphetamines, marijuana and patient reported crystal meth use a few days prior to admission. No brain imaging study was completed during hospitalization. Patient did have penicillin G challenge with monitoring in the intensive care unit due to history of allergy, with no reactions/side effects. The infectious disease consult recommended intravenous Penicillin G 24 million units' continuous infusion for 14 days (2/5/22 - 2/18/22), followed by Penicillin benzathine injection 2/19/22 post-intravenous course. Patient had a Peripherally Inserted Central Catheter (PICC line) placed. Unfortunately, no home health nursing available for patient as he could not discharge safely to home or skilled nursing facility with PICC due to recent methamphetamine use. Patient remained inpatient to continue continuous intravenous antibiotics until completion of treatment on 2/19/22. He tolerated treatment well. Additionally, he was diagnosed with likely past Lyme disease infection with +IgG and negative IgM for Lyme and reported erythema migrans 2 years ago. Patient denied any symptoms of arthritis, joint swelling, or peripheral neuropathy. However, treatment was recommended per infectious disease to minimize risk of further manifestation. He received oral doxycycline during hospitalization, and this was prescribed to his pharmacy to continue until completed course. He was prescribed Doxycycline 100 mg twice daily through 2/24/22 (x 5 days, to complete 21-day course) to complete the treatment of Lyme.

Discussion

The rate of syphilis infections has been increasing over the last several years, especially in immunocompromised patients with AIDS/HIV. Neurosyphilis is a later stage of the disease when the central nervous system is affected. The spirochete *Treponema pallidum* can infect different areas of the brain such as meninges, brainstem, spinal cord or cerebellum, spinal cord, or vasculature. There are increasingly atypical presentations reported [4,5] of neurosyphilis as in our case with isolated blurred vision but co-occurring psychiatric dual diagnosis presentation which complicated the diagnosis and delayed treatment.

Conclusion

Patients with neurosyphilis can present with neurological or psychiatric symptoms. Utilizing the available serological screening tests for syphilis is important to make the diagnosis. Neuroimaging studies should be considered as well, and treatment should be initiated as soon as possible.

References

1. Franzen C. Syphilis in composers and musicians- Mozart, Beethoven, Paganini, Schubert, Schumann, Smetana. Eur J Clin Microbiol Infect Dis. 2008;27(12):1151-7.
2. Lukehart SA, Hook EW III, Baker-Zander SA, Collier AC, Critchlow CW, Handsfield HH. Invasion of the central nervous system by *Treponema pallidum*: Implications for diagnosis and treatment. Ann Intern Med. 1988;109:855-62.
3. National Academies of Sciences, Engineering, and Medicine 2021. Sexually Transmitted Infections: Adopting a sexual health paradigm. Washington, DC: The National Academies Press.
4. St. Cyr S, Barbee L, Workowski KA, Laura HB, Cau P, Karen S, et al. Update to CDC's Treatment Guidelines for Gonococcal Infection, 2020. MMWR Morb Mortal Wkly Rep. 2020;69(50):1911-6.
5. Mitsonis C, Kararizou E, Dimopoulos N, Triantafyllou N, Kapaki E, Mitropoulos P, et al. Incidence and clinical presentation of neurosyphilis: A retrospective study of 81 cases. Int J Neurosci. 2008;118:1251-7.
6. Syphilis — Rates of reported cases by stage of infection, United States, 2011–2020.
7. Skalnaya A, Forminykh V, Ivashchenko R, Averchenkov D, Grazhdantseva L, Frigo N, et al. Neurosyphilis in the modern era: Literature review and case series. J Clin Neurosci. 2019;69:67-73.