Annals of Clinical Case Reports

Case Report
Published: 27 Jul, 2020

Life-Threatening Infectious Aortitis with Methicillin-Resistant *Staphylococcus aureus* (MRSA) Bacteremia in a Woman with Type 2 Diabetes Mellitus

Cheng Han[1], Yuan-Hung Wang[1], Ruei-Lin Wang[1], Kun-Lin Wu[1,2], Chung-Chi Yang[1]* and Po-Jen Hsiao[1,2]*

[1]Department of Internal Medicine, Taoyuan Armed Forces General Hospital, Taiwan

[2]Department of Internal Medicine, Tri-Service General Hospital, Taiwan

Abstract

Infectious aortitis can cause life-threatening complications in clinical practice. Here in, we present an educational case of Infectious aortitis with Methicillin-Resistant *Staphylococcus aureus* (MRSA) bacteremia in a Woman. The 84-year-old woman was admitted to the hospital due to intermittent fever for 5 days. Her temperature was 38.5°C, and chest X-ray demonstrated tortuosity of aorta with calcification of aortic arch. Her blood cultures subsequently all grew Methicillin-Resistant *Staphylococcus aureus* (MRSA) during hospitalization. Her echocardiography revealed no vegetation, but the symptoms of chest tightness and shortness of breath were noted. A follow-up contrast enhanced computed tomography (CT) scan demonstrated thickening of the wall of descending aorta that measured 0.8 cm, which was indicative of infectious aortitis.

Keywords: Infectious aortitis; Bacteremia; CT; *Staphylococcus aureus*

OPEN ACCESS

Correspondence:
Po-Jen Hsiao, Department of Internal Medicine, Division of Nephrology, Taoyuan Armed Forces General Hospital, No.168, Zhongxing Rd., Longtan Dist., Taoyuan City 325, Taiwan, Tel: +886-3-4799595; Fax: +886-3-4801625;
E-mail: a2005a660820@yahoo.com.tw
Chung-Chi Yang, Department of Internal Medicine, Division of Cardiology, Taoyuan Armed Forces General Hospital, No.168, Zhongxing Rd., Longtan Dist., Taoyuan City 325, Taiwan, Tel: 886-3-4799595; Fax: 886-3-4801625;
E-mail: ycc1@aftygh.gov.tw

Received Date: *29 Jun 2020*
Accepted Date*: 22 Jul 2020*
Published Date*: 27 Jul 2020*

Citation:
Han C, Wang Y-H, Wang R-L, Wu K-L, Yang C-C, Hsiao P-J. Life-Threatening Infectious Aortitis with Methicillin-Resistant Staphylococcus aureus (MRSA) Bacteremia in a Woman with Type 2 Diabetes Mellitus. Ann Clin Case Rep. 2020; 5: 1868.

ISSN: 2474-1655

Copyright *© 2020 Chung-Chi Yang and Po-Jen Hsiao. This is an open access article distributed under the Creative Commons Attribution License, which permits unrestricted use, distribution, and reproduction in any medium, provided the original work is properly cited.*

Introduction

Under normal situations the aorta is resistant to infections; infectious aortitis is uncommon but potentially be life-threatening. Including trauma, atherosclerotic ulcers, and cystic necrosis of the intima can cause infection of the aorta. The infectious state can occur and pass to the aorta from blood or surrounding tissues. Including diabetes mellitus, vascular malformations, and other invasive catheterization are clinical risk factors [1]. Such as mycotic aneurysm, infectious pseudoaneurysms, infected preexisting aneurysms, and infectious aortitis, all these cases are usually serious and require further surgical intervention.

Case Presentation

An 84-year-old woman was admitted to our hospital due to intermittent fever for 5 days. She had medical history of type 2 diabetes mellitus, hypertensive cardiovascular disease, and old cerebrovascular accident with regular outpatient clinic (OPD) follow-up. She had no history of traumatic injury. Physical examination revealed her temperature was 38.7°C, and the cardiovascular hemodynamics was stable initially. The white cell count was 17,600/μL, C-reactive protein (CRP) level was 15 mg/dl, and other blood tests were unremarkable. Chest X-ray demonstrated mild calcification of aortic arch. Her blood cultures subsequently all grew Methicillin-Resistant *Staphylococcus aureus* (MRSA). Intravenous antibiotic of vancomycin was administrated. A transthoracic echocardiogram (TTE) revealed no obvious vegetation. Around one week after admission, the symptoms of shortness of breath were noted. The electrocardiograms (ECG) demonstrated sinus tachycardia, a follow-up chest X-ray showed progressive mediastinal widening. Contrast enhanced Computed Tomography (CT) scan demonstrated thickening of the wall of descending aorta that measured 0.5 to 0.8 cm, indicative of aortitis (Figure 1). Finally, the clinical diagnosis of infectious aortitis was made. The family signed the do no resuscitation (DNR) due to old age of this patient. Unfortunately, she experienced sudden cardiovascular collapse and expired without further intensive surgical intervention.

Discussion

We present an educational case of life-threatening infectious aortitis with Methicillin-Resistant Staphylococcus Aureus (MRSA) bacteremia in a woman with type 2 diabetes mellitus.

In general, several mechanisms can cause infectious aortitis including: (a) direct bacteremic

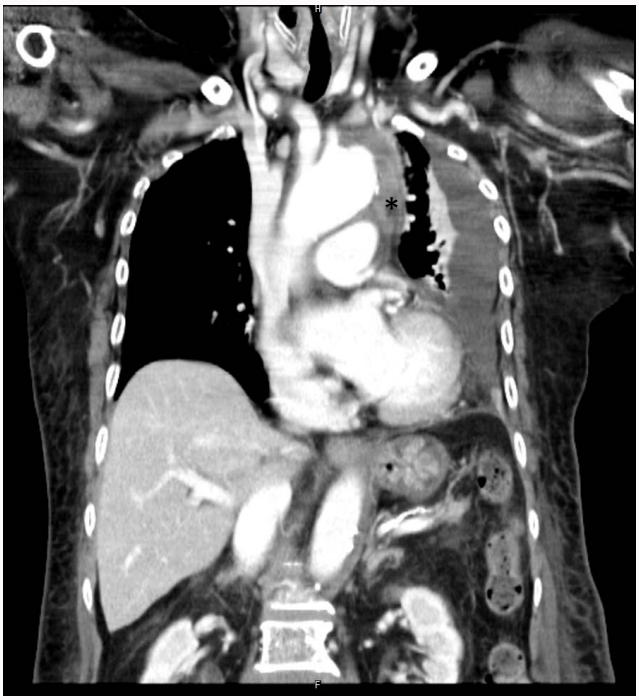

Figure 1: Contrast enhanced CT (coronal view) revealed thickening (*) of the wall of descending aorta

seeding with intimal injury, (b) septic emboli, (c) continuous infection extending to the aorta wall, and (d) traumatic injury, such as a penetrating injury [1-4]. The diagnosis of infectious aortitis is usually made based on imaging studies and the clinical symptoms of infection (fever, associated with chest, abdominal or back pain). However, the accurate diagnosis may be delayed and is confirmed by the culturing organisms from the blood or surgical specimens. Timely surgical intervention should be performed as soon as possible when the patients with impending aortic rupture or uncontrolled sepsis. CT scan and Magnetic Resonance Imaging (MRI) are helpful diagnostic tools and may demonstrate rapid aneurysm development, peri-aortic soft-tissue mass and peri-aortic gas (in advanced cases) [1-7]. To the best of our knowledge, the management of infectious aortitis may still be challenging in clinical practice [ex: the concerning type of reconstruction (*in situ*/extra-anatomic), the type of the graft and endovascular methods, or duration of antibiotic administration]. Early diagnosis and appropriate treatment including surgical management can improve clinical outcomes.

Acknowledgement

We thank the patient's consenting to publish the clinical information. This work is supported by grants from the Research Fund of the Taoyuan Armed Forces General Hospital (AFTYGH-D-109-009).

References

1. Lopes RJ, Almeida J, Dias PJ, Pinho P, Maciel MJ. Infectious thoracic aortitis: a literature review. Clin Cardiol. 2009;32(9):488-90.
2. Ramirez FD, Jamison BM, Hibbert B. Infectious Aortitis. Int Heart J. 2016;57(5):645-8.
3. Yuan SM, Lin H. Aortitis Presenting as Fever of Unknown Origin. Ann Thorac Cardiovasc Surg. 2018; 20;24(6):279-87.
4. Macedo TA, Stanson AW, Oderich GS, Johnson CM, Panneton JM, Tie ML. Infected aortic aneurysms: imaging findings. Radiology. 2004;231(1):250-7.
5. Alomari IB, Hamirani YS, Madera G, Tabe C, Akhtar N, Raizada V. Aortic intramural hematoma and its complications. Circulation. 2014;129(6):711-6.
6. Martin Haensig. Type B intramural hematoma: focus on reasons for development and overlapping clinical disease. Ann Cardiothorac Surg. 2019; 8(4):494-6.
7. Tanaka A, Estrera AL. Infectious aortitis: A bridge too far. J Thorac Cardiovasc Surg. 2018;155(3):e93-e94.