Annals of Clinical Case Reports

Case Report
Published: 27 Apr, 2017

Is it Feasible to Concomitantly Resect Gastric Gastrointestinal Stromal Tumor during Bariatric Laparoscopic Sleeve Gastrectomy?

*Muhammad Al-Zetawi, Hisham Shabani and Samer Al Sawalhi**

Department of Surgery, Al-Essra' Hospital, Amman, Jordan

Abstract

Laparoscopic Sleeve Gastrectomy (LSG) is one of the bariatric procedures used to ameliorate multiple comorbidities associated with obesity. Moreover, the incidence of Gastrointestinal Stromal Tumors (GISTs) has been found to be more in obese patients. We noticed incidentally a round shape mass, 3 cm x 3 cm in size in the anterior wall of the stomach, closer to the lesser curvature during LSG. The mass was resected successfully laparoscopically with guidance of the endoscope. The frozen section result confirmed the presence of GIST tumor with free margins. GISTs wedge resection during LSG can be done safely depending on the location of the tumor.

Keywords: Laparoscopic sleeve gastrectomy(LSG); Roux-en-Y gastric bypass (RYGB); Gastrointestinal stromal tumors (GISTs); Gastrointestinal (GI); Body Mass Index (BMI)

Introduction

Laparoscopic Sleeve Gastrectomy (LSG) is considered one of the treatment options to ameliorate co-morbidities associated with obesity [1]. However, incidental pathological findings can create a dilemma that may alter the surgical plan. Gastric Gastrointestinal Stromal Tumors (GISTs) are spindle-cell, epitheloid, or, occasionally, pleomorphic mesenchymal tumors that typically arise in the gastrointestinal tract from interstitial pacemaker cells of Cajal and account for <3% of all gastrointestinal neoplasms [2]. GISTs are caused by mutations in the c-kit tyrosine kinase protein or in platelet-derived growth factor receptor alpha (PDGFRα) [3]. Special attention must be paid by surgeons performing LSG, as gastric GISTs are most commonly located in the upper half of the stomach, in accordance with the distribution of interstitial cells of Cajal [4]. Laparoscopic resection of gastric GISTs has been proven to be both safe and effective [5].

Case Presentation

A 34-year-old man who had failed dietary modification for obesity visited our clinic for weight reduction. He complained of low back pain present for the previous 6 months and was advised to lose weight. Upon examination, his calculated body mass index was 40.4 (kg/m^2), (weight, 110 kg; height, 165 cm). We discussed options for weight reduction and decided to perform laparoscopic sleeve gastrectomy (LSG). His values for preoperative tests were all within normal limits except for the presence of fatty liver detected by abdominal ultrasound. A preoperative barium swallow did not demonstrateany gastric mucosal abnormalities. The patient did not complain of symptoms related to gastroesophageal reflux disease. Informed consent was obtained, and the patient was admitted for LSG. Per usual, five trocars were inserted (two 5 mm trocars into the epigastrium and left anterior axillary line, two 12 mm trocars into the right and left midclavicular line, and one10 mm trocar between the xiphisternum and the umbilicus). After devascularization of the greater curvature of the stomach and insertion of a size 40 bougie, we noticed a lesion in the anterior wall of the stomach, close to the lesser curvature and in the mid-gastric body. The lesion was rounded in shape, 3 cm x 3 cm in size, covered with serosa, and not ulcerated (Figure 1).

Intraoperative Upper Gastrointestinal (GI) endoscopy was performed to exclude the presence of any mucosal involvement, to assess the adequacy of the resected margins, and to avoid luminal narrowing. The endoscopy showed that the mass was located submucosally without ulceration. After discussion with the patient's family, the decision was made to laparoscopically resect the mass using an endoscopic gastrointestinal anastomotic (endo GIA 60, Tri-Stapler Technology–Medtronic,USA) stapler, which was performed successfully underboth laparoscopic and endoscopic vision. The mass

OPEN ACCESS

Correspondence:
Samer Al Sawalhi, Department of surgery, Al-Essra' Hospital, P O Box 1817-11941) Queen Rania St, Amman, Jordan,
E-mail: drsawalhi@yahoo.com

Received Date: *03 Apr 2017*
Accepted Date*: 25 Apr 2017*
Published Date*: 27 Apr 2017*

Citation:
Al-Zetawi M, Shabani H, Al Sawalhi S. Is it Feasible to Concomitantly Resect Gastric Gastrointestinal Stromal Tumor during Bariatric Laparoscopic Sleeve Gastrectomy?. Ann Clin Case Rep. 2017; 2: 1346.

ISSN: 2474-1655

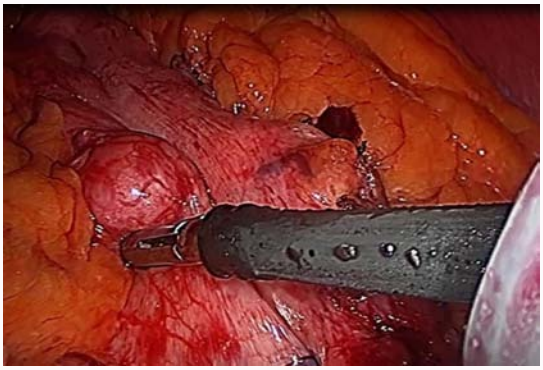

Figure 1: A lesion was rounded in shape, 3 cm x 3 cm in size, covered with serosa, and not ulcerated in the anterior wall of the stomach, close to the lesser curvature and in the mid-gastric body.

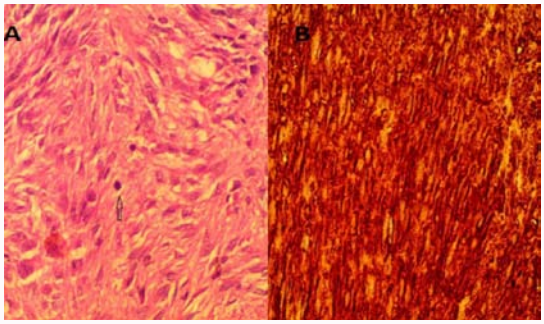

Figure 2: (A) Histopathologic evaluation of the resected specimen showed a cellular tumor composed of spindle shaped cells arranged in bundles and fascicles with many ovals to elongated nuclei. No necrosis is seen (B) Immunostaining positive for CD117 and CD34. The mitotic count was 4/10 cells in a high-power field.

was pulled anteriorly, and a 60 mm endo GIA was used for wedge resection. The specimen was retrieved in an (endocatch Gold 10 mm Covidien, USA) without spillage. We waited for frozen sections, which confirmed the diagnosis of GIST (Figure 2). We continued with a sleeve resection of the greater curvature of the stomach using the (endo GIA 60, Tri-Stapler Technology –Medtronic, USA) after calibration with a 40Fr bougie. Intraoperatively, we tested the integrity of the sleeve by injecting methylene blue dye (which was negative for leakage), and an intra-abdominal drain was inserted. The resected GIST staple line was not included in the resected specimen as it was anteriorly located near the lesser curvature. The patient underwent a Gastrografin upper GI study on the third post-operative day torule out any leak or stenosis. The patient was discharged on the same day after drain removal and had an uneventful recovery.

Histopathologic evaluation of the resected specimen showed a gastric mass (GIST), 2 cm in size with free margins (with a minimum margin of 1 cm). The mass was found to be a low-grade GIST that stained positive for CD117 and CD34 but was negative for actin. The mitotic count was 4/10 cells in a high-power field (Figure 2), therefore based on the tumor size and mitotic figure, it considered low risk for recurrence and metastasis.

The patient returned for follow-up at 1and 6 months. Upper gastrointestinal endoscopy and a computed tomography scan were negative for recurrence or metastasis. There was no local or port site recurrence. The patient did not receive post-operative imatinib mesylate due to a low risk of recurrence according to the National Comprehensive Cancer Network (NCCN) guidelines version 2, 2017 [6].

Discussion

The incidence of GIST has been proposed to be higher in patients with obesity (0.6-0.8%) compared to the generalpopulation (0.0006-0.0015%) [7,8]. GIST's are difficult to diagnose preoperatively despite routine upper GI barium tests for all of our patients. Moreover, it has been shown that routine upper GI endoscopy prior to surgery is not reliable for identifying GISTs [9]. Surgery is the first-line therapy for patients with primary resectable GISTs. The objective of surgical resection of a primary GIST is complete gross resection without rupturing the tumor pseudo capsule [3]. Novitsky "et al." [10] demonstrated that a laparoscopic approach appears to offer excellent therapeutic outcomes, with a long-term disease-free survival for patients with gastric GIST tumors of various sizes (1.0 cm to 8.5 cm) up to 92%. Additionally Tabrizian "et al." [11] Showed that patients undergoing laparoscopic wedge GIST resection have an overall survival rate of 89% and an overall disease-free survival rate of 77% for gastric GISTs, with a recurrence rate of 6%.

Recent reports from the National Comprehensive Cancer Network (NCCN) recommended that a laparascopic approach may be considered for selected GISTs in favorable anatomic location (greater curvature or anterior wall of stomach) by surgeons with appropriate laparascopic experience [6]. It has been recommended that before resection, both the anterior and posterior surfaces of the stomach be examined with care. Because some masses are embedded in fat, a tumor in the lesser curvature might not be recognized. If a GIST is found during surgery, the entire abdominal cavity and particularly the liver should also be inspected for metastasis and secondary tumors [7].

The presence of a tumor on the lesser curvature poses a challenge and may necessitate a change in the surgical plan from LSG to RYGB or even termination of the procedure altogether [7] in favor of an appropriate method of tumor excision. In the case detailed here, we noticed the gastric mass after inserting the bougie, and it was therefore more practical to explore the stomach surface after its insertion. The tumor size and mitotic rate are used as a guide to predict the malignant potential of GISTs, although it is notoriously difficult to predict the biological behavior of GISTs based on pathologic features a lone [6].

In the case of the patient described here, the tumor was considered low risk. Therefore, resection with a safe margin was curative, and imatinib was not indicated according to the NCCN guidelines [6]. We decided to perform abdominal computed tomography scanning 6 months after surgery and again yearly.

According to the European Society for Medical Oncology consensus recommendations, GISTs should be considered for molecular analysis for *KIT* or *PDGFR*-α mutations [12]. Experts recommend genotyping for all high risk patients, primary imatinib resistance and metastatic GISTs [13]. Low-risk tumors and those fully resected do not require this type of testing.

The limitation of our case is that we were unable to diagnose the tumor prior to surgery, as we do not routinely perform upper endoscopy before bariatric surgery except for symptomatic patients and patients undergoing gastric bypass. Still, the significance of routine pre-operative screening by upper GIT endoscopy in

asymptomatic patients remains debatable [8].

Conclusion

GIST wedge resection during laparoscopic sleeve gastrectomy can be performed safely, depending on the location of the tumor. The surgeon should explore the precise location of the lesion to assess the feasibility of sleeve gastrectomy without causing narrowing or tortuosity in the stapler line. Concomitant sleeve gastrectomy and tumor resection is feasible with a laparoscopic approach, giving priority to adequate tumor excision.

References

1. Gender Influence on Long-Term Weight Loss and Comorbidities after Laparoscopic Sleeve Gastrectomy and Roux-en-Y Gastric Bypass: a Prospective Study With a 5-Year Follow-up. Obesity Surgery. 2016;26(2):276–81.
2. Sasaki A, Koeda K, Obuchi T, Nakajima J, Nishizuka S, Terashima M, et al. Tailored laparoscopic resection for suspected gastric gastrointestinal stromal tumors. Surgery. 2010;147(4):516-20.
3. Sawalhi S, Al-Harbi K, Raghib Z, Abdelrahman AI, Al-Hujaily A. Behavior of advanced gastrointestinal stromal tumor in a patient with von-Recklinghausen disease: Case report. World J Clin Oncol. 2013;10(4):70-4.
4. Yun HY, Sung R, Kim YC, Choi W, Kim HS, Kim H, et al. Regional Distribution of Interstitial Cells of Cajal (ICC) in Human Stomach. Korean J Physiol Pharmacol. 2010;14(5):317-24.
5. Julio Sokolich, Christos Galanopoulos, Ernest Dunn, Jeffrey D. Linder, et al. Expanding the Indications for Laparoscopic Gastric Resection for Gastrointestinal Stromal Tumors. JSLS. 2009;13(2):165–9.
6. NCCN guidelines. Gastrointestinal stromal tumors (GIST). version 2, 2017.
7. Yuval JB, Khalaileh A, Abu-Gazala M, Shachar Y, Keidar A, Mintz Y, et al. The true incidence of gastric GIST-a study based on morbidly obese patients undergoing sleeve gastrectomy. Obes Surg. 2014;24(12):2134-7.
8. Sanchez BR, Morton JM, Curet MJ, Alami RS, Safadi BY. Incidental finding of gastrointestinal stromal tumors (GISTs) during laparoscopic gastric bypass. Obes Surg. 2005;15(10):1384–8.
9. De Palma GD, Forestieri P. Role of endoscopy in the bariatric surgery of patients. World J Gastroenterol. 2014;20(24):7777-84.
10. Novitsky YW, Kercher KW, Sing RF, Heniford BT. Long-term outcomes of laparoscopic resection of gastric gastrointestinal stromal tumors. Ann Surg. 2006;243(6):738-45.
11. Tabrizian P, Nguyen SQ, Divino CM. Laparoscopic management and longterm outcomes of gastrointestinal stromal tumors. J Am Coll Surg. 2009;208(1):80-6.
12. ESMO/European Sarcoma Network Working Group. Gastrointestinal stromal tumors: ESMO Clinical Practice Guidelines for diagnosis, treatment and follow-up. Ann Oncol. 2012;23(7): vii49–55.
13. Debiec-Rychter M, Dumez H, Judson I, Wasag B, Verweij J, Brown M, et al. Use of c-KIT/PDGFRA mutational analysis to predict the clinical response to imatinib in patients with advanced gastrointestinal stromal tumours entered on phase I and II studies of the EORTC Soft Tissue and Bone Sarcoma Group. Eur J Cancer. 2004;40(5):689–95.