Annals of Clinical Case Reports

Case Report
Published: 05 Jun, 2017

Intraductal Extracapsular Rupture of Silicone Breast Implant

Carl Seynnaeve and Wendie Berg*

Department of Radiology, University of Pittsburgh Medical Center, USA

Abstract

Complications of silicone implant rupture are commonly encountered, both clinically and by imaging. An unusual type of rupture with intraductal spread of silicone has only been described in a few case reports. The following is a case of intraductal spread of silicone illustrated by mammography, ultrasonography (US), and Magnetic Resonance (MR) imaging.

Case Presentation

Our case is a 69-year-old female who presented for a diagnostic mammogram in the summer of 2015 with complaint of hardening of the right breast and implant for three weeks. She carried a complex history of breast augmentation with multiple revisions, which started in her twenties. Her most recent revision was in 2007, which included bilateral exchange of silicone implants secondary to rupture with placement of bilateral silicone implants in a subglandular position. The mammographictechnologist who performed thecurrent diagnostic mammogramnoted a small amount of golden discharge from the right nipple during performance of the implant-displaced views, which could not be reproduced by the radiologist physician at the time ofultrasound. Mammography (Figure 1) and ultrasound (US) (Figure 2) demonstrated spread of silicone in the soft tissues anterior to the implant in a ductal distribution. Because the patient desired implant removal, Magnetic Resonance Imaging (MRI) was also performed (Figure 3), confirming intraductal spread of silicone.

The patient was subsequently seen in the Plastic Surgery office, where a small amount of silicone gel was able to be extruded from the right nipple. Following evaluation, implant exchange was recommended. For personal reasons, the patient delayed surgery and presented months later

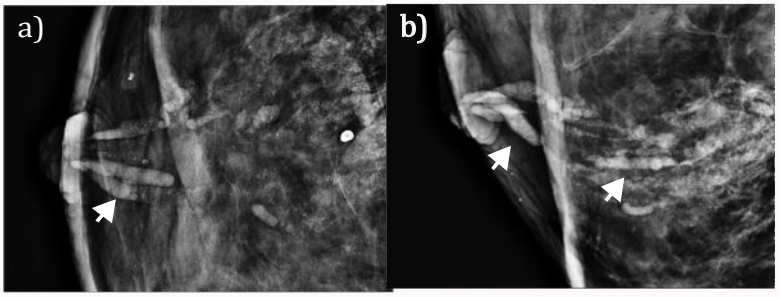

Figure 1: Magnification (a) Craniocaudal (b) mediolateral rightimplant-displaced mammograms show dense, tubular material within multipleducts (arrows) leading to the nipple. Scar is also evident.

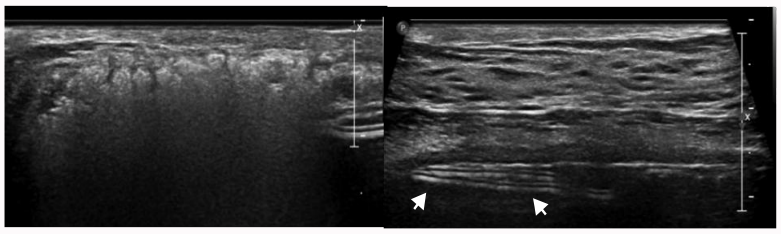

Figure 2: Ultrasound (US). Top image illustrates the typical "snowstorm" appearance of diffuse echogenic extracapsular silicone with posterior shadowing near the nipple. Bottom image illustrates the "stepladder sign" (arrows) indicative of collapse of the implant shell.

OPEN ACCESS

Correspondence:
Carl Seynnaeve, Department of Radiology, University of Pittsburgh Medical Center, 259 Mt Nebo Pointe Dr, Pittsburgh, PA 15237, USA, E-mail: seynnaeveca@upmc.edu

Received Date: *18 Mar 2017*
Accepted Date*: 31 May 2017*
Published Date*: 05 Jun 2017*

Citation:
Seynnaeve C, Berg W. Intraductal Extracapsular Rupture of Silicone Breast Implant. Ann Clin Case Rep. 2017; 2: 1369.

ISSN: 2474-1655

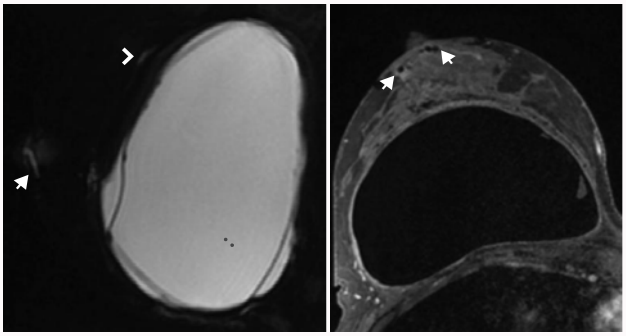

Figure 3: (a) Magnetic resonance imaging (MRI). Sagittal T2-weighted,water-suppressed silicone-brightimage (TR=3167, TE=53, TI=150) illustrates bright signal within a lactiferous duct (arrow) that matches the signal of the silicone implant. There is gel outside the implant capsule (arrowhead), consistent with extracapsular rupture and the hypointense implant shell (dotted arrow) has separated from the capsule. (b) Axial T1-weighted fat-and silicone suppressed, post-contrast sequence (TR=7, TE=3) illustrates foci of signal void within the lactiferous ducts (arrows) that matches the signal of the silicone implant.

with evidence of a right breast infection and a sinus tract to the skin. The patient then underwent removal of ruptured silicone implant on the right and intact silicone implant on the left with bilateral capsulectomy, as well as excision of the sinus tract and silicone granulomas within the right breast.Following months of healing, she underwent bilateral breast augmentation with silicone implants.The patient has not undergone post-procedure breastimaging.

Discussion

Intraductal spread of silicone following implant ruptureis a known but uncommonly seen entity. In the majority of implant ruptures, the gel is contained by the fibrous capsule the body forms around the implant, so-called "intracapsular ruptures". When the gel spreads outside the fibrous capsule, it can migrate to the axillae, the back, arms, and even groin. Migration of gel is accompanied by inflammation and silicone granuloma formation [1-3]. These granulomas represent a natural host response to wall off a foreign substance, and silicone can be a nidus for fistula formation and subsequent infection [4]. Thus, diagnosis and subsequent timely removal of extracapsular silicone is considered desirable so as to minimize complications, including an increased risk of fibromyalgia [3].Mammography, US, and MRI are all useful modalities to help detect extracapsular silicone implant rupture [5,6].

Mammography is reliable and readily available, with silicone appearing as a dense opacity. Extracapsular silicone can be seen as round or oval masses of varying size adjacent to or separate from the implant. A tubular appearance due to intraductal spread as seen in this case (Figure 1) is uncommon.Mammography does have some limitations, including the inability to confidently distinguish silicone from other high-density masses, and positioning limitsmammographic evaluation to the breast and included portions of the axilla [5]. Intracapsular silicone implant ruptureis nearly always mammographically occult. Mammography, including implant-displaced views, remains the primary method of screening for breast cancer, though a metaanalysis showed a slight increased risk (1.2-fold) of late-stage diagnosisin women with implants, likely due to masking of some cancers on mammography [7].

US is also reliable in depicting extracapsular implant rupture, is widely available, and easier to correlate with physical examination findings not limited to the breast itself. The classic US appearance of extracapsular silicone is a highly echogenic pattern with a well-defined anterior margin and loss of detail posteriorly with shadowing, commonly referred to as a "snowstorm appearance" (Figure 2) [8]. Collapse of the implant shell can be recognized at the anterior aspect of the implant ("stepladder sign") but may be focal or posterior and not well seen on US and separation of the shell from the fibrous capsule in uncollapsed rupture can be quite subtle on US; the accuracy of the examination depends on the ability of the operator to recognize and interpret the abnormal findings [5].While MR imaging is substantially more sensitive in the detection of implant rupture, the advantage in mapping extracapsular silicone is less well established [6,9]. One clear advantage of MR imaging is the ability to perform silicone-specific sequences [10]. Silicone will present as high signal on T2-weighted water-suppressed images (Figure 3a), and low signal intensity foci on T1-weighted fat-suppressed images (Figure 3b), though it is important to be aware of potential pitfalls with MR imaging of implants[11].MR imaging also affords a detailed evaluation of the breast, axilla, chest wall, and the implant, and can therefore be helpful for surgical planning purposes. A disadvantage unique to MR imaging isthe increased cost of the examination compared to mammography and US [5].

Our case of silicone implant rupture with intraductal spread of siliconewas documented with all three modalities, including mammography, US, and MR imaging, illustrating a rarely seen imaging finding with clinical relevance.

References

1. Leibman AJ, Kossoff MB, Kruse BD. Intraductal extension of silicone from a ruptured breast implant. Plast Reconstr Surg. 1991; 89: 546-547.
2. Shermis RB, Adler DD, Smith DJ, and Hall JD. Intraductal silicone secondary to breast implant rupture. Breast Dis. 1990; 3: 17.
3. Brown LS, Silverman BG, Berg WA. Rupture of silicone-gel breast implants: causes, sequelae, and diagnosis. The Lancet. 1997; 350: 1531-1537.
4. Klaus-Jürgen Walgenbach, Christiane Kuhl, Christian Rudlowski, Martin Poelcher, Axel Sauerwald, Gisela Walgenbach-Brünagel, et al. A Rare Complication Following Breast Implant Surgery: Capsular Contracture with a Cutaneous Silicone Fistula after Breast Reconstruction with Silicone Gel Implants. Breast Care (Basel). 2011; 6: 51-53.
5. Caskey CI, Berg WA, Hamper UM, Sheth S, Chang BW, Anderson ND. Imaging spectrum of extracapsular silicone: correlation of US, MR imaging, mammographic, and histopathologic findings. Radiographics. 1999; 19 Spec No :S39–S51; quiz S261–S262.
6. Berg WA, Caskey CI, Hamper UM, Kuhlman JE, Anderson ND, Chang BW, et al. Single- and double- lumen silicone breast implant integrity: prospective evaluation of MR and US criteria. Radiology. 1995; 197: 45-52.

7. Eric Lavigne, Eric J Holowaty, Sai Yi Pan, Paul J Villeneuve, Kenneth C Johnson, Dean A Fergusson, et al. Breast cancer detection and survival among women with cosmetic breast implants: systematic review and meta-analysis of observational studies. BMJ. 2013; 346: f2399.

8. Harris KM, Ganott MA, Shestak KC, Losken HW, Tobon H. Silicone implant rupture: Detection with US. Radiology. 1993; 187: 761-768.

9. Song JW, Kim HM, Bellfi LT, Chung KC. The effect of study design biases on the diagnostic accuracy of magnetic resonance imaging for detecting silicone breast implant ruptures: a meta-analysis. Plast Reconstr Surg. 2011; 127: 1029-1044.

10. Ma J, Choi H, Stafford RJ, Miller MJ. Silicone-specific imaging using an inversion-recovery-prepared fast three-point Dixon technique. J Magn Reson Imaging. 2004; 19: 298-302.

11. Berg WA, Anderson ND, Zerhouni EA, Chang BW, Kuhlman JE. MR imaging of the breast in patients with silicone breast implants: normal postoperative variants and diagnostic pitfalls. AJR Am J Roentgenol.1994; 163: 575-578.