



## Familial Hypercholesterolemia with Cardiovascular Disease: A Case Report

Kexin Wang<sup>1</sup>, Tao Sun<sup>2</sup>, Xiaoping Zhang<sup>3</sup>, Hai Gao<sup>1\*</sup> and Xiaoyan Li<sup>3\*</sup>

<sup>1</sup>Department of Emergency, Beijing Anzhen Hospital, China

<sup>2</sup>Department of Cardiology, Beijing Anzhen Hospital, China

<sup>3</sup>Department of Lung & Blood Vessel Disease, Beijing Institute of Heart, China

### Abstract

Familial Hypercholesterolemia (FH) is one of the most common autosomal codominant diseases. Patients with FH have elevated Low-Density Lipid Cholesterol (LDL-C) levels which lead to cardiovascular complications at an early age and a reduced life expectancy. Low-Density Lipoprotein Receptor (LDLR) gene mutation is the most common genetic cause of FH. In this study, a 56-year-old female with definite FH was reported based on clinical algorithms. Whole exome sequencing identified a heterozygous LDLR mutation (c.1599G>A), which is pathogenic according to ACMG guidelines. Sanger sequencing was performed in family members, and the mutation site was co-segregated with the disease in the family.

**Keywords:** Familial hypercholesterolemia; Cascade screening; Whole exome sequencing

### Introduction

Familial Hypercholesterolemia (FH) has been identified as an autosomal dominant disorder and is a major contributor to premature Atherosclerotic Cardiovascular Disease (ASCVD). Mutations in four genes have been reported to be responsible for an estimated 70% to 95% of FH: LDLR, Apo B, PCSK9, and LDLRAP. Additionally, LDLR mutation has been the most common cause [1-4]. This case reported a 56-year-old female with unstable angina and elevated plasma LDL-C level, carried a heterozygous pathogenic LDLR mutation (c.1599G>A), the patient was a definite FH according to DLCN criteria. The Sanger sequencing on the family members confirmed 3 members carried a heterozygous mutation in the previous site, and the clinical investigations were consistent with these quenching.

### Case Presentation

A 56-year-old female with unstable angina was performed Percutaneous Coronary Intervention (PCI). The Right Coronary Artery (RCA) was diffuse from the proximal segment to the distal segment, the proportion of three parts of the right coronary artery were 75%, 99% and 60%, respectively. 1 stent was placed in the RCA (Figure 1,2). Aspirin (100 mg/day), clopidogrel (75 mg/day), rosuvastatin (20 mg/day), metoprolol (47.5 mg/day), and isosorbide mononitrate (40 mg/day) were used after the intervention. After one year, the medications were adjusted to aspirin (100 mg/day), rosuvastatin (20 mg/day), ezetimibe (10 mg/day), and bisoprolol fumarate (10 mg/day).

The patient had been found a high level of blood lipid at the age of 35 (Table 1), but received treatment irregularly and the particular method was unknown. Without other conditions that could lead to secondary hypercholesterolemia or phytosterolemia. Whole exome sequencing was performed, and one candidate mutation was identified: LDLR (NM\_000527.4): c. 1599G>A (p. Trp533\*) (Figure 3). This mutation was pathogenic according to ACMG guidelines. Based on the patient's medical history, early on-set ASCVD family history and information of sequencing, a definite FH could be evaluated according to DLCN criteria.

Clinical investigation indicated that family members III1 had a high lipid level and ASCVD at the age of 56, II2 and III2 were found to have elevated LDL-C at the age of 51 and 41, respectively, but have no ASCVD yet (Table 1). The Sanger sequencing for 3 family members (III1, II2, III2) certified the heterozygous mutation. While III3 and IV1 were wild type.

Expect for family member III2, the other family members were treated with statins regularly and adjusted to statins and Ezetimibe combined lipid-lowering therapy after the effect was poor. So

### OPEN ACCESS

#### \*Correspondence:

Hai Gao, Department of Emergency, Beijing Anzhen Hospital, Capital Medical University, Beijing, 100029, China,

E-mail: gaohai71@hotmail.com

Xiaoyan Li, Department of Lung & Blood Vessel Disease, Beijing Institute of Heart, Beijing 100029, China, E-mail: xiaoyanli82@163.com

Received Date: 08 Jul 2021

Accepted Date: 22 Jul 2021

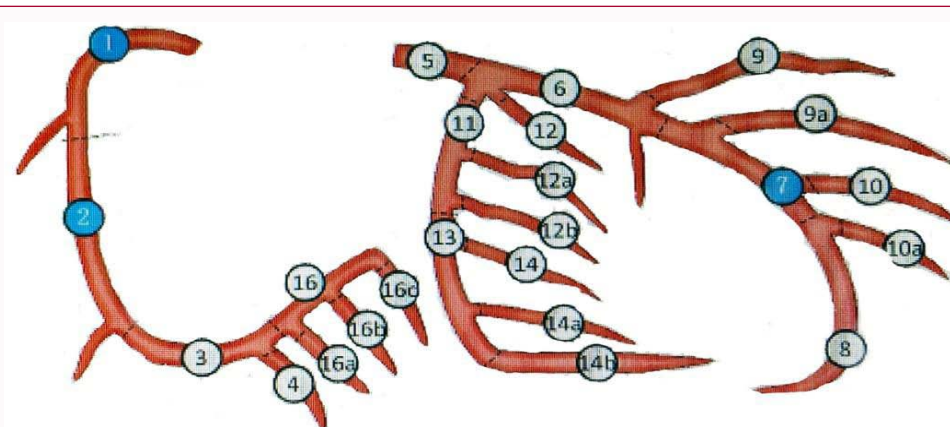
Published Date: 26 Jul 2021

#### Citation:

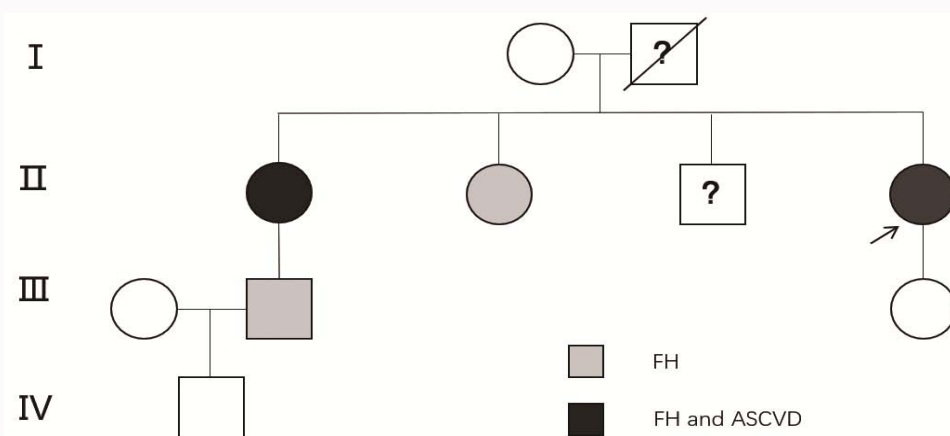
Wang K, Sun T, Zhang X, Gao H, Li X. Familial Hypercholesterolemia with Cardiovascular Disease: A Case Report. *Ann Clin Case Rep.* 2021; 6: 1954.

ISSN: 2474-1655

Copyright © 2021 Hai Gao and Xiaoyan Li. This is an open access article distributed under the Creative Commons Attribution License, which permits unrestricted use, distribution, and reproduction in any medium, provided the original work is properly cited.



**Figure 1:** Schematic diagram of coronary angiography of the patient. Blue marker: target lesion; LMA (Left Main Artery) was irregular, LAD (Left Anterior Artery) with 75% tubular stenosis in the middle segment; no significant stenosis of LCX (Left Circumflex Artery); the proportion of three parts of RCA (Right Coronary Artery) were 75%, 99% and 60%.



**Figure 2:** Pedigree of the patient. II4 was diagnosed as FH and ASCVD. Cascade screening for family members (II1, II2, III2 and IV1) found that II1, II2 and III2 was FH, II1 was diagnosed as CAD and received the PCI.

**Table 1:** Serum LDL-cholesterol level and diagnosis of the family.

	Sex M/F	Age/LDL-C (mmol/L)	Age/LDL-C (mmol/L)	Age of ASCVD	DLCN
Index patient (II4)	F	35y/5.6	58y/2.24	56y	Definite FH
The eldest sister (II1)	F	56y/6.06	67y/3.37	56y	Definite FH
The second elder sister (II2)	F	51y/7.19	58y/6.25	-	Definite FH
Nephew (III2)	M	39y/7.90	42y/6.85	-	Definite FH
Daughter (III3)	F	31y/normal	-	-	Unlikely FH

F: Female; M: Male; LDL-C: Low Density Lipoprotein Cholesterol; ASCVD: Arteriosclerotic Cardiovascular Disease; DLCN: Dutch Lipid Clinical Network criteria

far, no recurrence or occurrence of cardiovascular or cerebrovascular events has been reported.

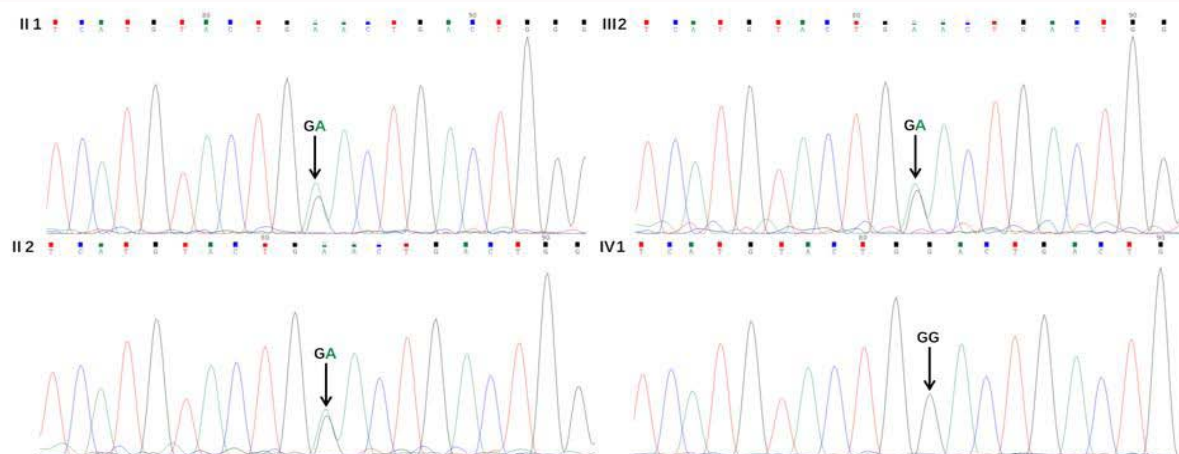
**Discussion**

The most common gene mutation that causes FH is LDLR. More than 3000 LDLR mutations have been reported in ClinVar [4-6]. There are many clinical criteria for FH, but genetic testing is still the gold standard for diagnosis [7]. In this case, a heterozygous LDLR mutation (c. 1599G>A) was identified by whole exome sequencing and Sanger sequencing for family members.

In this case, family members with heterozygous LDLR mutation have LDL-C level fluctuated between 5 mmol/L to 7.9 mmol/L which can be simply judged as heterozygous FH from the LDL-C level ≥

190 mg/dL (5 mmol/L) in an adult [7]. However, family members’ DLCN score classified as probable FH (score 7 to 8) before genetic sequencing. Positive sequencing results clarified their diagnoses were definite FH, and improved the efficiency of this cascade screening to some extent.

Early and appropriate lipid-lowering therapy is essential for patients with FH and ASCVD [8-10]. The index patient was irregularly used statin at age 35, and the reduction was unknown. After PCI and genetic sequencing, reduction inpatient who used statins and ezetimibe in combination with lipid-lowering during a year was 55.2% to 62.7%. Therefore, FH with heterozygous LDLR mutation (c. 1599G>A) may be suitable for combination lipid-lowering therapy with statins and ezetimibe. In addition, the family members (III,



**Figure 3:** Sanger sequencing for the candidate mutation of the family members. Whole exome sequencing for the index patient identified a mutation: LDLR (NM\_000527.4): c. 1599G>A (p. Trp533\*). The Sanger sequencing for family members, II1, II2 and III2 were found the heterozygous mutation in the candidate site. IV1 were wild type.

II2 and III2) used statins at the early stage. However, the reduction was 20.5% (II1), 15.1% (II2) and 13.3% (III2), the treatment adjusted to the combined lipid-lowering therapy of statins (20 mg/day) and ezetimibe (10 mg/day) after cascade screening. For family member III2, it is strongly suggested to strengthen lipid-lowering therapy, improve bad living habits, and further coronary CTA or coronary angiography can be carried out. After sequencing, family member III2 did reexamination that the LDL-C level is 4.12 mmol/L, the reduction is 47.8%. It was found that positive genetic confirmation of FH recognizes the importance, increases confidence in the role of lipid-lowering medicines, motivates initiation and adherence to lipid-lowering treatments.

In conclusion, comparing with traditional screening, cascade screening is more cost-effective. Genetic testing and cascade screening improve cognition and treatment adherence in FH patients. Besides, genetic testing to somewhat enhances the efficiency of cascade screening.

## Acknowledgement

We thank the patient and her family members for their interest and cooperation.

## Funding

The study was supported by the National Natural Science Foundation of China (81400846).

## Ethical Statement

The authors are accountable for all aspects of the work in ensuring that questions related to the accuracy or integrity of any part of the work are appropriately investigated and resolved. All procedures performed in studies involving human participants were in accordance with the Helsinki Declaration (as revised in 2013), and this study was approved by the ethics committee of the Beijing Anzhen Hospital of Capital Medical University. Written informed consent was obtained from the patient for publication of this case report and any accompanying images. A copy of the written consent is available for review by the Editor-in-Chief of this journal.

## References

- Benito-Vicente A, Uribe KB, Jebari S, Galicia-Garcia U, Ostolaza H, Martin C. Familial hypercholesterolemia: The most frequent cholesterol metabolism disorder caused disease. *Int J Mol Sci.* 2018;19(11):3426.
- Watts GF, Gidding SS, Mata P, Pang J, Sullivan DR, Yamashita S, et al. Familial hypercholesterolemia: Evolving knowledge for designing adaptive models of care. *Nat Rev Cardiol.* 2020;17(6):360-77.
- Defesche JC, Gidding SS, Harada-Shiba M, Hegele RA, Santos RD, Wierzbicki AS. Familial hypercholesterolaemia. *Nat Rev Dis Primers.* 2017;3:17093.
- Gidding SS, Champagne MA, de Ferranti SD, Defesche J, Ito MK, Knowles JW, et al. The agenda for familial hypercholesterolemia: A scientific statement from the American Heart Association. *Circulation.* 2015;132(22):2167-92.
- Iacocca MA, Chora JR, Carrié A, Freiburger T, Leigh SE, Defesche JC, et al. ClinVar database of global familial hypercholesterolemia-associated DNA variants. *Hum Mutat.* 2018;39(11):1631-40.
- Wang J, Dron JS, Ban MR, Robinson JF, McIntyre AD, Alazzam M, et al. Polygenic versus monogenic causes of hypercholesterolemia ascertained clinically. *Arterioscler Thromb Vasc Biol.* 2016;36(12):2439-45.
- Moldovan V, Banescu C, Dobreanu M. Molecular diagnosis methods in familial hypercholesterolemia. *Anatol J Cardiol.* 2020;23(3):120-27.
- Raal FJ, Hovingh GK, Catapano AL. Familial hypercholesterolemia treatments: Guidelines and new therapies. *Atherosclerosis.* 2018;277:483-92.
- Lee S, Akiyamen LE, Aljenedil S, Rivière JB, Ruel I, Genest J, et al. Genetic testing for familial hypercholesterolemia: Impact on diagnosis, treatment and cardiovascular risk. *Eur J Prev Cardiol.* 2019;26(12):1262-70.
- Hardcastle SJ, Legge E, Laundry CS, Egan SJ, French R, Watts GF, et al. Patients' perceptions and experiences of familial hypercholesterolemia, cascade genetic screening and treatment. *Int J Behav Med.* 2015;22(1):92-100.