Annals of Clinical Case Reports

Case Report
Published: 16 Dec, 2020

Extensive Subgaleal with Subperiosteal Abscess and Deep Neck Abscess Secondary to Ear Foreign Body - Uncommon Presentation

Riana Kipiani Abdul Halim[1,2,3], Hafeza Ahmad[3], Soo Mun Yee[3], Muhammad Hazim Abdul Ghafar[3] and Iskandar Hailani[3]*

[1]*Department of ORL-HNS, KPJ Healthcare University College, Malaysia*

[2]*Department of ORL-HNS, KPJ Selangor Specialist Hospital, Shah Alam, Selangor, Malaysia*

[3]*Department of Otorhinolaryngology, Hospital Kuala Lumpur, Wilayah Persekutuan Kuala Lumpur, Malaysia*

Abstract

A 36-year-old lady presented to our casualty with septic shock. She had four days history of fever, scalp swelling and poor oral intake. From the clinical findings, she was diagnosed left mastoiditis secondary to left ear foreign body complicated with extensive scalp and left deep neck abscesses. Computed tomography scans also showed left lateral skull base osteomyelitis changes. She was stabilized with inotrope infusion and fluids resuscitation. She was subjected to Intravenous (IV) antibiotics, abscesses drainage and regular ear cleaning. Mastoidectomy was performed later as she was refractory to the initial treatment. Conservative management as a first line treatment can reduce mastoidectomy related complications. However, mastoidectomy should be reserved for refractory cases and patients with associated cholesteatoma or intracranial complications. The purpose of the article is to discuss the uncommon presentation and on the mastoidectomy treatment for this case with its related literature review.

Keywords: Mastoiditis; Subperiosteal abscess; Subgaleal abscess; Deep neck abscess; Ear foreign body; Mastoidectomy; Skull base osteomyelitis

OPEN ACCESS

Correspondence:
Riana Kipiani Abdul Halim, Department of ORL-HNS, KPJ Healthcare University College, KPJ Selangor Specialist Hospital, Jalan Singa 20/1, Seksyen 20, 40300 Shah Alam, Selangor, Malaysia, Tel: +60355431111; E-mail: r_kipiani@yahoo.com

Received Date: *11 Nov 2020*
Accepted Date*: 10 Dec 2020*
Published Date*: 16 Dec 2020*

Citation:
Riana KAH, Hafeza A, MY Soo, MHA Ghafar, Iskandar H. Extensive Subgaleal with Subperiosteal Abscess and Deep Neck Abscess Secondary to Ear Foreign Body - Uncommon Presentation. Ann Clin Case Rep. 2020; 5: 1897.

ISSN: 2474-1655

Introduction

In the era of advanced medicine, the progress of otomastoiditis to scalp and neck abscesses could be prevented. A poor historian patient, the poorly controlled diabetes mellitus, untreated foreign body, destructive bacterial infections were factors contributed for rapid progression of the diseases in this patient. There is no common accepted surgical management for otogenic scalp and deep neck abscesses till present [1]. Ventilation tube tympanotomy insertion, Intravenous (IV) antibiotics, incision and drainage or needle aspiration have been reported as treatments for otomastoiditis with subperiosteal abscess. These treatments have avoided the morbidity and necessity of mastoid surgery. Indication of mastoidectomy is reserved in cases of severe complications or refractory disease despite antibiotics, ventilation tube tympanotomy and drainage [1-7]. We reported a case of adult patient with uncommon presentations following ear foreign body and discussed the management with its literature review.

Case Presentation

This is a case report of a 36-year-old lady with underlying chronic schizophrenia, which had been diagnosed since 2005. She was compliant to her medications and follow-up. She presented to emergency department in March 2020 with septic shock secondary to scalp and deep neck abscess and newly diagnosed Diabetes Mellitus (DM). She had fever, extensive scalp swelling and poor oral intake for four days prior to her visit. Her scalp swelling extended to her eyes and face. She did not complaint of any ear symptoms. Clinically, she was febrile and had fluctuant swelling on her left scalp extending from left temporoparietal region to her forehead, eyes and her left face. She also had bilateral preseptal cellulitis.

Computed Tomography (CT) scans of the brain, orbit and temporal bone showed large rim enhancing subperiosteal collection on left temporoparietal region extending to the left and right subgaleal frontal region (Figure 1A). There was left lateral skull base osteomyelitis with eroded left mastoid cortex that communicating with the subperiosteal and subgaleal abscesses (Figure 1B).

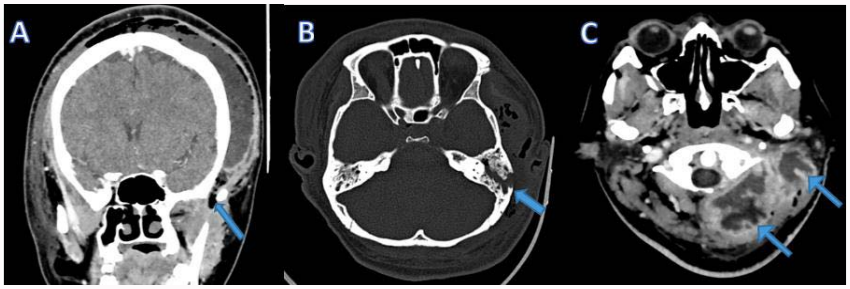

Figure 1: A. CT brain and temporal in coronal cut. Rim enhancing subgaleal collection with air locules predominantly on the left temporoparietal region which extends into the left infratemporal fossa (Arrow). **B.** High resolution CT temporal bone in axial cut. There is mastoid cortex erosion, communicating between the left mastoid air cells and the scalp (Arrow). **C.** CT-neck in axial cut. Arrows showed multiloculated rim enhancing collections at left posterior neck and paraspinal regions. No intraspinal extension.

Figure 2: Foreign body (multiple pieces of cotton) in the left external auditory canal.

Figure 3: The skin and soft tissue surrounds the surgical wound were contracted. However, the wound managed to be closed primarily.

She was resuscitated for septic shock secondary to extensive otogenic scalp abscess in the casualty department. After inotrope infusion, fluids resuscitation, insulin and intravenous third generation cephalosporin she was stabled. The White Blood Cells (WBC) was 18.06 × 10^9/L predominantly neutrophils and C-Reactive Protein (CRP) was 242.6 mg/L. Random blood sugar was markedly high 22.9 mmol/L and blood ketone was within acceptable range. Other bloods parameter was normal.

She underwent scalp abscesses drainage *via* retrosigmoid incision and about forty cc of frank pus drained out. Ear examination under microscopic revealed cerumen in the meatus occluding mucopurulent discharge and debris in the External Auditory Canal (EAC) with intact tympanic membrane. The posterior canal wall was eroded and multiple small pieces of cotton found embedded within debris and granulation tissue in the cavity (Figure 2). Thorough ear cleaning was performed and all foreign body were removed under general anesthesia together with drainage of the abscesses.

She was improved clinically and became afebrile. *Bactroides fragillis* was isolated from her blood culture and *Enterococcus avium* was isolated from the scalp pus drainage. However, on day 8 post drainage, she developed picket fence spiking temperature despite improvement on the scalp abscess wound. Repeated septic workup, showed similar organisms were cultured from the blood and the surgical wound respectively. Acid Fast Bacilli (AFB) smear test of the pus reported negative. Antibiotics IV Ampicillin, IV Ceftazidime and IV Metronidazole were tailored accordingly based on culture and sensitivity results. Repeated CT showed abscess collection had extended to the left deep neck spaces (Figure 1C).

Subsequently, left neck abscess drainage was performed which drained about 15cc of pus and in the same setting we performed Canal Wall down (CWD) mastoidectomy to eradicate the disease. The CWD mastoidectomy was opted in her case in view of erosion of the posterior EAC wall and present of cholesteatoma sac. The mastoid cortex had a defect and the mastoid cavity was filled up with granulation tissue extending into the middle ear. The ossicles were eroded. The skin and soft tissue surrounds the surgical wound were contracted. However, the wound managed to be closed primarily (Figure 3).

Her spiking fever had settled after the surgeries. In view of concurrent skull base osteomyelitis, the IV antibiotics were administered for six weeks. Patient was discharged after 2 months of hospital stay. After 4 months, patient was afebrile. However, the common cavity was still not well epithelized.

Discussion

Foreign body in the ear in an adult is uncommon. However, it should be considered in an adult patient with psychiatric disorder presenting with otogenic scalp abscess. Subperiosteal abscess as sequela from mastoiditis due to otitis externa following EAC foreign body is rare. The subperiosteal abscess, can rapidly progress to the subgaleal and the deep neck spaces, in cases with undiagnosed and uncontrolled DM. This was a serious condition because it can lead to intracranial complications, septic shock and skull base osteomyelitis.

In the past centuries, incidence of acute mastoiditis following otitis media have been decreasing drastically. In early 20th century to 1955, the incidence had dropped from 50% to 6% cases, and further dropped to 0.24% in 1990's [3,4]. Intracranial and extracranial

complications of otitis media have markedly decreased in the era of modern antibiotics. Complications such as facial nerve palsy, coalescent mastoiditis and subperiosteal abscess was reported only about 0.45% [8]. Deep neck abscess as a sequela of mastoiditis was extremely rare [9,10]. Subperiosteal abscess is the most common complication of acute mastoiditis in pediatric, however it is rare in adult [1,3-7,9]. It can spread by continuous passageway *via* the middle ear to the antrum then to the mastoid cavity or direct erosion of the posterior wall of the EAC as in this report. This destructive infection may also spread *via* tympanomastoid suture and vascular channels in the cribriform area which can lead to lateral skull base osteomyelitis [5].

Necrosis of the mastoid due to infection or inflammation may provide pus tracking medially to the neck spaces *via* the digastric groove. Bezold was the first to describe abscess in the neck arising from mastoiditis in 1908. Bezold's abscess can spread to the posterior cervical region, the perivertebral spaces and the deep neck spaces. The abscess may extend into the mediastinum and the base of skull *via* the danger spaces of the neck. These abscesses are more common in adult with well pneumatized mastoid because of the mastoid cortex bone are relatively thinner as compared to those with sclerosed mastoid [8,10].

Most common bacterial organisms isolated in mastoiditis were *Streptococcus pneumoniae*, *Streptococcus pyogenes*, *Staphylococcus aureus*, *Haemophilus influenza* and Bacteroides species. *Pseudomonas aeruginosa* commonly colonizes in the external ear canal [4,8].

Studies showed that conservative management such as IV antibiotic, myringotomy with or without ventilation tube insertion and pus needle aspiration or limited incision and drainage of the abscess were effective in most of patients [1,2,6].

Mastoidectomy was said to be reserved for refractory cases and patients with associated cholesteatoma or intracranial complications [1,2]. Mastoidectomy usually performed if patients showed no improvement after 48 h and up to day 5 of conservative treatment [2,5,7]. Conservative management as a first line of treatment can reduce mastoidectomy related complications [2,7]. Studies found out that the length of hospital stay reduced significantly in preserving mastoidectomy [1,2]. Chesney et al. [7] in 2013 had developed an algorithm where simple mastoidectomy is reserved in cases with intracranial and uncomplicated or subperiosteal abscess that had poor response to the initial treatment of IV antibiotics, myringotomy and drainage.

In our case, patient condition failed to improve despite regular ear toileting, IV antibiotics and drainage of the abscesses. A mastoidectomy was a necessity to clear out the source of infection. A multidisciplinary teamwork of Otorhinolaryngology (ORL), neurosurgical, internal medicine, infectious disease, psychiatric and ophthalmology teams involved in managing her.

Conclusion

We concluded that although foreign body in the ear is uncommon in an adult, it should be considered in those with psychiatric disorder presenting with otogenic scalp abscesses. Stabilization of acute condition along with IV antibiotics, regular ear cleaning, ventilation and pus drainage are the first line of management in patients with subgaleal, subperiosteal and deep neck abscess developing from mastoiditis. Mastoidectomy should be reserved for second line therapy in refractory cases and those associate with cholesteatoma or intracranial complications.

Acknowledgment

We would like to acknowledge Dr. Gurmit Singh Attar Singh (Neurosurgeon) and his team, our Otorhinolaryngology team and to other team for managing this patient together. Also to Dr. Nur Aimi Ngah (Master student in Radiology from the National University of Malaysia and Hospital Kuala Lumpur, Malaysia) and Radiology team for the images and reports.

Author Contributions

Conceptualization: Iskandar H. Writing - original draft: Riana KAH. Writing - review: MY Soo, MHA Ghafar. Editing: Hafeza A.

References

1. Psarommatis I, Giannakopoulos P, Theodorou E, Voudouris C, Carabinos C, Tsakanikos M. Mastoid subperiosteal abscess in children: Drainage or mastoidectomy? J Laryngol Otol. 2012;126(12):1204-8.
2. Irfan M, Fairuz MI, Dinsuhaimi S. Mastoid subperiosteal abscess with osteolytic intracranial extension: A rare complication of mastoiditis in a young patient. Pak J Med Sci. 2011;27(5):1184-6.
3. Dudkiewicz M, Livni G, Kornreich L, Nageris B, Ulanovski D, Raveh E. Acute mastoiditis and osteomyelitis of the temporal bone. Int J Pediatr Otorhinolaryngol. 2005;69(10):1399-405.
4. Abdel Raouf M, Ashour B, Abdel Gawad A. Updated management strategies for mastoiditis and mastoid abscess. Egyptian J Ear Nose Throat Allied Sci. 2012;13(1):43-8.
5. Migirov L, Yakirevitch A, Kronenberg J. Mastoid subperiosteal abscess: A review of 51 cases. Int J Pediatr Otorhinolaryngol. 2005;69(11):1529-33.
6. Kim SR, Choo OS, Park HY. Two cases of acute mastoiditis with subperiosteal abscess. Korean J Audiol. 2013;17(2):97-100.
7. Chesney J, Black A, Choo D. What is the best practice for acute mastoiditis in children? Laryngoscope. 2014;124(5):1057-9.
8. Chen YL, Ng SH, Wong HF, Wong MC, Wai YY, Wan YL. Otogenic deep neck abscess: A rare complication of cholesteatoma with acute mastoiditis. Chin J Radiol. 2002;27:251-6.
9. Luntz M, Brodsky A, Nusem S, Kronenberg J, Keren G, Migirov L, et al. Acute mastoiditis- the antibiotic era: A multicenter study. Int J Pediatr Otorhinolaryngol. 2001;57(1):1-9.
10. Khurram M, Lisa Dever L, Rajendra K. Bezold's abscess: A rare complication of suppurative mastoiditis. ID Cases. 2019;17:e00538.