Annals of Clinical Case Reports

Case Report
Published: 15 Jun, 2022

Extensive Right Coronary Artery Thrombosis in a Patient with Coronavirus Disease 2019

Clarissa Campo Dall'Orto[1], Rubens Pierry Ferreira Lopes[1], Mariana Torres Cancela[2], Círia de Sales Padilha[2], Gilvan Vilella Pinto Filho[1] and Marcos Raphael da Silva[1]*

[1]Therapy Center, Brazilian Society of Health Support Hospital, Brazil

[2]Medical Assistance Extreme South Hospital, Brazil

Abstract

A 62-year-old woman with COVID-19 had received three vaccine doses for SARS-CoV-2. Ten days after, the patient presented with inferior ST-segment elevations and was referred for an emergency angiography. Images of the Right Coronary Artery (RCA) and its Right Posterior Descending (RPD) and Right Posterior Ventricular (RPV) branches indicated intraluminal filling defects, suggesting a thrombus. The Intravascular Ultrasound (IVUS) suggested a subacute, homogeneous, echolucent thrombus in a large extension of the RCA, RPD, and RPV and an acute thrombus with a bright aspect, clear outline, and no signal attenuation in the RVP and mild to moderate atherosclerosis in the middle third of the RCA. We opted for dual antiplatelet therapy and complete anticoagulation therapy. After 7 days, a repeat coronary angiography revealed complete disappearance of the thrombi in the RCA and its branches. Optical Coherence Tomography (OCT) was performed for confirmation, showing the disappearance of the thrombi, except for a small residual thrombus in the RVP branch. It also identified mild to moderate atherosclerosis plaque in the middle third of the RCA. The invasive physiology of RCA was measured using the resting full-cycle ratio, indicating the absence of coronary physiology impairment. The patient recovered without further events and was discharged on the eleventh day of hospitalization.

OPEN ACCESS

Correspondence:
Clarissa Campo Dall'Orto, Department of Hemodynamic and Interventional Cardiology of Advanced Hemodynamic Therapy Center, Av. Pres. Getúlio Vargas - Recanto do Lago, 2752, Teixeira de Freitas, Bahia, 45987-088, Brazil, Tel: +55 (73) 99977-1522; Fax: + 55 (73) 3291-5419;
E-mail: clarissadallorto@alumni.usp.br

Received Date: *12 May 2022*
Accepted Date*: 07 Jun 2022*
Published Date*: 15 Jun 2022*

Citation:
Dall'Orto CC, Lopes RPF, Cancela MT, de Sales Padilha C, Filho GVP, da Silva MR. Extensive Right Coronary Artery Thrombosis in a Patient with Coronavirus Disease 2019. Ann Clin Case Rep. 2022; 7: 2228.
ISSN: 2474-1655

Abbreviations

ACS: Acute Coronary Syndrome; AMI: Acute Myocardial Infarction; COVID-19: Coronavirus Disease 2019; IVUS: Intravascular Ultrasound; OCT: Optical Coherence Tomography; RCA: Right Coronary Artery; RPD: Right Posterior Descending; RPV: Right Posterior Ventricular

Introduction

Cardiovascular complications that occur during the course of COVID-19 are causes of morbidity and mortality, occurring in approximately 30% of hospitalized patients [1-3]. A possible explanation for the damage caused by SARS-CoV-2 to the myocardium includes hypoxia after respiratory failure, excessive inflammation, excess cytokines, angiotensin-converting enzyme 2 receptor expression downregulation, platelet activation, coagulation cascade, endothelial cell injury, the rupture of previously existing plaques (type 1 Acute Myocardial Infarction [AMI]), and direct myocyte infiltration by the virus [4-6].

Case Presentation

A 62-year-old woman presented with Coronavirus Disease 2019 (COVID-19). The patient's medical history included: Dyslipidemia and incipient atherosclerosis in the carotid and aortic territories, continuous use of nortriptyline for migraines, and 9 years of tiboline as menopausal hormone therapy. The patient initially presented with flu-like symptoms, and was diagnosed with COVID-19 following a positive reading on a Polymerase Chain Reaction (PCR) test. The patient had received three vaccine doses for SARS-CoV-2. The first two doses were chimpanzee adenovirus vector vaccines (ChAdOx1 nCoV-19 AZD1222; Oxford/AstraZeneca/Fiocruz, Rio de Janeiro, Brazil), and the third dose was BNT162b2 mRNA COVID-19 vaccine (BioNTech/Pfizer, New York City, NY, USA). Ten days after [testing positive/the symptoms began], the patient presented with chest pain, dyspnea, nausea, and vomiting. In addition, electrocardiography showed sinus rhythm, inferior ST-segment elevations, and reciprocal changes in the anterolateral leads (Figure 1). The patient was referred for an emergency angiography. Coronary angiography revealed that the anterior descending coronary artery and its diagonal branches, and the circumflex artery and its marginal

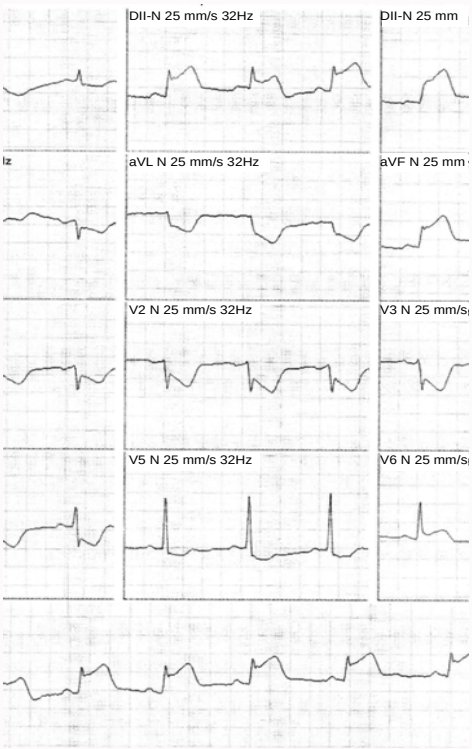

Figure 1: Electrocardiogram on admission**.** The results showed sinus rhythm with ST-segment elevation in the inferior wall and reciprocal changes in the anterolateral leads.

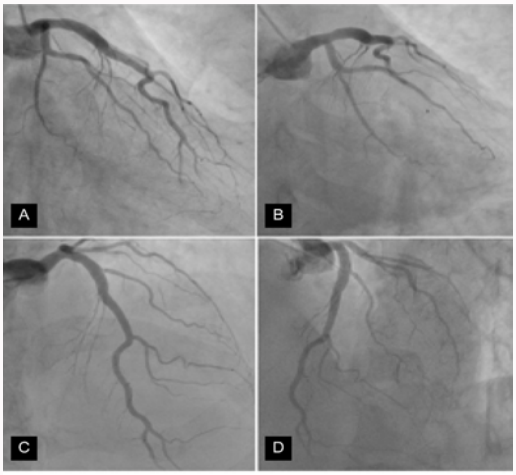

Figure 2: Emergency coronary angiogram: Left coronary artery**.** Angiography revealed no significant stenoses (A–D).

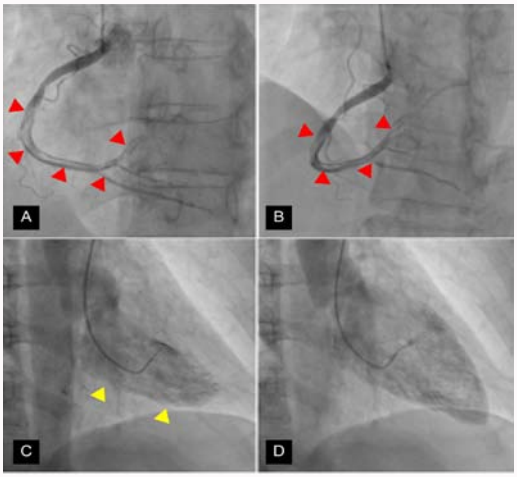

Figure 3: Emergency coronary angiogram: right coronary artery and left ventriculography. The images show intraluminal filling defects (red arrows) starting in the middle third of the Right Coronary Artery (RCA) and extending to the distal third, affecting the posterior descending and posterolateral RCA branches (**a, b**). Left ventriculography demonstrates inferior akinesia (yellow arrows) (**c, d**).

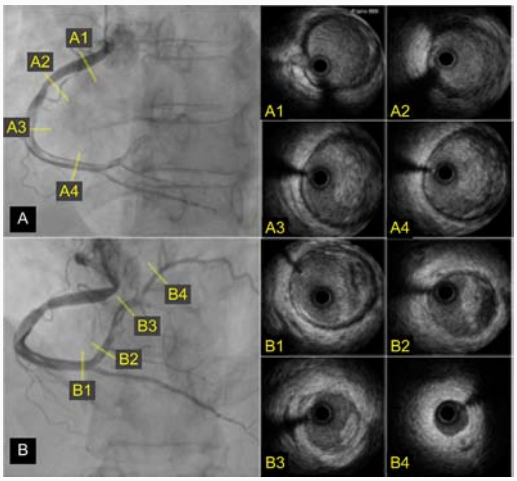

Figure 4: Intravascular ultrasound images from two angles (a, b). (**a1**) An incipient plaque**.** (**a2**) A concentric plaque-causing moderate luminal stenosis. (**a3**, **a4, b1**, **b2**) A subacute-appearing thrombus with a layered light to dark-gray appearance with white patches and less clear delineations. Moderate-to-severe signal attenuation may also be observed, probably due to the deviation or absorption of ultrasound waves by the subacute thrombus. (**b3**) An acute thrombus (asterisk) with a bright appearance, clear outline, and no signal attenuation. (**b4**) Discreet intimal thickening.

branches were free of obstructive atherosclerotic lesions (Figure 2). However, images of the Right Coronary Artery (RCA) and its Right Posterior Descending (RPD) and Right Posterior Ventricular (RPV) branches indicated intraluminal filling defects, suggesting a thrombus (Figure 3). Therefore, we evaluated the RCA by intracoronary ultrasound. The Intravascular Ultrasound (IVUS) pullbacks were performed using a 40 MHz IVUS OPTICROSS catheter (Boston Scientific, Natick, MA, USA) at 0.5 mm/s. The images suggested a subacute, homogeneous, echolucent thrombus in a large extension of the RCA, RPD, and RPV and an acute thrombus with a bright aspect, clear outline, and no signal attenuation in the RVP (Figure 4). We also identified mild to moderate atherosclerosis in the middle third of the RCA (Figure 3). At the angiogram, the patient was pain-free and had Thrombolysis in Myocardial Infarction (TIMI) 3 flow. Therefore, we opted for dual antiplatelet therapy with 180 mg of ticagrelor and aspirin and complete anticoagulation therapy with enoxaparin. The patient developed Killip grade I heart failure with elevated blood cardiac biomarkers (creatine kinase: 6105 IU/L; creatine kinase myocardial band fraction: 300 IU/L; and cardiac troponin I: 25 000 pg/mL). In addition, transthoracic Doppler echocardiography revealed a kinesis in the inferior mid-basal and apical infero-basal portions of the left ventricle. After 7 days, we repeated the coronary angiography, finding that the thrombi in the RCA and its branches completely disappeared (Figure 5). Therefore, we performed Optical Coherence Tomography (OCT) for confirmation. Intravascular OCT was performed using the ILUMIENTM OPISTM, OPTIS Integrated, and

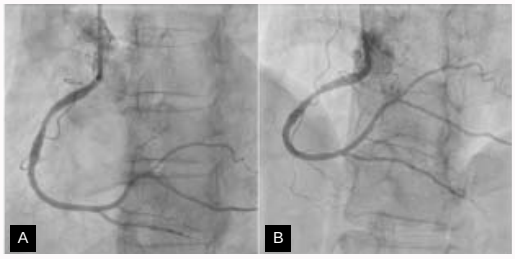

Figure 5: Reexamination of the Right Coronary Artery (RCA) after 7 days**.** The images show nearly complete resolution of the RCA thrombus.

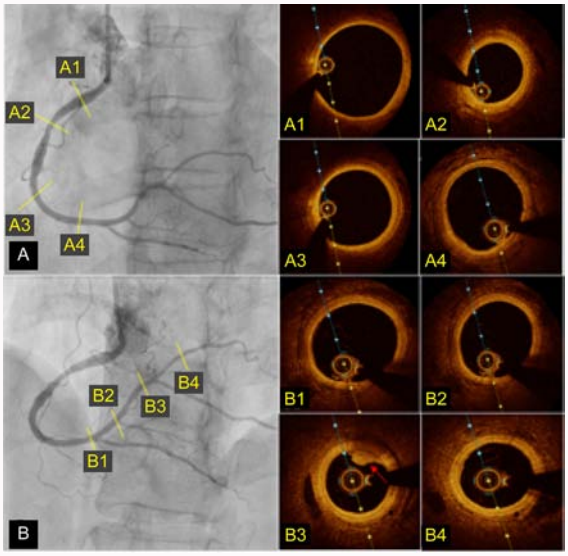

Figure 6: Optical coherence tomography images from two angles **(a, b).** (**a1**) A normal vessel with a three-layered structure. (**a2**) A fibrotic plaque. (**a3, a4**) Normal vessels with a three-layer structure**.** (**b1, b2**, **b4**) Normal vessels with a three-layer structure. (**b3**) Mild signal attenuation and easily delineated borders suggest white thrombus remnants (red arrow).

OPTIS Mobile systems (Abbott Vascular, Santa Clara, CA, USA) with a rapid exchange catheter (Dragonfly™ DUO, Dragonfly™ OPISTM, and Dragonfly OpStar™ Imaging Catheter; Abbott Vascular, Santa Clara, CA, USA) with a 75 mm/2.1 s (36 mm/s) pullback and 180 frames/s. The OCT exam confirmed that the thrombi disappeared, except for a small residual thrombus in the RVP branch (Figure 6). It also identified plaque in the middle third of the RCA. Severity of coronary stenosis was measured using the resting full-cycle ratio, which is a non-hyperemic index based on the unbiased detection of the lowest existing relationship between distal coronary pressure and aortic pressure (Pd/Pa), independent of the electrocardiogram, landmark identifications, and time within the heart cycle. We evaluated this plaque as 40% in mild RCA, causing 40% arterial lumen obstruction. We used PressureWire X (Abbott Vascular, Santa Clara, CA, USA), which reported a value of 0.99 (Figure 7), indicating the absence of coronary physiology impairment. The patient recovered without further events and was discharged on the eleventh day of hospitalization with ticagrelor, aspirin, statins, beta-blockers, and angiotensin-converting enzyme inhibitors. The authors obtained informed consent from the patient to publish this case report.

Discussion

Extra-respiratory involvement during SARS-CoV-2 infection has become more evident over time. AMI with ST-segment elevation with

Figure 7: Direct coronary artery invasive physiology assessment by resting full-cycle ratio. The plaque was evaluated as 40% in mild right coronary artery with a value of 0.99, indicating the absence of coronary physiology impairment.

a pattern on angiography with extensive thrombosis that can affect one or more coronary arteries simultaneously and different vascular territories, not caused by rupture of atherosclerotic plaques, represents a new challenge in treating and managing this pathology. This may be associated with the increased incidence of stent thrombosis, and severe inflammation with consequent hypercoagulation is another primary pathology associated with this phenomenon [7]. While differentiating between type I and type II AMI and myocarditis in patients with COVID-19 presenting with Acute Coronary Syndrome (ACS) is important, there is no consensus on the ideal management approach for ACS. Percutaneous coronary intervention, aspiration, and antiplatelet thrombectomy are possible options, with the latter being the most generally agreed upon for treating these patients [8].

Conclusion

This case is the first report of extensive RCA thrombosis in a patient with COVID-19 evaluated by intracoronary imaging and intracoronary invasive physiology.

Funding

This work was supported by the Department of Hemodynamic and Interventional Cardiology of Advanced Hemodynamic Therapy Center, Brazilian Society of Health Support Hospital.

References

1. Zhou F, Yu T, Du R, Fan G, Liu Y, Liu Z, et al. Clinical course and risk factors for mortality of adult inpatients with COVID-19 in Wuhan, China: A retrospective cohort study. Lancet. 2020;395:1054-62.
2. Arentz M, Yim E, Klaff L, Lokhandwala S, Riedo FX, Chong M, et al. Characteristics and outcomes of 21 critically ill patients with COVID-19 in Washington State. JAMA. 2020;323:1612-4.
3. Guo T, Fan Y, Chen M, Wu X, Zhang L, He T, et al. Cardiovascular implications of fatal outcomes of patients with Coronavirus Disease 2019 (COVID-19). JAMA Cardiol. 2020;5:811-8.
4. Stefanini GG, Montorfano M, Trabattoni D, Andreini D, Ferrante G, Ancona M, et al. ST-elevation myocardial infarction in patients with COVID-19: Clinical and angiographic outcomes. Circulation. 2020;141:2113-6.
5. Bois MC, Boire NA, Layman AJ, Aubry MC, Alexander MP, Roden AC, et al. COVID-19-associated nonocclusive fibrin microthrombi in the heart. Circulation. 2021;143:230-43.
6. Masi P, Hékimian G, Lejeune M, Chommeloux J, Desnos C, De Chambrun MP, et al. Systemic inflammatory response syndrome is a major contributor

to COVID-19-associated coagulopathy: Insights from a prospective, single-center cohort study. Circulation. 2020;142:611-4.

7. Kermani-Alghoraishi M. A review of coronary artery thrombosis: A new challenging finding in COVID-19 patients and ST-elevation myocardial infarction. Curr Probl Cardiol. 2021;46:100744.

8. Varga Z, Flammer AJ, Steiger P, Haberecker M, Andermatt R, Zinkernagel AS, et al. Endothelial cell infection and endotheliitis in COVID-19. Lancet. 2020;395:1417-8.