



Endoscopic Resection of a Large Brunner's Gland Hamartoma: A Case Report and Literature Review

Yu Jin¹, Gangping Li¹, Nan Shen², Weibin Chen³, Xiaohua Hou^{1*} and Jun Liu^{1*}

¹Division of Gastroenterology, Huazhong University of Science and Technology, China

²Department of Radiology, Huazhong University of Science and Technology, China

³Department of Pathology, Huazhong University of Science and Technology, China

Abstract

Background: Brunner's gland Hamartoma is a rare and benign tumor of the duodenum. Endoscopic resection of large Brunner's gland Hamartoma has seldom been reported. We report a case of a Brunner's gland Hamartoma which was as large as 6 cm × 5 cm that was successfully managed by endoscopic excision.

Case presentation: A 49-year-old Chinese woman presented to a local hospital with a 5-month history of epigastric fullness and nausea. In local hospital, upper endoscopy presented a sessile lesion in the proximal duodenum, for which mucosal biopsies were non-diagnostic. She was managed conservatively; however, the patient did not improve over the next 2 months and complained of persistent epigastric fullness. Then she was referred to our hospital for further examination. In our hospital, the contrast-enhanced Computed Tomography (CT) showed a round mass about 5 cm in diameter. Endoscopic Ultrasonography (EUS) suggested this was a submucosal and cyst-solid lesion with a well-defined boundary, and there were no ulcers or erosions on the surface. Finally, the lesion was successfully managed by endoscopic technique (Endoscopic Submucosal Dissection, ESD). The size of the resected specimen was as large as 6 cm × 5 cm and pathologically diagnosed as Brunner's gland Hamartoma. These results show that large Brunner's gland Hamartoma can be treated successfully by careful use of endoscopic procedures.

Conclusion: We present this case and reviewed the reported cases of Brunner's gland hamartomas which were resected endoscopically, which might provide a reference for endoscopists and surgeons.

Keywords: Duodenum; Brunner's gland hamartoma; Endoscopic Resection

Introduction

Brunner's gland Hamartoma was first described by Cruveilhier in 1835. It is generally described as a rare, benign, proliferative lesion arising from Brunner's glands, which are located in the submucosa of duodenum [1,2]. Histologically, the lesions are characterized as an admixture of normal tissues such as Brunner's glands, ducts, smooth muscle, adipose and lymphoid tissues [3,4].

The symptomatic Brunner's gland Hamartoma accompanied by hemorrhage, obstruction, or intussusceptions usually requires surgical treatment, while it remains controversial as to whether an asymptomatic tumor, found incidentally, requires surgical removal [5]. When the tumor is small or pedunculated, endoscopic excision including polypectomy can be performed for treatment, while surgical removal should be considered for giant lesions. However, there are no explicit criteria to discern between endoscopic or surgical resection.

Herein, we report a case of a large Brunner's gland Hamartoma of the duodenum that was successfully managed by endoscopic excision, and give a review through the existing literatures of Brunner's gland hamartomas which were subsequently resected endoscopically.

Case Presentation

A 49-year-old Chinese woman was referred to the hospital with epigastric fullness. Physical examination and laboratory results revealed no abnormalities. Upper endoscopy presented a sessile lesion in the first part of duodenum, for which mucosal biopsies were non-diagnostic (Figure 1). This patient was admitted to our hospital for further investigation and treatment. Endoscopic ultrasonography showed a cyst-solid lesion (Figure 2). Abdominal CT revealed a round mass with

OPEN ACCESS

*Correspondence:

Xiaohua Hou, Division of Gastroenterology, Union Hospital, Tongji Medical College, Huazhong University of Science and Technology, Wuhan, China,

E-mail: houhx@medmail.com.cn

Jun Liu, Division of Gastroenterology, Union Hospital, Tongji Medical College, Huazhong University of Science and Technology, Wuhan, China,

E-mail: liujun_99@126.com

Received Date: 04 Dec 2019

Accepted Date: 08 Jan 2020

Published Date: 13 Jan 2020

Citation:

Jin Y, Li G, Shen N, Chen W, Hou X, Liu J. Endoscopic Resection of a Large Brunner's Gland Hamartoma: A Case Report and Literature Review. *Ann Clin Case Rep.* 2020; 5: 1785.

ISSN: 2474-1655

Copyright © 2020 Xiaohua Hou and Jun Liu. This is an open access article distributed under the Creative Commons Attribution License, which permits unrestricted use, distribution, and reproduction in any medium, provided the original work is properly cited.

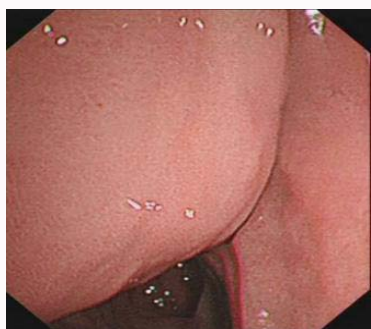

Figure 1: Upper endoscopy presented a subepithelial sessile duodenal lesion.

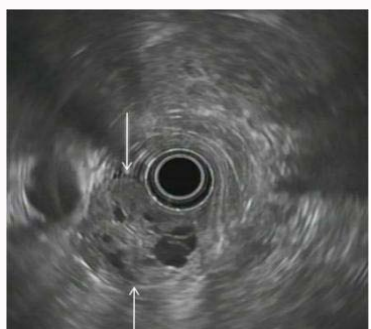

Figure 2: Endoscopic ultrasonography showed a cyst-solid lesion (arrow).

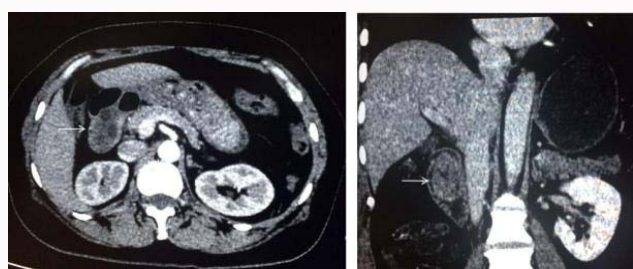


Figure 3: Abdominal CT revealed a round mass with internal multifocal low densities in the proximal duodenum (arrow).

internal multifocal low densities in the proximal duodenum (Figure 3).

Based on the macroscopic and ultrasonography characteristics, Brunner's gland Hamartoma was suspected. Furthermore, in consideration of that this patient had no serious complications; we intended to resect it endoscopically. The patient agreed to undergo endoscopic resection. Anatomic characteristics of the duodenum make endoscopic resection of duodenal lesions challenging. However, advanced endoscopic techniques enable the endoscopic resection of large duodenal lesions. This lesion was successfully resected without any complications, and the specimen was obtained for pathological analysis. Gross examination of the resected specimen revealed a large sessile duodenal lesion measuring 6 cm × 5 cm, with intact mucosa without erosions or ulcers (Figure 4). Figure 5 shows a histologic section of the mass stained with Hematoxylin and eosin. Microscopic examination showed that the mass was composed of lobules of relatively bland-appearing Brunner's glands, which were surrounded by bundles of fibro muscular and connective tissue without atypical glands, confirming the diagnosis of Brunner's gland Hamartoma. The

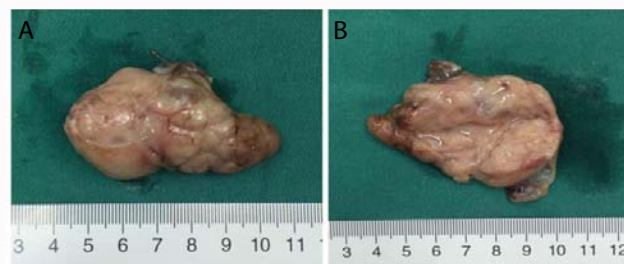

Figure 4: Gross examination of the resected specimen revealed a large duodenal lesion measuring 6 cm × 5 cm, with a smooth surface without erosions or ulcers.

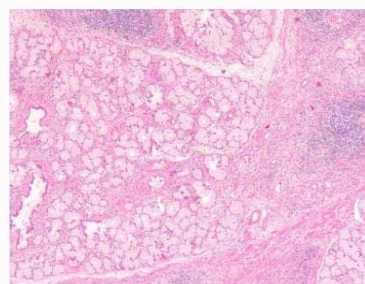


Figure 5: Microscopic examination showed that the mass was composed of lobules of relatively bland-appearing Brunner's glands, which were surrounded by bundles of fibro muscular and connective tissue without atypical gland.

postoperative course was uneventful, and the patient was discharged on postoperative day 5.

Discussion

Brunner's gland Hamartoma, also known as Brunner's gland adenoma or brunneroma, is a rare benign tumor arising from the Brunner's glands of the duodenum [6]. The exact pathogenesis of Brunner's gland Hamartoma is unknown. One hypothesis suggests that they may be related to irritation of the local lining, chronic pancreatitis, *Helicobacter pylori* infection, or parasympathetic activity [7].

Most patients are asymptomatic, but some can present with non-specific symptoms such as abdominal bloating, mild abdominal pain, early satiety or nausea [8]. Brunner's gland hamartomas can be found incidentally during gastroscopy or on imaging. Although symptomatic lesions are rare, patients may present with hemorrhage or obstruction. Gastrointestinal bleeding may occur because of ulcer or tumor erosion, causing in melena, fatigue, iron deficiency anemia, and in rare cases, hematemesis [6,9,10].

Gastroscopy is a diagnostic method of Brunner's gland hamartomas. However, endoscopic biopsies are usually negative owing to the submucosal location of the mass [11]. The radiological features have been described elsewhere. There are, however, no exact characteristic radiological features for this lesion. CT scan can help to exclude associated pathology in adjacent structures [12]. Endoscopic ultrasonography is used to better define origin, extent, and vascularity of polyps and suspected submucosal lesions. It is considered to be the imaging modality of choice [11,13]. It assists to differentiate between intraluminal and extraluminal mass and to give a preliminary diagnosis on the characteristic appearance of the lesion and the layer from which the lesion arises. Brunner's gland hamartoma appear

Table 1: Reported cases of Brunner's gland hamartomas which were resected endoscopically.

Reference	Year	Size (cm)	Morphology
Hizawa et al. [20]	2002	0.7	broad-based
Hizawa et al. [20]	2002	1.5	sessile
Hizawa et al. [20]	2002	1.5	sessile, surface dimples
Lenz et al. [26]	2013	1.5 × 1.4 × 0.8	pedunculated
Kurella et al. [27]	2008	1.7	sessile
Hizawa et al. [20]	2002	1.8	broad-based
Hizawa et al. [20]	2002	2	sessile, surface dimples
Hizawa et al. [20]	2002	2	pedunculated, surface dimples
Matsui et al. [28]	1989	2.5 × 1.5	pedunculated
Mukherjee et al. [29]	1999	2.5 × 1.8 × 1.5	pedunculated, ulcerated stalk
Iwamuro et al. [18]	2016	2.6 × 1.9	pedunculated
Shemesh et al. [30]	2000	3.0 × 2.0	pedunculated, ulcerated
Rocco et al. [31]	2006	3.0 × 4.0	pedunculated
Jeong et al. [32]	2004	4.0 × 2.0	pedunculated
Walden [33]	1998	4.0 × 2.5 × 2.0	pedunculated, ulcerated
Kehl et al. [34]	1985	4.0 × 4.0	pedunculated
Hyatt et al. [35]	2006	5.0cm	pedunculated
Chen et al. [36]	2006	6.0 × 0.4 × 0.2	pedunculated
Coriat et al. [13]	2008	6.0 × 4.0	pedunculated
Stermer et al. [37]	2005	7 cm long	pedunculated, lobulated, ulcerated
Lee et al. [38]	2016	9.3 × 2.0	pedunculated, eroded
Tai et al. [39]	2001	10.5 cm in length	pedunculated

as a heterogeneous lesion with solid and cystic components. And it usually demonstrates as a localized mass exclusively limited to the submucosal layer [14-17]. Therefore, endoscopic ultrasonography provides endoscopists an important tool to diagnose Brunner's gland hamartoma [11,18,19]. Hizawa et al. [20] reviewed endoscopic ultrasonography features of six cases of Brunner's gland hamartoma and they indicated that single or multiple cystic structures within the submucosa could be detected in four patients and solid echogenicity in the remaining two patients. There is no doubt that the definite diagnosis was established on the pathological examination of the resected specimen.

It is still controversial whether asymptomatic Brunner's gland hamartoma found incidentally needs surgical removal. Some people think that it needs no treatment, whereas others hold that it should undergo endoscopic excision in order to prevent complications [21-24]. Symptomatic Brunner's gland hamartoma usually needs surgical treatment. When the tumor is small or pedunculated, endoscopic polypectomy is the first choice. In our case, this sessile lesion was as large as 6 cm × 5 cm, and we successfully resected it under endoscopy and allowed the patient to avoid surgery, which providing a choice for clinicians. We also give a review through the reported cases of Brunner's gland hamartomas which were resected endoscopically. The results are summarized in Table 1. These results may be a reference for endoscopists when they encounter analogous lesions. Open surgical excision is reserved for cases where endoscopic excision has failed or when tumor is too large [21,25].

Conclusion

In conclusion, we treated a patient with a large Brunner's gland

hamartoma showing sessile morphology. When a solitary lesion with cystic structure is found at the duodenum, it is important for clinicians to consider Brunner's gland hamartoma in the differential diagnosis, despite the rarity of the disease. Endoscopic ultrasonography provides endoscopists an important tool to diagnose Brunner's gland hamartoma. In our case, endoscopic resection proceeded successfully despite the size of the lesion. This case shows that large Brunner's gland hamartoma can be treated successfully by careful use of endoscopic procedures. Furthermore, we also give a review through the reported cases of Brunner's gland hamartomas which were resected endoscopically, to provide a reference for clinicians.

Authors Contributions

YJ and GL contributed to the writing of the manuscript. JL performed the clinical work-up and therapy. XH revised the manuscript to get final approval of the current submission. JL and XH contributed equally to this manuscript. NS provided the radiological images for this manuscript. WC provided the pathological images. All authors read and approved the final manuscript.

Consent for Publication

Written informed consent was obtained from the patient for publication of this case report.

References

- Gupta A, Rajput D, Kumar U, Gupta S, Singh A, Sanyal S. Brunner's gland hamartoma presenting as gastric outlet obstruction: unusual presentation and review of literature. *Trop Doct.* 2019;49:475519870980.
- Yi L, Cheng Z, Qiu H, Yang J, Wang T, Liu K. A giant Brunner's gland hamartoma being treated as a pedunculated polyp: a case report. *BMC Gastroenterol.* 2019;19(1).
- Wang YP, YR Kuo, CL Lu. A rare cause of gastrointestinal bleeding. *Gastroenterology.* 2013;145(1):62-261.
- Namikawa T, Kobayashi M, Hanazaki K. An Unusual Giant Duodenal Mass Lesion. *Gastroenterology.* 2015;148(5):e5-e6.
- Hsieh WY, Chen PH, Hou MC. A Duodenal Tumor That Causes Partial Obstruction. *Gastroenterology.* 2016;150(1):e9-e10.
- Nakabori T, Shinzaki S, Yamada T, Nishida T, Iijima H, Tsujii M, et al. Atypical duodenal ulcer and invagination caused by a large pedunculated duodenal Brunner's gland hamartoma. *Gastrointest Endosc.* 2014;79(4):679-80.
- Sen R, Gupta V, Sharma N, Chawla N, Kumar S, Malik S. Brunner gland hamartoma masquerading as malignancy: A rare case report. *Middle East J Dig Dis.* 2014;6(4):237-40.
- Sudo G, Kobayashi T, Nakase H. Brunner's gland hamartoma arising from the pyloric ring. *Clin Gastroenterol Hepatol.* 2019;17(13):e155.
- Lu L, Ruotong Li, Zhang G, Zhao Z, Fu W, Li W. Brunner's gland adenoma of duodenum: report of two cases. *Int J Clin Exp Pathol.* 2015;8(6):7565-9.
- Yadav D, Hertan H, Pitchumoni CS. A giant Brunner's gland adenoma presenting as gastrointestinal hemorrhage. *J Clin Gastroenterol.* 2001;32(5):448-50.
- Nelsen EM, Abbott DE, Pfau PR, Benson ME. EUS core biopsy leading to duodenal brunneroma diagnosis. *Gastrointest Endosc.* 2017;86(6):1179-80.
- Takeuchi M, Cho H, Sugimoto M, Ohira T, Usuki N, Morimoto Y. CT and MRI findings for Brunner's gland hamartoma: report of three cases. *Jpn J Radiol.* 2015;33(6):375-9.
- Coriat R, Mozer-Bernardeau M, Terris B, Chryssostalis A, Prat F,

- Chaussade S. Endoscopic resection of a large Brunner's gland hamartoma. *Gastroenterol Clin Biol*. 2008;32(1 Pt 1):11-4.
14. Peloso A, Viganò J, Vanoli A, Dominioni T, Zonta S, Bugada D, et al. Saving from unnecessary pancreaticoduodenectomy. Brunner's gland hamartoma: Case report on a rare duodenal lesion and exhaustive literature review. *Ann Med Surg (Lond)*. 2017;17:43-9.
15. Tornambè A, Tornambè G. A case of peduncolated Brunner's gland hamartoma. *G Chir*. 2018;39(2):111-3.
16. Pasetti A, Capoferro E, Querzoli G, Montanari R, Bocus P. En Bloc Endoscopic Resection of Large Pedunculated Brunner's Gland Hamartoma: A Case Report. *Case Rep Gastroenterol*. 2018;12(2):344-51.
17. Barat M, Dohan A, Dautry R, Barral M, Boudiaf M, Hoeffel C, et al. Mass-forming lesions of the duodenum: A pictorial review. *Diagn Interv Imaging*. 2017;98(10):663-75.
18. Iwamuro M, Tanaka T, Ando S, Gotoda T, Kanzaki H, Kawano S, et al. Endoscopic Resection of a Pedunculated Brunner's Gland Hamartoma of the Duodenum. *Case Rep Gastrointest Med*. 2016;2016:6707235.
19. Stoos-Veic T, Tadic M, Aralica G. EUS-FNA of Brunner's gland hamartoma: A case report. *Cytopathology*. 2013;24(3):194-6.
20. Hizawa K, Iwai K, Esaki M, Suekane H, Inuzuka S, Matsumoto T, et al. Endosonographic Features of Brunner's Gland Hamartomas which were Subsequently Resected Endoscopically. *Endoscopy*. 2002;34(12):956-8.
21. de la Riva S, Carrascosa J, Muñoz-Navas M, Sùtil JC, Carretero C, Sola JJ, et al. [Giant Brunner's gland hamartoma: diagnosis and endoscopic treatment]. *Gastroenterol Hepatol*. 2011;34(5):333-6.
22. Toussaint C, Libbrecht L, Dano H, Piessevaux H. Endoscopic features, pathological correlates and possible origin of foveolar gastric metaplasia presenting as a duodenal polyp. *Acta Gastroenterol Belg*. 2019;82(2):257-60.
23. Rath MM, Mohapatra D, Mohanty SK, Shantisudha S. Brunner's gland hamartoma with dysplasia, presenting as multiple duodenal polyps: An unexplored entity with literature review. *Indian J Pathol Microbiol*. 2019;62(2):290-2.
24. Gaspar JP, Stelow EB, Wang AY. Approach to the endoscopic resection of duodenal lesions. *World J Gastroenterol*. 2016;22(2):600-17.
25. Delvecchio K, Seman S. Successful surgical excision of a massive symptomatic partially obstructing Brunner's gland hamartoma: a case report. *J Surg Case Rep*. 2016;2016(12).
26. Lenz L, Felipe-Silva A, Nakao F, Miyajima N, Della Libera E, Chaves DM, et al. Pyloric Brunner's gland hamartoma with atypical hyperplasia. *Autops case reports*. 2013;3(4):49-51.
27. Kurella RR, Ancha HR, Hussain S, Lightfoot SA, Harty R. Evolution of Brunner gland hamartoma associated with *Helicobacter pylori* infection. *South Med J*. 2008;101(6):648-50.
28. Matsui T, Iida M, Fujishima M, Sakamoto K, Watanabe H. Brunner's gland hamartoma associated with microcarcinoids. *Endoscopy*. 1989;21(1):37-8.
29. Mukherjee S, Mainzer TA, Murthy UK. Endoscopic injection and polypectomy for bleeding Brunner's gland hamartoma. *Gastrointest endosc*. 1999;50(4):597-8.
30. Shemesh E, Ben Horin S, Barshack I, Bar-Meir S. Brunner's gland hamartoma presenting as a large duodenal polyp. *Gastrointest endosc*. 2000;52(3):435-6.
31. Rocco A, Borriello P, Compare D, De Colibus P, Pica L, Iacono A, et al. Large Brunner's gland adenoma: Case report and literature review. *World J Gastroenterol*. 2006;12(12):1966-8.
32. Jeong YS, Chung JP, Lee DY, Ji SW, Lee SJ, Lee KS, et al. Pyloric Brunner's gland hamartoma. *Gastrointest endosc*. 2004;59(1):76.
33. Walden DT, Marcon NE. Endoscopic injection and polypectomy for bleeding Brunner's gland hamartoma: Case report and expanded literature review. *Gastrointest Endosc*. 1998;47(5):403-7.
34. Kehl O, Buhler H, Stamm B, Amman RW. Endoscopic removal of a large, obstructing and bleeding duodenal Brunner's gland adenoma. *Endoscopy*. 1985;17(6):231-2.
35. Hyatt P, Resnick M, Habr F, Baffy G. Brunner's gland hamartoma. Clinical gastroenterology and hepatology: the official clinical practice. *J Am Gastroenterol Association*. 2006;4(7):A26.
36. Chen YY, Su WW, Soon MS, Yen HH. Hemoclip-assisted polypectomy of large duodenal Brunner's gland hamartoma. *Dig dis sci*. 2006;51(9):1670-2.
37. Stermer E, Elias N, Keren D, Rainis T, Goldstein O, Lavy A. Acute pancreatitis and upper gastrointestinal bleeding as presenting symptoms of a duodenal Brunner's gland hamartoma. *Can J Gastroenterol*. 2006;20(8):541-2.
38. Lee JH, Jo KM, Kim TO, Park JH, Park SH, Jung JW, et al. Giant Brunner's Gland Hamartoma of the Duodenal Bulb Presenting with Upper Gastrointestinal Bleeding and Obstruction. *Clin Endosc*. 2016;49(6):570-4.
39. Tai M, Yoshikawa I, Kume K, Murata I, Otsuki M. A large Brunner's gland hamartoma resected by endoscopic polypectomy. *Gastrointest endosc*. 2001;53(2):207-8.