Annals of Clinical Case Reports

Review Article
Published: 12 Aug, 2016

Dens Invaginatus with Necrotic Pulp in a Right Maxillar Lateral Incisor with Preserved Vitality

Femiano F[1], Femiano R[1], Femiano L[1], Perillo L[1] and Guidetti E[2]*

[1]*Multidisciplinary Department of Medical-Surgical and Dental Specialties, Second University of Naples, Italy*

[2]*Freelance dentistry in Naples, Italy*

Abstract

Dens invaginatus is a dental anomaly of embryonic origin that presents itself in several morphologic types. Root canal treatment of teeth with dens invaginatus, for the complex root canal anatomy, can be problematic because infected pulpal tissues may remain in inaccessible areas of canal system. The singularity of case reported was the finding of a sinus tract at the buccal mucosa in correspondence of apex of a vital maxillar lateral incisor with a inner dens invaginatus with necrotic pulp.

We avoided to preserve the vital pulp of tooth and the treatment choice was the root canal therapy both of tract canal of inner dental malformation and of root canal of tooth with obturation of canals by means mineral trioxide aggregate and guttapercha respectively. After 10 days we got the clinical disappearance of oral sinus tract while the disappearance of radiolucent area, expression of radiographic healing, occurred after 6 months.

Keywords: Dens invaginatus; Dens in dente; Dental malformation; Endodontic treatment; Periapical lesion

Introduction

Dens Invaginatus (DI) or known as 'dens in dente' was described by Ploquet in 1794 in a whale's tooth, identified as such in a human tooth by the dentist Socrates in 1856, represents an unusual developmental anomaly involving the early invagination of enamel and dentine that may extend deep into the pulp cavity and to the roots, sometimes reaching the apex before calcification occurs [1-3].

The case describes in this study is a rare presentation of a DI with necrotic pulp held within the vital pulp of a maxillar lateral incisor.

Case Report

A 19 years old Italian female patient with a non-contributory medical history came to our observation for a visit programmed control. The intraoral examination revealed an fistula of the buccal mucosa in correspondence of apex of right maxillar lateral incisor [1,2] (Figure 1A). The response to electric pulp vitality test for the right upper canine, the lateral and the central incisor was positive. The 1.2 appeared morphologically normal except for a deep pit on lingual surface (Figure 1B). The intra oral periapical radiography highlighted the crown of 1.2 with the central dilated and amorphous area for inner presence of a wide radiopaque formation which occupying the coronal space and gets over the enamel cement junction and which encloses a space radiolucent which communicates with the periodontal space of middle third of root (Figure 1C). The fistulography, performed by means insertion of a guttapercha cone into oral fistula and gently pushed into sinus tract, revealed the impact of tip in closeness of half of radicular surface of lateral incisor neighbouring with a radiolucent area. The radiographic diagnosis was of DI of 1.2 (Figure 2A and B). The therapy was to try the endodontic treatment. The patient was informed about the diagnosis and the treatment plan and the agreement was signed by an informed consent form. In following administration of local anesthesia, under 20X magnification, the pulp chamber of 1.2 was opened and the invagination orifice of malformation was localized (Figure 3A). Subsequently, the design of cavity was finished to surround the profile of found malformation. The DI was revealed as malformation of rounded shape into the dental chamber and surrounded by vital and bloody pulp (Figure 3B). The hole central of DI was recognized and enlarged with the Gates Glidden burs in succession from N° 1 to 3 to facilitate the insertion of a K-file 0.8 pushed gently in tract canal of increasing diameter

OPEN ACCESS

Correspondence:
Felice Femiano, Conservative Dentistry, Multidisciplinary Department of Medical-Surgical and Dental Specialties, Second University of Naples, Via Francesco Girardi 2, S.Antimo (NA) 80029, Italy, Tel: 0039 081-8304248; Fax: 0039 081-5051524;
E-mail: femiano@libero.it

Received Date: *10 Jun 2016*
Accepted Date*: 09 Aug 2016*
Published Date*: 12 Aug 2016*

Citation:
Femiano F, Femiano R, Femiano L, Perillo L, Guidetti E. Dens Invaginatus with Necrotic Pulp in a Right Maxillar Lateral Incisor with Preserved Vitality. Ann Clin Case Rep. 2016; 1: 1079.

Figure 1: A: The clinical case with buccal fistula in correspondence of apex of right maxillar lateral incisor. B: Intra oral peri apical radiograph shows the presence of dens invaginatus within crown of lateral incisor extending in root canal and with radiolucency area in periodontal space of radicular surface. C: Accentuated lingual pit of right upper lateral incisor.

Figure 2: A: The gutta-percha cone inserted in oral fistula. B: Fistulography.

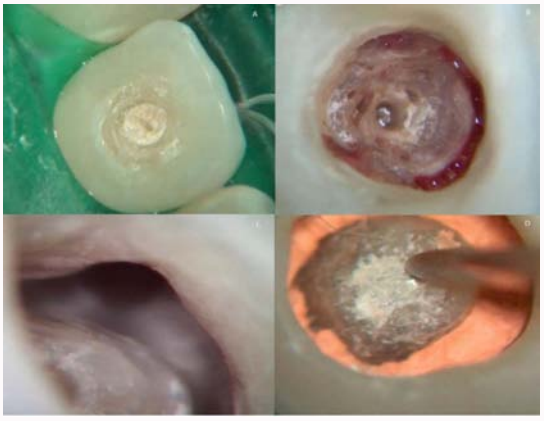

Figure 3: A: Identification of invagination orifice of dental anomaly. B: Dens invaginatus of rounded shape surrounded by vital pulp of toothmaxillar lateral incisor. C: Entrance of dental root canal. D: Seal ofperi-malformation space by means gutta-percha and of canal tract of dental malformation by means MTA.

until the communication with periodontal space. The pulpartissue of DI appeared necrotic and not bloody. It was necessary to remove the vital pulp, highlighted around the malformation with a pointed probe to locate the access for the principal root canal (Figure 3C). The working length was determined using a K-file 0.8 connected to an apex locator (Root ZX, Morita, Tokyo, Japan) followed by confirmation with a periapical radiography. To prevent the spread of infectious processes, the endodontic treatment of dental root canals was carried out before embarking the treatment of pulpar tract of the inner malformation and all this in a single session. The preparation of both canal systems includes both enlargement and shaping of the

Figure 4: A: Clinical disappearance of oral fistula after 10 days from completion of root canal therapy. B: Indirect restoration of access cavity.

Figure 5: A: Periapical radiography of lateral incisor at end of endodontic treatment. B: Periapical radiography at 6 months.

complex endodontic space by hand and mechanical instrumentation of ProTaper technique (Dentsply), disinfection by means alternate irrigating solutions with EDTA and sodium hypochlorite at 2% heated to 40°C. The filling of the canals was performed by means sealing with mineral trioxide aggregate (MTA) for DI canal while for three-dimensional obturation and seal of the root canal systems was utilized guttaperca by means the vertical compaction technique with System B Heat Source (SymbronEndo) for the down-packing and injection of thermoplastic guttaperca by Obtura III (SymbronEndo) up to sealing the surrounding malformation space for the back-filling (Figure 3D).

After 10 days from finishing of root canal therapy, we remarked the clinical disappearance the oral sinus tract (Figure 4A). The access cavity was then restored by a filling base with vetroionomeric cement (3M Espe) and covering with resin composite by indirect restorative technique (A2 Gandioso, Voco) (Figure 4B).

After 6 months the comparison of intra-oral periapical radiography the end of treatment, emphasized the disappearance of the radiolucent area (Figure 5 A and B). After one year, the patient required to improve her smile complaining a discolouring of lateral incisor and the correction of slope of central incisor. A cervical gingivoplasty (Figure 6A) with veener restoration in lithium silicate at 1.2 and a reductive odontoplasty of central incisor was carried out with great satisfaction of the patient (Figure 6B).

Figure 6: A: cervical gingivoplasty. B: veener restoration in lithium silicate at 1.2 and a reductive odontoplasty of central incisor.

Etiopathogenesis and classification

1. Several theories have been put forward to explain the etiopathogenesis of DI [1]. Kronfeld (1934) suggested that the invagination results from a focal failure of growth of the internal enamel epithelium while the surrounding normal epithelium continues to proliferate engulfing the static area [4].

2. Rushton [5], in opposition, proposed that the invagination is a result of rapid and aggressive proliferation, rather than retardation, of a part of the internal enamel epithelium invading the dental papilla.

3. Fischer [6] and Sprawson [7] considered the infection to be responsible for the malformation.

4. Growth pressure of the dental arch results in buckling of the enamel organ [8].

5. The "twin-theorie" (Bruszt 1950) suggested a fusion of two tooth-germs [9].

6. Oehlers and Dens invaginatus [10] considered that distortion of the enamel organ during tooth development and subsequent protrusion of a part of the enamel organ will lead to the formation of an enamel-lined channel ending at the cingulum or occasionally at the incisal tip.

Oehlers classified the DI basing on the radiographic interpretation of the degree of invagination into three types: Type I, Type II and Type III.

Type I indicates a minor enamel lined invagination that is restricted within the crown of the tooth and does not cross beyond the cemento-enamel junction.

Type II, the enamel-lined invagination extends into the pulp chamber without any communications to either the pulpal or periodontal ligament.

Type III DI is further sub classified into Type III A and Type III B. Type III A is an invagination seen running into the root, communicating laterally with the periodontal ligament without pulpal involvement. Type III B invaginates into the root communicating with the periodontal ligament at the apical foramen and is lined usually by enamel and in rare instances by cementum [10].

Discussion

DI mainly occurs in permanent dentition, even if cases have been described in deciduous dentition and supernumerary teeth. The maxillary teeth are more commonly affected than mandibular teeth. Among permanent teeth, the maxillary lateral incisors are the most commonly affected tooth as is the case here, followed by central incisors, canines and molars [10].

The clinical appearance of the crown may vary ranging from a normal form to more unusual forms, such as a greater labiolingual diameter, peg-shaped, barrel-shaped and conical and talon cusp. The radiographic examination shows a radiopaque invagination of density equal to enamel and could extend from the cingulum to the root canal.

The defects may vary in size and shape from a loop-like, pearshaped or slightly radiolucent structure to a severe form resembling a tooth within a tooth. The invaginated tooth usually shows no clinical symptoms and in most cases it is highlighted occasionallyin a radiograph; however, a deep foramen caecum susceptible to caries may be the first clinical sign indicating the existence of an invaginated tooth.The accentuated pit within the DI accumulates debris resulting in rapid initiation and progression of dental caries with subsequent involvement of the pulp, resulting in periapical pathology [11,12]. The reported case involved a maxillary lateral incisor which showed an accentuated lingual pit. The unusual case described in this study reveals a tooth of preserved vitality containing a DI with necrotic pulp.A tooth with DI presents technical difficulties in clinical management and especially forthe endodontic treatmentwhen necessary. The inaccessibility of the anomaly and its variable presentation along with its proximity from the pulpal chamber and of canal anomalies presents treatment challenges. Partially developed roots and tortuous pit further complicate the treatment of DI. Treatment for Type I DI includes minimally invasive procedures and sealing of the defect with restorative materials. Bishop and Allani [13] indicated that minor debridement with ultrasonic instruments and use of sealants may be successful in Type I and Type II cases [13]. However, most cases the treatment require further invasive procedures, including root canal therapy due to extension of the defect over a period of time. In cases with pulpal involvement, the treatment could range from conservative pulpotomy to a full root canal treatment, preferably with the use of a dental endoscope.

In teeth with open apices, various restorative materials have been utilized, including calcium hydroxide, zinc oxide cement, MTA and guttapercha. Surgical treatments may be indicated in cases of DI with extensive infection in the periapical region with complex root canal anatomy and incomplete root canal development. The case reported belongs to DI Type III A with a separate canal tract communicates with parodontal space.

The use of MTA as a filling material is becoming popular in cases of DI, due to its advantageous characteristics, such as sealing capacity, biocompatibility and apical healing stimulation [14]. The so-called "one-step apexification technique" with MTA is an interesting alternative to successive changes of calcium hydroxide dressing. In the present case, the use of MTA was to fill the root canal of malformation after removal the necrotic pulp and to seal the wide orifice on radicular surface of tooth root. Some authors have stated that endodontic treatment of the main canal is not necessary if there is no connection with the invaginated canal or when pulp necrosis is not detected [15]. In the case reported herein, the periapical radiography revealed two separate canals. We preferred the endodontic treatment both of tract canal of malformation and of primary root canal to avoid complications in case of a possible second surgical time or to avoid a root canal therapy even more complex in the case of a second

intervention endodontic for the difficulties that may be added for the formation of tertiary dentin.

References

1. Schulze C. Developmental abnormalities of the teeth and the jaws. In: Gorlin RJ, Goldman HM, editors. Thoma's oral pathology. 6th ed. St. Louis: Mosby. 1970; 96-183.
2. Jaramillo A, Fernández R, Villa P. Endodontic treatment of dens invaginatus: a 5-year follow-up. Oral Surg Oral Med Oral Pathol Oral Radiol Endod. 2006; 101: 15-21.
3. Shadmehr E, Kiaani S, Mahdavian P. Nonsurgical endodontic treatment of a maxillary lateral incisor with dens invaginatus type II: A case report. Dent Res J (Isfahan). 2015; 12: 187-191.
4. Kronfeld R. Dens in dente. J Dent Res. 1934; 14: 49-66.
5. Rushton MA. A collection of dilated composite odontomas. Br Dent J. 1937; 63: 65-85.
6. Fischer CH ZurFrage. des Dens in dente. Deutsche Zahn-, Mundund Kieferheilkunde. 1936; 3: 621-634.
7. Sprawson EC. Odontomes. British Dental Journal. 1937; 62: 177-201.
8. Euler H. Die Anomalien, Fehlbildungen und Verstümmelungen der menschlichenZähne. München, Germany: Lehmann. 1939; 62-67.
9. BrusztP.ÜberdieEntstehungdes'Densindente'.SchweizerMonatsschriftfür Zahnheilkunde. 1950; 60: 534-542.
10. Oehlers FA. Dens invaginatus I. Variations of the invagination process and associated anterior crown forms. Oral Surgery, Oral Medicine and Oral Pathology. 1957; 10: 1204-1218.
11. Nosrat A, Schneider SC. Endodontic Management of a Maxillary Lateral Incisor with 4 Root Canals and a Dens Invaginatus Tract. J Endod. 2015; 41: 1167-1171.
12. Patil S, Yadav N, Patil P. Non-syndromic occurrence of multiple dental and skeletal anomalies: a rare case report and brief literature review. J ClinDiagn Res. 2014; 8: 28-30.
13. Bishop K, Alani A. Dens invaginatus. Part 2: Clinical, radiographic features and management options. Int Endod J. 2008; 41: 1137-1154.
14. Brooks JK, Ribera MJ. Successful nonsurgical endodontic outcome of a severely affected permanent maxillary canine with dens invaginatusOehlers type 3. J Endod. 2014; 40: 1702-1707.
15. Goncalves A, Goncalves M, Oliveira DP, Goncalves N. Dens invaginatus type III: report of a case and 10-year radiographic follow-up. IntEndod J 2002; 35: 873-879.