Annals of Clinical Case Reports

Case Series
Published: 25 Aug, 2021

CT and MRI Appearances of Abdomen and Pelvis Gossypibomas at Varied Time after Cesarean Resection

Yu-Feng Bai[1#], Juan-Qin Niu[1#], Chao Zhang[1], Jun-Tao Lu[1], Ju-Jing Liang[1], Jing-Zhong Liu[1] and Wen Wang[1,2]**

[1]Department of Radiology, The 944th Hospital of Joint Logistics Support Force of People's Liberation Army, China

[2]Department of Radiology, Functional and Molecular Imaging Key Lab of Shaanxi Province, Tangdu Hospital, Fourth Military Medical University, China

[#]These authors contributed equally to this work

Abstract

The incidence of gossypiboma is considerably higher in open cavity surgeries, among which cesarean section ranks number one, however, it is difficult to diagnose abdomen or pelvic gossypibomas after cesarean section. We retrospectively analyzed the clinical and imaging data of 3 pathologically confirmed gossypiboma patients at varied time after cesarean resection. At four months after cesarean resection, gossypiboma near the small intestine caused fistula and intestinal obstruction. Soft tissue density along the intestinal canal, made the "segmental honeycomb sign" and "truncation", with metal markings on the edge on CT. Long T1 and short T2 signals and DWI metal artifacts were revealed on MRI. Eighteen months after cesarean resection, gossypiboma located in the peritoneal and intestinal space. MRI demonstrates cystic and solid features, with "vortex like sign" and obvious ring enhancement on contrast-enhanced scan. Five years after cesarean resection, gossypiboma was palpated in the right middle and lower abdomen. MRI revealed a round mass of long T1 signal with mixed T2 signal, as well as swirling lower signal in T2WI, T2WI-FS and DWI were observed. In CT and MRI examinations for suspected gossypiboma after cesarean resection, "honeycomb sign" and "vortex like sign" are the characteristic appearances; gauze transplanted into the intestine may show "truncation sign". DWI metal artifacts and surgical history can aid the diagnosis.

Keywords: Gossypiboma; Abdominal; Computed tomography; Magnetic resonance imaging; Diagnosis

OPEN ACCESS

Correspondence:
Wen Wang, Department of Radiology, Functional and Molecular Imaging Key Lab of Shaanxi Province, Tangdu Hospital, Fourth Military Medical University, Xi'an 710038, China, Tel: 86-29-84778689;
E-mail: wangwen@fmmu.edu.cn
Jing-Zhong Liu, Department of Radiology, The 944th Hospital of Joint Logistics Support Force of People's Liberation Army, Jiu quan 735000, Gansu, China, Tel:13919934167;
E-mail: 2793949748@qq.com

Received Date: *02 Aug 2021*
Accepted Date*: 20 Aug 2021*
Published Date*: 25 Aug 2021*

Citation:
Bai Y-F, Niu J-Q, Zhang C, Lu J-T, Liang J-J, Liu J-Z, et al. CT and MRI Appearances of Abdomen and Pelvis Gossypibomas at Varied Time after Cesarean Resection. Ann Clin Case Rep. 2021; 6: 1971.
ISSN: 2474-1655

Introduction

A gossypiboma or textiloma is an infrequent complication of any surgical procedure associated with potentially dangerous health problems for the patient [1-3] and legal implications for the surgeon [4]. The medico legal implications and widespread negative press coverage explain why many cases are not reported, with the literature consisting only of case reports [5-7]. The incidence of gossypiboma is generally low, but is considerably higher in surgeries performed with open cavities, among which cesarean section ranks number one [8]. Early and accurate diagnosis of gossypiboma plays very important role for delivering proper treatment. However, the diagnosis of gossypibomas is challenging as the symptoms are usually nonspecific, may appear years after surgery, and may be misdiagnosed as a tumor [9] or abscess [10] in the abdomen and pelvis.

Depending on the retained time of foreign bodies or sponge, exudative and aseptic fibrous alterations may occur, leading to early abscess or late fistulas [11] as well as clinically silent for many years [12,13]. Thus, medical imaging is important in giving accurate diagnosis. Ultrasonography is a cheap and easy imaging modality for gossypiboma diagnosis; however, it may not be sufficient to evaluate the abdominal or pelvic organs in the cases of suspected gossypibomas in women after cesarean resection [14]. Thus recognizing computed tomography and MR features of gossypibomas after varied foreign body retain time in this population is very important.

In this study, we retrospectively enrolled 3 women who developed gossypibomas at varied time after cesarean resection and correlated their imaging features with the pathological findings.

Case Series

Case 1. Gossypiboma in a woman at 4 months after cesarean resection

A 29-year old female was admitted to the hospital due to intermittent abdominal pain, abdominal

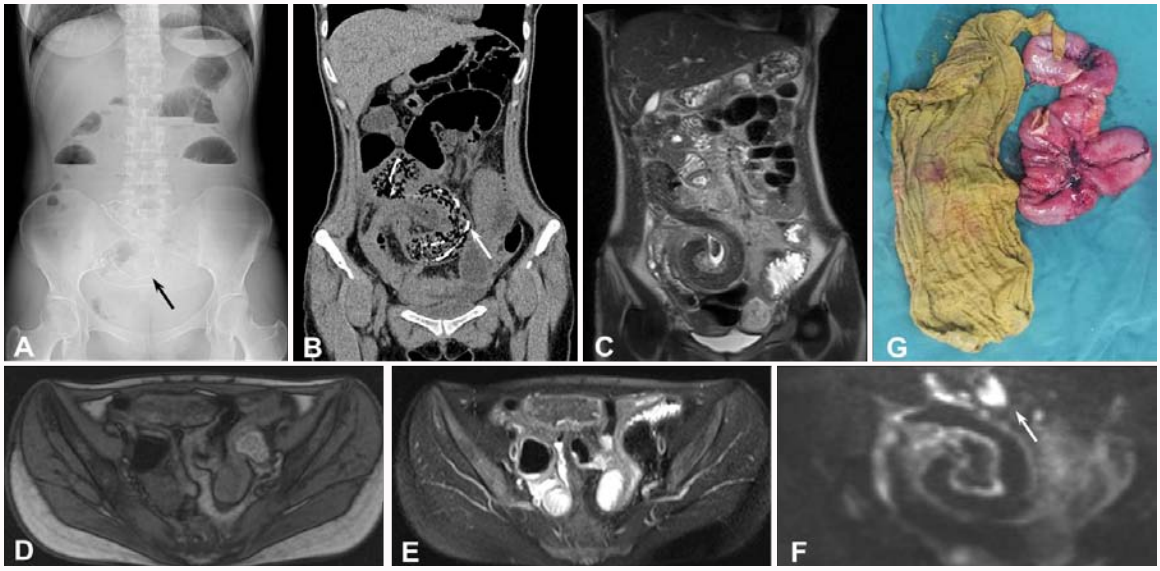

Figure 1: A 29-year-old woman who presented with intestinal obstruction 4 months after caesarean section. **A**: KUB showed a high-density image in the hypogastrium (black arrow). **B**: Unenhanced CT scan shows honeycombed gauze foreign body in small intestine with visible metal marks (white arrow). **C-F**: MRI shows foreign body in small intestine, the intestinal wall is swollen and thickened, and lymph node enlargement around the intestine was clearly shown (white arrow).

distension, and anal cessation of exhaust and defecation for more than 1 month and getting worse for 2 weeks. More than 1 month before admission, intermittent abdominal pain occurred without obvious reason, mainly in the upper abdomen. The pain became worse after eating, with occasional nausea and vomiting. Recently, she has lost about 15 Kg of body weight. She underwent a cesarean section 4 months ago. A 10-cm transverse surgical scar was observed at the lower abdomen, together with the whole abdomen tenderness, especially the middle and lower abdomen. Abdomen plain radiograph revealed high density fold line of the lower abdomen (Figure 1A). Plain CT scan revealed tortuous and coiled soft tissue density shadows in the right middle and lower abdominal small intestine, and circular high-density shadows at the edge. Multiple gas shadows were observed with "segmental honeycomb" changes. Edema and thickening of the intestinal wall and mesentery, dilation, fluid accumulation and gas accumulation in the upper intestinal layer were also observed (Figure 1B). MRI showed that the right middle and lower abdominal small intestine was dilated, with short T2 signal shadows along the intestinal canal lumen, and low DWI signal of metal artifacts on the edge, corresponding to the thickened intestinal wall. Besides, high T2WI-FS and DWI signal, and multiple enlarged lymph nodes were observed around the intestine and at the mesenteric roots (Figure 1C-1F). During the laparotomy operation, the small intestine was found to have clumps of adhesives at 150 cm from the ileocecal part, and the adhesive bowel was about 40 cm long. An enveloped internal fistula was formed locally. Pathological examination revealed intestinal wall tissue, mucosal tissue degeneration and necrosis, submucosal vascular dilation, congestion, inflammatory cell infiltration (Figure 1G). Based on the patient history and examinations, the diagnosis of intestinal ulcer and perforation with foreign body (gauze) was made.

Case 2. Gossypiboma in a woman at 18 months after cesarean resection

A 38 years old female was admitted in our hospital due to the intermittent abdominal pain and discomfort for 6 months. Physical examination showed an old surgical scar in the middle of the lower abdomen, and a soft mass about 8 cm × 5 cm in size was palpable in the left abdomen, with low mobility. She had a caesarean section 18 months ago and had a history of massive bleeding and blood transfusion. MRI examination showed a round long T1 mass with mixed T2 signal ("swirl-like" sign) about 5.5 cm × 4.4 cm on the left middle-lower abdomen, uneven high signal on DWI, complete capsule at the edge of the mass. Furthermore, obvious ring enhancement in the capsule and no enhancement in the center were observed on enhanced MR scan (Figure 2A-2D). Laparotomy revealed that the mass in the left middle-lower abdomen was closely

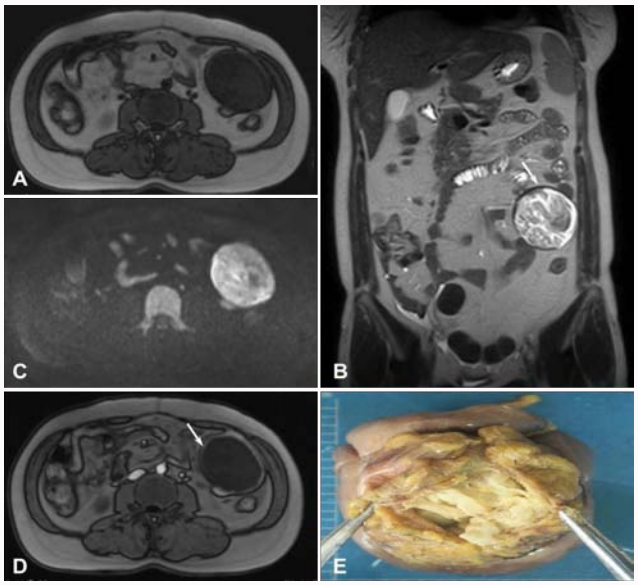

Figure 2: A 38-year-old woman with a mass in her left middle and lower abdomen18 months after caesarean section. **A-D**: MRI plain and enhancement scan showed a mass in her abdomen with complete capsule at the margin (white arrows), obviously ring enhancement was observed in the capsule, but no enhancement was found inside. E: Postoperative view of the gross shows there was a retained surgical gauze foreign body in the mass.

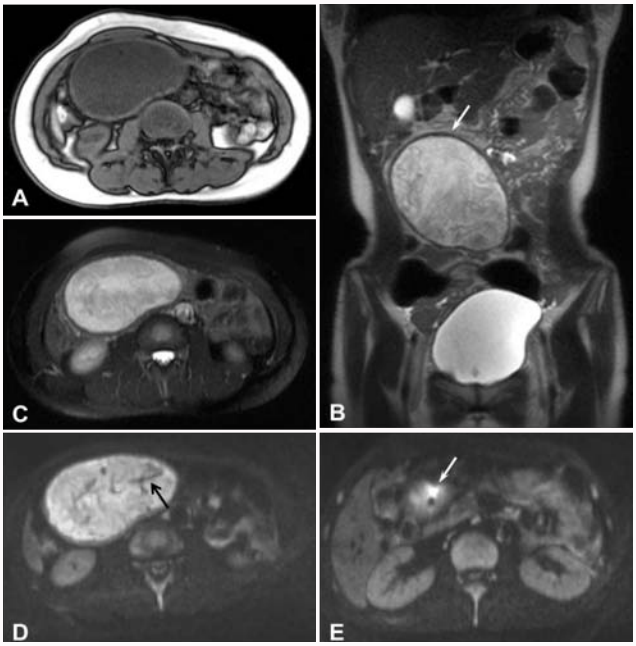

Figure 3: A 30-year-old woman with a mass in her abdomen 5 years after caesarean section. **A-E**: Unenhanced MRI scan showed a mass in her abdomen with complete capsule at the margin (white arrow), DWI showed swirling slightly lower signal shadow and strip lower signal band (black arrow) in the high signal background of the mass, and magnetic sensitivity artifacts (white arrow) can be seen locally.

adhered to the intestinal canal and mesangium, with a gray yellow surface. A cystic cavity was visible on the cut surface, and there were pale yellow turbidity fluid and gauze masses in the cavity. Pathological examination revealed subserosal foreign body (gauze mass), surrounding mesangial and omental tissue, and foreign body granuloma formation in the small intestine (Figure 2E).

Case 3. Gossypiboma in a woman at 5 years after cesarean resection

A 30-year old female with intermittent abdominal pain for 2 months and abdominal mass for 1 week was admitted. She underwent cesarean section 5 years ago, tubal ligation 4 years ago and myomectomy 1 year ago. MRI examination showed a round long T1 mass (about 13.1 cm × 9.7 cm) with mixed T2 signal (Figure 3A, 3B) in the right middle and lower abdominal cavity. Slightly lower "swirling" sign was observed in T2WI and T2WI-FS images, and isoT1-short T2 signal envelope at the edge of the mass (Figure 3C). Slightly lower vortex signal shadow and lower strip band signal can be seen within high signal background (Figure 3D). On the other layer of DWI, magnetic sensitivity artifacts can be seen around the low-signal shadow (Figure 3E). Laparotomy revealed a cystic mass at 50 cm away from the ileocecal part, which encapsulated the ileum and adhered to the adjacent small intestine. The section was cystic, containing yellow fluid and gauze mass, and granulation tissue formation was observed on the cyst wall. Pathological examination confirmed the gauze retention and fibrous tissue wrap, with foreign body granuloma.

Discussion

Gossypiboma developed after cesarean section is the most common one among all gossypibomas [1,2], however, its diagnosis remains challenging and should be considered in the differential diagnosis of a mass or neoplasm, abscess, lymphocele, or nonspecific imaging findings in a postoperative patient [3-6].

Imaging is the most efficient diagnostic approach for gossypiboma after cesarean section. Plain radiography is the most common technique but with a relatively high false-negative rate [7]. Because of its higher sensitivity, computed tomography is the first-choice diagnostic imaging technique for excluding gossypibomas [8]. Depending on the clinical situation, magnetic resonance imaging and other relevant radiological techniques such as barium contrast studies may also be used [9].

In the current study, we presented typical "honeycomb sign" and "vortex like sign" for all 3 gossypibomas after cesarean section, which is consistent with previous studies showing a spongiform pattern with a radiodense linear structure [10-16]. Besides, based on the temporal development and location of gossypiboma, varied imaging features such as cyst, solid soft tissue, or well circumscribed capsulated mass, can be observed. However, these features were not closely related with the disease duration, making the diagnosis of gossypiboma after cesarean section still a clinical challenge. Combining patient histories as well as symptoms with imaging features are important to make the accurate diagnosis.

References

1. Alis H. Surgical intervention may not always be required in gossypiboma with intraluminal migration. World J Gastroenterol. 2007;13(48):6605-7.
2. Bilali V. Gossypiboma in abdomen: Retained surgical gauze after a cesarean section. G Chir. 2019;40(4):338-42.
3. Gavric Lovrec V. Retained surgical needle and gauze after cesarean section and adnexectomy: A case report and literature review. J Int Med Res. 2018;46(11):4775-80.
4. Haegeman S. Textiloma complicated by abscess-formation, three years after surgical repair of abdominal aortic aneurysm. JBR-BTR. 2008;91(2):51-3.
5. Hariharan D, Lobo DN. Retained surgical sponges, needles and instruments. Ann R Coll Surg Engl. 2013;95(2):87-92.
6. Kaiser CW. The retained surgical sponge. Ann Surg. 1996;224(1):79-84.
7. Kumar GVS. Imaging of retained surgical items: A pictorial review including new innovations. Indian J Radiol Imaging. 2017;27:354-61.
8. Li QY. Sonographic appearances of retained surgical sponges in the abdomen and pelvis. J Clin Ultrasound. 2020;48(3):156-9.
9. Lu YY. Calcified reticulate rind sign: A characteristic feature of gossypiboma on computed tomography. World J Gastroenterol. 2005;11(31):4927-9.
10. Machado DM. Thoracic textilomas: CT findings. J Bras Pneumol. 2014;40(5):535-42.
11. Mavrigiannaki PE. Gossypiboma: A rare abdominal lesion of women after cesarean section, usually misdiagnosed as a neoplasm. Clin Exp Obstet Gynecol. 2011;38(3):294-6.
12. Okten AI, Adam M, Gezercan Y. Textiloma: A case of foreign body mimicking a spinal mass. Eur Spine J. 2006;15(5):626-9.
13. Silva SM, Sousa JB. [Gossypiboma after abdominal surgery is a challenging clinical problem and a serious medicolegal issue]. Arq Bras Cir Dig. 2013;26(2):140-3.
14. Susmallian S, Raskin B, Barnea R. Surgical sponge forgotten for nine years in the abdomen: A case report. Int J Surg Case Rep. 2016;28:296-9.
15. Tacyildiz I, Aldemir M. The mistakes of surgeons: "gossypiboma". Acta Chir Belg. 2004;104(1):71-5.
16. Yildirim T, Parlakgumus A, Yildirim S. Diagnosis and management of retained foreign objects. J Coll Physicians Surg Pak. 2015;25(5):367-71.