Annals of Clinical Case Reports

Case Report
Published: 15 Sep, 2016

Coexistence of Lung Cancer and Primary Lymph Nodes Tuberculosis Diagnosed by Cancer Staging: A Report of a Rare Case

Aysun Sengul[1], Sinan Arslan[1], Fatma Tasolar[1] and Oguz Kapicibasi[2]*

[1]Department of Pulmonology, KocaeliDerince Education and Research Hospital, Turkey

[2]Department of Thoracic Surgery, IzmitSeka State Hospital, Turkey

Abstract

Lung cancer (LC) and lymph node (LN) tuberculosis are two common entities around the world. 18F-fluorodeoxyglucose (18F-FDG) positron emission tomography-computed tomography (PET-CT) is frequently used in LC, because accurate lymph node (LN) staging is critical to choose appropriate treatment and to predict prognosis. However, increased 18F-FDG uptake is also seen in infected or inflammatory processes, such as tuberculosis. We reported a case of 57-year-old woman with lung cancer diagnosed by bronchoscopic biopsy with concomitant mediastinal and cervical LN involvement with malignant features due to the increased 18F-FDG uptake. However, mediastinal and cervical LN biopsies established the diagnosis of lymph nodes tuberculosis. There was no evidence of pulmonary tuberculosis. We concluded that NSCLC and primary LN tuberculosis was coexisted and the treatment approach was changed radically. The case is a good sample demonstrating vital importance of biopsying LN involvement with increased 18F-FDG uptake during lung cancer staging.

Keywords: Lung cancer; Tuberculosis; F-18 fluorodeoxyglucose; Positron emission tomography; Biopsy

OPEN ACCESS

Correspondence:
Aysun Sengul, Department of Pulmonology, KocaeliDerince Education and Research Hospital, Kocaeli, Turkey, Tel: 905434247360; Fax: 90 0262 233 46 41;
E-mail: dr.aysunsengul@hotmail.com

Received Date: *07 Aug 2016*
Accepted Date*: 09 Sep 2016*
Published Date*: 15 Sep 2016*

Citation:
Sengul A, Arslan S, Tasolar F, Kapicibasi O. Coexistence of Lung Cancer and Primary Lymph Nodes Tuberculosis Diagnosed by Cancer Staging: A Report of a Rare Case. Ann Clin Case Rep. 2016; 1: 1136.

Introduction

Non-small cell lung cancer (NSCLC) is a major cause of cancer-related mortality on a worldwide scale. Accurate staging of lymph nodes (LN) is critically important for NSCLC treatment planning and predicting prognosis [1]. Positron-emission tomography/computed tomography (PET/CT) using the glucose analog 18F-fluorodeoxyglucose (FDG), is a useful method in distinguishing malignant lesions from benign lesions. However, increased 18F-FDG uptake is not specific to tumors, and can be seen secondary to increased glucose utilization by inflammatory cells and macrophages in certain infectious and inflammatory conditions such as tuberculosis, sarcoidosis, and pneumoconiosis [2-4]. We present a case with mediastinal and cervical tuberculous lymphadenitis with increased 18F-FDG uptake in PET/CT, diagnosed during staging of non-small cell lung cancer (NSCLC).

Case Presentation

A 57-year-old female patient presented at our outpatient clinic with cough, sputum, chest pain and dyspnea that lasted for the past 2 weeks. The patient, who was on oral antidiabetics for type 2 diabetes, was not a smoker, but had a history of exposure to second-hand smoke. In auscultation there were inspiratory rales in mid-lower left zone. A non-homogenous opacity was seen in the mid-lower left zone on posterior-anterior chest x-ray (Figure 1). Chest CT revealed a mass lesion obstructing the bronchus of upper left lobe surrounded by atelectasis in the periphery. An endobronchial lesion was detected in the aperture of upper left lobe and a biopsy was performed (Figure 1). Histopathologic evaluation of upper left lobe endobronchial biopsy revealed non-small cell carcinoma with features primarily suggesting squamous cell carcinoma (Figure 2). There was a centrally located hypermetabolic mass (SUVmax: 18.4) with malignant features on upper left lung, and images suggesting metastatic lesions (SUVmax: 9) in multiple mediastinal and cervical lymph nodes on PET/CT (Figure 2). Mediastinoscopy Mediastinal lymph node biopsies numbered 4L, 4R, and 7, and cervical lymph node biopsies revealed granulomatous inflammation with extensive necrosis (Figure 2) and, established the diagnosis of lymph nodes tuberculosis. There was no evidence of pulmonary tuberculosis at the diagnostic work-up.

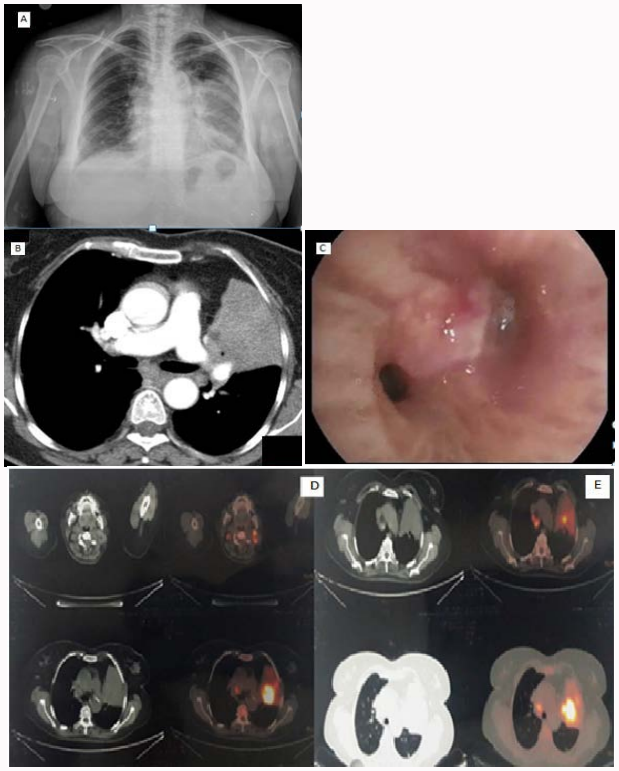

Figure 1: (a) Nonhomogeneous increase in opacity in left lung, mid-lower zone in posteroanterior chest X-ray. (b) Mass lesion obstructing left upper lobe bronchus, and atelectasis on chest CT. (c) An endobronchial lesion obstructing left upper bronchus was visualized in fiberoptic bronchoscopy under local anesthesia. (d) Hypermetabolic mass lesion with malignant features centrally located on left upper lober on PET/CT (SUVmax: 18,4). (e) Lesions suggesting metastasis in multiple mediastinal and cervical lymph nodes on PET/CT (SUVmax: 9).

TNM staging was concluded as T3 N0 M0, stage IIB. The patient was diagnosed with NSCLC and primary tuberculous lymphadenitis, and started on antituberculous treatment. Surgery was planned for the malignancy.

Discussion

While there is an ongoing battle against tuberculosis in our country, incidence rate of tuberculosis in Turkey is still as high as 18 in 10000. Among all tuberculosis cases in our country, rate of extrapulmonary tuberculosis is 37.2% [5]. Most common presentation of extrapulmonary tuberculosis is tuberculous lymphadenitis.

Pulmonary tuberculosis and mediastinal lymph node tuberculosis are known to be associated with false positive 18F-FDG PET results. Increased lung cancer risk in patients with tuberculosis might be associated with immune suppression induced by infection [6]. Conversely, immune suppression induced by cancer may also cause increased rate of tuberculosis reactivation [7]. During cancer staging in our case, PET/CT showed lymphadenitis with high 18F-FDG uptake that initially suggested malignancy. While its existence initially suggests malignancy, importance of histopathologic evaluation should be highlighted.

Cervical and mediastinal lymph node enlargement may be usually linked to lymphoma, metastatic carcinoma, sarcoidosis, and direct infection or hyperplastic reactions due to infections [8-13]. Mediastinal lymph node staging is important in lung cancer in selecting treatment approach and predicting prognosis. While

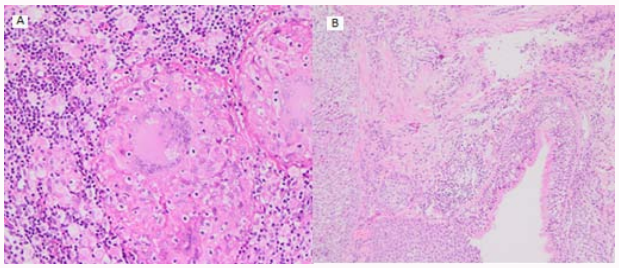

Figure 2: (a) Non-caseating granulomatous inflammation in mediastinal lymph node biopsy, hematoxylin & eosin staining. (b) Non-small cell carcinoma with features of squamous cell carcinoma, endobronchial biopsy, hematoxylin & eosin staining.

surgery is an option when there is no lymph node involvement or distant metastasis, with lymph node involvement, treatment options are definitive chemotherapy and radiotherapy [14-16]. In lymph node involvement, invasive diagnostic approaches like image-guided biopsy (CT, endoscopic ultrasound), transbronchial lymph node biopsy, and thoracoscopic or mediastinoscopic biopsy should be used in distinguishing malignant lesions from benign lesions.

In conclusion, we presented a case of coexistence of mediastinal and cervical tuberculosis with lung cancer with a false positive result in 18F-FDG PET/CT. Tuberculosis can affect any organ. The most common presentation is lymph node tuberculosis. In patients with malignancies, tuberculosis can be missed because of increased 18F-FDG uptake, however, in countries where tuberculosis is common, evaluation should be meticulous and all lymph node groups should be histopathologically evaluated, because the treatment approach might be changed radically, as in our case. So, our case is a good sample demonstrating vital importance of biopsying LN involvement with increased 18F-FDG uptake during lung cancer staging.

References

1. Mountain CF. Revisions in the International System for Staging Lung Cancer. Chest. 1997; 111: 1710-1717.
2. Rosenbaum SJ, Lind T, Antoch G, Bockisch A. False-positive FDG PET uptake-the role of PET/CT. EurRadiol. 2006; 16: 1054-1065.
3. Chang JM, Lee HJ, Goo JM, Lee HY, Lee JJ, Chung JK, et al. False positive and false negative FDG-PET scans in various thoracic diseases. Korean J Radiol. 2006; 7: 57-69.
4. Kubota R, Kubota K, Yamada S, Tada M, Ido T, Tamahashi N. Microautoradiographic study for the differentiation of intratumoral macrophages, granulation tissues and cancer cells by the dynamics of fluorine-18 fluorodeoxyglucose uptake. J Nucl Med. 1994; 35: 104-112.
5. World Health Organization: Global Tuberculosis Report 2013. 2013.
6. Rybacka-Chabros B, Mańdziuk S, Berger-Lukasiewicz A, Dańko-Mrozińska M, Milanowski J. The coexistence of tuberculosis infection and lung cancer in patients treated in pulmonary department of Medical Academy in Lublin during last ten years (1990-2000). Folia Histochem Cytobiol. 2001; 39: 73-74.
7. Kim HR, Hwang SS, Ro YK, Jeon CH, Ha DY, Park SJ, et al. Solid-organ malignancy as a risk factor for tuberculosis. Respirology. 2008; 13: 413-419.
8. McLoud TC, Meyer JE. Mediastial metastases. Radiol Clin North Am. 1982; 20: 453-468.
9. Filly R, Bland N, Castellino RA. Radiographic distribution of intra thoracic disease in previously un treated patients with Hodgkin's disease and non-

Hodgkin's lymphoma. Radiology. 1976; 120: 277-281.

10. Choyke PL, Sostman HD, Curtis AM, Ravin CE, Chen JT, Godwin JD, et al. Adult-onset pulmonary tuberculosis. Radiology. 1983; 148: 357-362.

11. Fraser RS, Müller NL, Colman N, Pare PD. Fraser and Pare's Diagnosis of Diseases of the Chest. philadelphia: Saunders; 1999.

12. Waldron JA Jr, Dohring EJ, Farber LR. Primary large cell lymphom as of the mediastinum: an analysis of 20 cases. Semin Diagn Pathol. 1985; 2: 281-95.

13. Berkmen YM. Radiologic aspects of intrathoracicsarcoidosis. Semin Roentgenol. 1985; 20: 356-375.

14. Lee BE, Redwine J, Foster C, Abella E, Lown T, Lau D, et al. Mediastinoscopy might not be necessary in patients with non-small cell lung cancer with mediastinal lymph nodes having a maximum standardized uptake value of less than 5.3. J Thorac Cardiovasc Surg. 2008; 135: 615-619.

15. Lewis PJ, Salama A. Uptake of fluorine- 18-fluorodeoxyglucose in sarcoidosis. J Nucl Med. 1994; 35: 1647-1649.