Annals of Clinical Case Reports

Case Series
Published: 25 Jan, 2017

Can another Surgical Approach for the Cerebrospinal Fluid Fistulas Change the Rehabilitative Outcome in a Significant Way?

Francesco Marchetti[1], Tempesta M[1], Carmen Cantisani[2] and Bruno Carlesimo[1]*

[1]Department of Plastic Surgery, "Sapienza" University of Rome, Italy

[2]UOC of Dermatology, "Sapienza" University of Rome, Italy

Abstract

Cerebrospinal fluid fistula represents one of the most dangerous but rare complication, in the spinal surgery, with a high risk of morbidity for meningitis too. Its treatment results difficult for the high incidence of relapses. As regards to the rehabilitation, the presence of the cerebrospinal fluid fistula implies great care, related to the entity of the possible neurological damage, which could hesitate also in paraplegia. Many treatments were described in literature for the repair of dura mater defects; we report our experience about the treatment of the cerebrospinal fluid fistula through the use of three local fasciocutaneous and muscular flaps, opposed and overlapped.

Keywords: Cerobrospinal fluid fistula; Z-plasty; Local flaps

Introduction

Cerebrospinal fluid fistula, a rare and dangerous complication, could, often, be associated with an infection and a dehiscence of the surgical wound, hesitating in great loss of substance of the middle line, also with a high risk of morbidity for meningitis. This complication could be potentially dangerous for patient's life and its treatment results difficult for the high incidence of relapses [1-3]. Many treatments were described in literature as regard to dura mater defects reconstruction and cerebrospinal fistula closure. These treatments differ from simple direct suture, the use of TISSUCOL and SURGICELL, grafts from fascia lata and muscular flaps associated or not with a ventriculostomy and cerebrospinal fluid derivation [4].

As regards to the soft tissues defect covering, associated with cerebrospinal fluid fistula, many Authors described the use of local fasciocutaneous flaps in addition to muscular flaps like latissimus dorsii, trapezium, gluteus maximus and the paraspinal muscles [5].

Case Series

From October 2001 till now at the Policlinico Umberto I hospital, ten patients were referred to the plastic surgeon inpatient clinic. Eight of them affected by cerebrospinal fluid fistula and two by lymphatic fistula. They were evaluated at baseline and after 1, 3, 6 and 12 months according to our protocols. Patients were verbally informed about treatment procedures, benefit limits, side effects, and alternative treatment options and then all of them signed the consent form, before the procedure, allowing taking clinical pictures. The study was performed as an analysis produced by an extrapolation of data, coming from our routine medical records.

The final outcome was recorded by a visual evaluation made by plastic surgeons, taking into account also the patient's perception. The cerebrospinal fluid fistula, as result of laminectomy, was treated in all cases with a direct suture of the dura mater, covering it with SURGICELL and TISSUCOL and with cerebrospinal fluid drainage maintained for at least 15 days. We decided to utilize this procedure to avoid recurrences of the fistula by avoiding the formation of dead spaces, where the liquor could expand and start creating new fistulas, as we observed in all the cases never treated with this peculiar kind of surgery. After a thorough debridment of the defect, we prepared two sacrospinal muscular flaps from each side, which were sutured together through a Z plasty, to replace the defect made by the previous laminectomy. Afterward, we covered the muscular layer with two lumbo-dorsal fascial flaps and with two cutaneous flaps, all sutured with a Z plasty.

OPEN ACCESS

Correspondence:
Francesco Marchetti, UOC of Plastic Surgery "Sapienza" University of Rome, Viale del Policlinico 155, 00161 Rome, Italy, Tel: 393488894830; Fax: 39064997693;
E-mail: Francesco.marchetti@hc-sc.gc.ca

Received Date: *14 Nov 2016*
Accepted Date: *23 Jan 2017*
Published Date: *25 Jan 2017*

Citation:
Marchetti F, Tempesta M, Cantisani C, Carlesimo B. Can another Surgical Approach for the Cerebrospinal Fluid Fistulas Change the Rehabilitative Outcome in a Significant Way?. Ann Clin Case Rep. 2017; 2: 1242.

Copyright *© 2017 Marchetti F. This is an open access article distributed under the Creative Commons Attribution License, which permits unrestricted use, distribution, and reproduction in any medium, provided the original work is properly cited.*

Figure 1: Preoperative appearance of cerebrospinal fluid fistula.

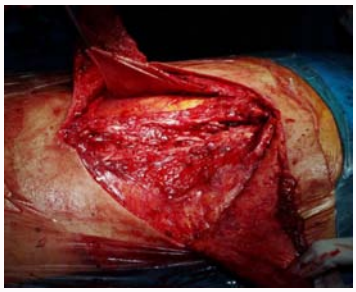

Figure 2: Exposure of spinal cord after flaps harvesting.

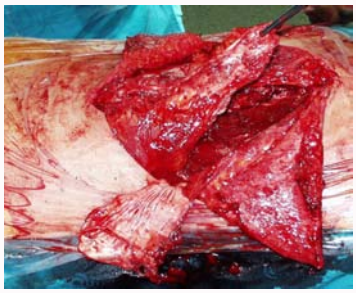

Figure 3: Deep closure with sacrospinal muscular and fascial flaps.

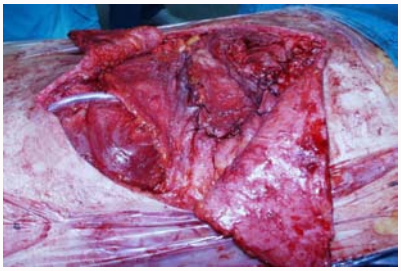

Figure 4: Muscolar and fascial flaps sutured togheter through a Z plasty.

Figure 5: Cutaneous closure through two cutaneous flaps sutured with Z plasty (lateral view).

Figure 6: Cutaneous closure through two cutaneous flaps sutured with Z plasty (front view).

All muscular, fascial and cutaneous flaps were placed opposed in different layers, in way that sutures weren't in continuation between them. For each anatomic layer, that is submuscular, subfascial and subcutaneous ones, we placed aspirative drainages. We removed them on the 2nd, 7th and 15th day respectively.

All patients were submitted to antibiotic therapy based on bioptical intraoperative finding. We planned follow-up visits after 1, 3, 6, 12 and 24 months from the surgical treatment, so we can determine the effectiveness of this surgical procedure with long term results.

Results

Patients were six men and four women aged from 30 to 72 (average 58,8 ; mean 70 years). The basis pathology was in six cases a lumbar stenosys localized at level L3-L5, in two cases a spondylolisthesis of the tract L3-L5 and in other two cases a tethered cord syndrome associated with a lombosacral lipoma. We observed the relapse of the fistula during the 15th-18th day; therefore, we decided to repair it another time by using three local fasciocutaneous flaps above muscular flaps, opposed and overlapped. All patients submitted to follow-up visits after 1, 3, 6 and 12 months from the surgical treatment have a complete resolution of the cerebrospinal fluid and lymphatic fistula. We didn't observe intra-operative or post-operative complications. In each patient we observe a good posture, without changes by functional deficit, absence of pain and a good aesthetic result.

Discussion

Surgical treatments suggested for the resolution of cerebrospinal fluid fistulas foresee the use of wide muscular flaps as the latissimus dorsii, the trapezium and the gluteus maximus that, in most cases, could give serious postural and functional deficit [6].

We suggest a surgical treatment that restricts the rotational degree and the muscular movement almost maintaining all the muscular bone insertions so that we could limit the functional deficit. The scar sequelae areas formed on the dura mater, cooperate in the closure of the fistula and avoid the formation of dead places, that could be areas of gathering for liquor, by the formation of a kind of "pseudodura".

We think that the particular order of the three muscular, fascial and cutaneous flaps overlapped and placed in a way in which sutures don't have continuity between them, could create a sort of tissue barrier that could avoid the creation of a linear transit for the leakage of liquor. Sutured areas represent the place with less resistance, their placement could create areas easily crossed by the liquor. As regard rehabilitation, we observed an earlier return to daily activities, with minimal human and economic waste.

In the end, the reduced upsetting of layers surrounding the lesion limits the postural changes and the following rehabilitative restoration will result less difficult (Figure 1-6).

References

1. Couture D, Branch CL Jr. Spinal pseudomeningoceles and cerebrospinal fluid fistulas. Neurosurg Focus. 2003; 15: E6.
2. Garcia-Correa G, Aguilar-Sibilla CA, Murguia-Corral R, Espinosa-de los Monteros P. Conservative management of postoperative lymphatic fistula. Cir Cir. 2005; 73: 307-310.
3. Sakikawa Y, Kobayashi H, Nomura Y. Changes in cerebrospinal fluid pressure in daily life. Ann Otol Rhinol Laryngol. 1994; 103: 959-963.
4. Shimada Y, Hongo M, Miyakoshi N, Sugawara T, Kasukawa Y, Ando S, et al. Dural substitute with polyglycolic acid mesh and fibrin glue for dural repair: technical note and preliminary results. J Orthop Sci. 2006; 11: 454-458.
5. Salvi PF, Midiri G, Tucci G, Lombardi A, Coppola M, Conte S, et al. Rhomboid flap in radical surgical treatment of sacrococcygeal fistulas:Technical notes. G Chir. 2006; 27: 335-338.
6. Raco A, Russo N, Landi A, Dazzi M, Carlesimo B. Lymphatic fluid fistula: an extremely rare complication of posterior lumbar transpedicular screw fixation case report. J Neurosurg Spine. 2006; 4: 421-423.
7. Mullan S. Reflections upon the nature and management of intracranial and intraspinal vascular malformations and fistulae. J Neurosurg. 1994; 80: 606-616.