Annals of Clinical Case Reports

Case Report
Published 04 May, 2022

An Atypical NSTEMI Presentation: SPECT Usefulness at the Waiting Room

*Villa-Ramírez CA[1], Bautista-Pérez-Gavilán A[1], Ibarra-Moreno A[1], Perez-Partida AM[1], Sáenz-Ancira S[1], García-Cárdenas M[1], González-Hernández MA[1],Bermudez-González JL[1], Serrano-Roman J[1], Cabello-Ganem A[1], Arce-Sandoval CR[1], Santoyo-Saavedra AH[1], Vargas-Ahumada J[1], Hernández-Olalde D[1], Alexanderson-Rosas E[1] and Espinola-Zavaleta N[1,2]**

[1]Department of Nuclear Cardiology, National Institute of Cardiology Ignacio Chavez, Mexico

[2]Department of Echocardiography, ABC Medical Center, Mexico

Abstract

A Non-ST Elevation Myocardial Infarction (NSTEMI) is distinguished by an elevation of cardiac enzymes without the characteristic ST-elevation seen on EKG. Due to insufficient diagnostic evidence at clinical presentation, there is a need for additional diagnostic tests. Thus myocardial perfusion imaging aids in complementing the diagnostic and therapeutic approach of these patients.

A 52-year-old woman presented acute chest pain in the Nuclear Cardiology waiting room. An EKG showed no changes in the ST segment. A myocardial perfusion study showed moderate to severe perfusion defects in the territories of the anterior descending, right and circumflex arteries. This evaluation was later confirmed by coronary angiography, demonstrating the need for further evaluation of perfusion in these patients.

Keywords: NSTEMI; Electrocardiogram; Acute coronary syndrome; Single-photon emission computed tomography; Technetium-99

OPEN ACCESS

Correspondence:
Nilda Espinola-Zavaleta, Department of Nuclear Cardiology, National Institute of Cardiology Ignacio Chavez, Juan Badiano N°1, Colonia Sección XVI, Tlalpan, P.C. 14080, Mexico City, Mexico,
E-mail: niesza2001@hotmail.com

Received Date: *21 Mar 2022*
Accepted Date*: 27 Apr 2022*
Published Date*: 04 May 2022*

Citation:
Villa-Ramírez CA, Bautista-Pérez-Gavilán A, Ibarra-Moreno A, Perez-Partida AM, Sáenz-Ancira S, García-Cárdenas M, et al. An Atypical NSTEMI Presentation: SPECT Usefulness at the Waiting Room. Ann Clin Case Rep. 2022; 7: 2182.

ISSN: 2474-1655

Introduction

Patients presenting to the emergency room with chest pain and a normal Electrocardiogram (EKG) are not uncommon scenarios. In these cases, high-sensitivity cardiac enzymes alone could be insufficient to confirm an Acute Coronary Syndrome (ACS). However, the use of technetium-99 (99Tc) Single-Photon Emission Computed Tomography (SPECT) in the acute phase of an Acute Coronary Syndrome (ACS) may be useful in detecting abnormalities of coronary blood flow during acute myocardial ischemia.

In this article, we describe the case of a patient who presented with unstable angina while in the waiting room for a myocardial perfusion study. Gated-SPECT confirmed the diagnosis of Non-ST-Segment Elevation Myocardial Infarction (NSTEMI).

Case Presentation

A 52-year-old female patient with a history of tobacco use came to our Nuclear Cardiology Department for myocardial perfusion assessment due to atypical angina. During her preparation for the test in the waiting room, she suddenly presented with oppressive chest pain 10/10 on the Visual Analogue (VAS) Scale which lasted 10 min; and was accompanied by dyspnea and adrenergic symptoms. Three 12-lead EKGs taken at rest showed no ST-segment abnormalities (Figures 1A-1C), while two more subsequent EKGs showed dynamic changes in the ST-segment (Figure 2). With the possibility of unstable angina, 10 mCi of Tc99m MIBI radiotracer was administered intravenously, and the patient was referred to the cardiology department for classification and management. Myocardial perfusion images during this period showed a non-transmural perfusion defect from the apical to the basal third of the inferior wall and in the inferolateral region (Right Coronary Artery [RCA]/Circumflex Artery [Cx] territory), and a transmural apical and middle-third of anteroseptal perfusion defect, which extends as non-transmural to the middle-third of the septal and inferolateral walls (left anterior descending artery territory), (Figure 3). The enzyme curve confirmed a NSTEMI. The patient was admitted to the catheterization laboratory, where an obstructive lesion was observed in the proximal segment of the Left Anterior Descending artery (LAD). Thus angioplasty with drug-eluting stent placement was decided. The Cx and RCA were dominant and chronically occluded, however, these occlusions were collateral and without significant functional impact on myocardial

Figure 1: (A) 12-lead EKG. In A the EKG exhibits a Q-wave in DII, DIII, and aVF with intraventricular conduction disorders. The second ECG (B) showed a Q-wave, repolarization abnormalities in DIII, aVF, and loss of the first vector in V3-V4. In (C), a diffuse and asymmetric inversion of the T-wave in almost all leads was observed.

tissue (Figures 4A-4C).

Discussion

Acute coronary syndromes are classified by EKG in ST-Segment Elevation Myocardial Infarction (STEMI) and NSTEMI. In NSTEMI events, an enzymatic curve is useful to differentiate between myocardial infarction and unstable angina. In patients with unstable angina, mortality risk stratification scales like GRACE, TIMI or HEART are useful [1-4]. High-risk patients are submitted to coronary intervention, while intermediate-to-low risk patients have been shown to benefit more from noninvasive anatomical or functional studies, such as Coronary Computed Tomography Angiography (CCTA) or SPECT. The ERASE study demonstrated improved outcomes when nuclear medicine was employed, 2,475 patients with chest pain were randomly assigned to a conventional or a SPECT-guided approach, demonstrating an improvement of triage effectiveness with the latter method [5]. Nuclear cardiology studies offer considerable advantages in a cardiology department, such as safe radiotracers' use without prior renal or hepatic function evaluation; the versatility of usage in patients with cardiac devices (e.g., pacemakers or implantable cardioverter-defibrillators); and the ability to demonstrate which territory of the myocardial wall is most affected.

Additionally, in patients that present in the acute phase of an ACS, complete revascularization in comparison to revascularization of only the affected vessel is a current controversy. Studies like COMPLETE [6] and DANAMI 3 PRIMULTI favor complete revascularization, whereas others like PRAMI [7] or CULPRIT SHOCK [8] did not and even reported an increase of adverse events through complete

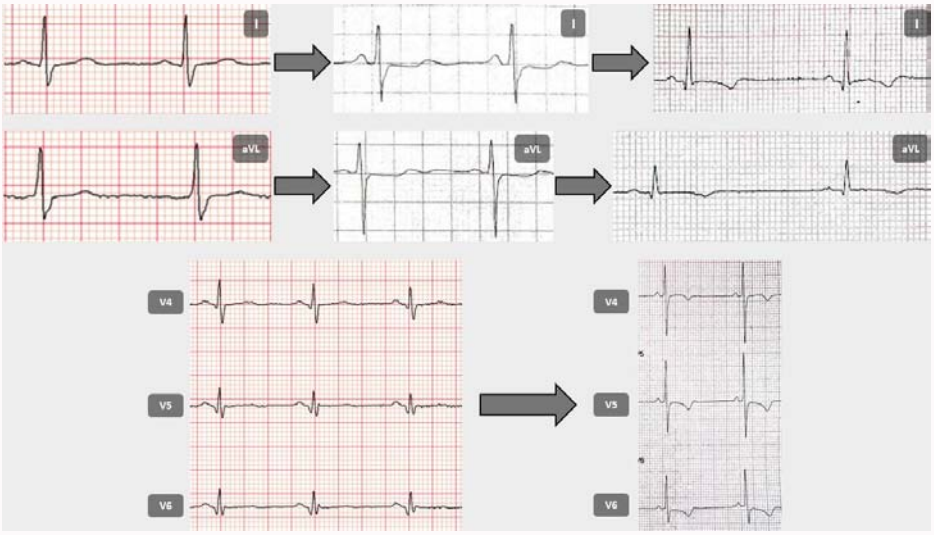

Figure 2: 12-lead EKG with dynamic changes in the ST segment.

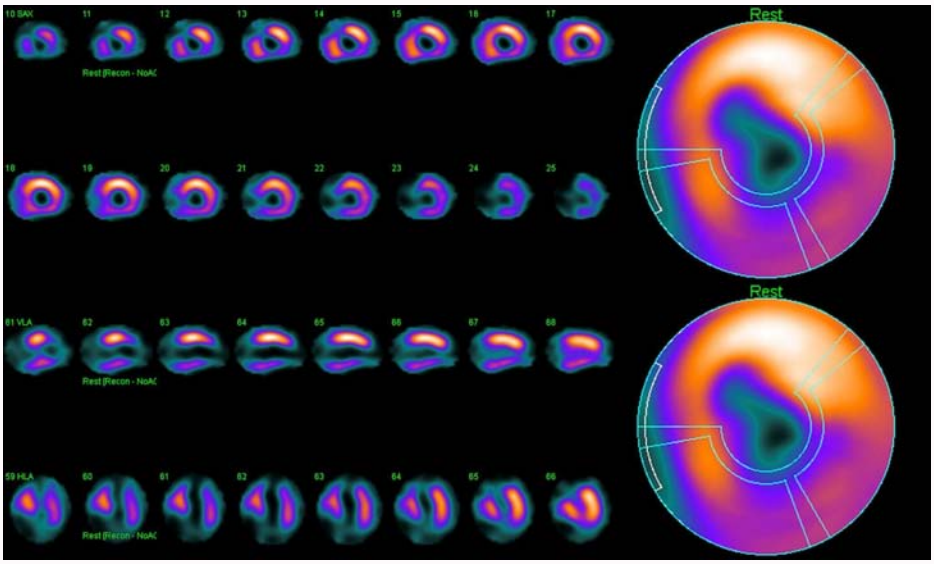

Figure 3: Gated-SPECT. Myocardial perfusion images showed a non-transmural perfusion defect from the apical to the basal third of the inferior wall and in the inferolateral region (Right Coronary Artery [RCA]/Circumflex Artery [Cx] territory), and a transmural apical and middle-third of anteroseptal perfusion defect, which extends as non-transmural to the middle-third of the septal and inferolateral walls (left anterior descending artery territory).

revascularization. In patients with unstable angina, evidence is even scarcer. The SMILE study evaluated 584 patients with NSTEMI who were randomly assigned to single or complete revascularization, revealing a discretely larger benefit with complete revascularization [9]. Myocardial perfusion studies allow physicians to determine which myocardial territories are at higher risk and if an invasive and aggressive revascularization strategy might be more appropriate.

The radiotracers of choice for these protocols are typically technetium-containing agents. Their physical and pharmacokinetic properties allow image acquisition of up to 6 h after administration, reflecting myocardial perfusion at the moment of intravenous injection. Most of the studies that have used SPECT in cardiology departments show both high sensitivity and a Positive Predictive Value (PPV) close to 100% for the diagnosis of myocardial infarction, especially if the radiotracer is injected during an episode of chest pain or during the 6 following hours. Its high sensitivity comes at the expense of its low negative predictive value and specificity which is close to 75%. Another disadvantage is the requirement of an in-situ 99Mo/99mTc generator for radiotracers preparation, in addition to the need for trained personnel and an exclusive emergency-image-acquisition gamma camera [10,11].

A future direction for research could be the inclusion of Tc-containing agents (which give a "frozen" image at the moment of administration) while comparing different revascularization strategies in patients with an ACS, aiming to identify the amount of viable myocardium.

Because of the above-mentioned advantages, myocardial perfusion imaging is an extremely useful tool in patients with chest pain and unclear or unavailable EKG or cardiac enzymes. Myocardial perfusion studies may be used to guide diagnosis, management and as a prognostic tool in patients that are admitted to the cardiovascular emergency room. They have demonstrated a significant risk reduction

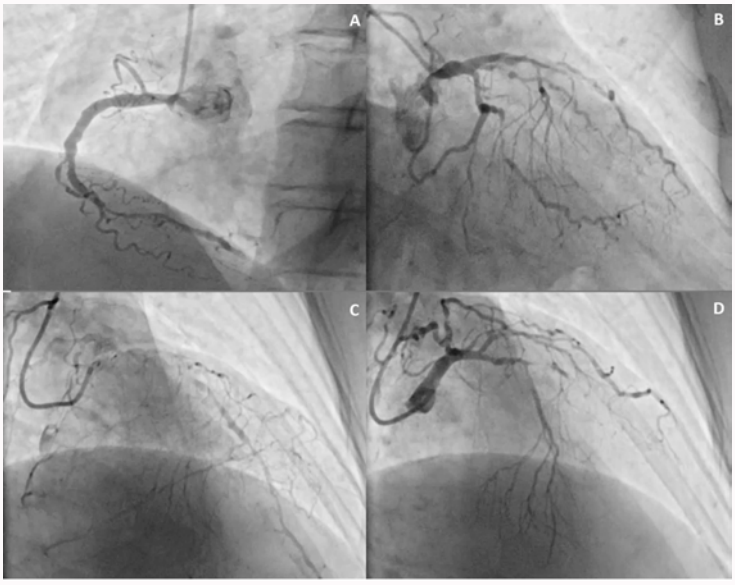

Figure 4: Coronary angiography. (A) The Right Coronary Artery (RCA) was dominant and had a diffuse concentric lesion with irregular margins with maximum stenosis of 90% and a TIMI 2 flow. (B) Diffuse atherosclerosis in the proximal third of the circumflex artery, the distal third had chronic total occlusion (JCTO 2 PTS; PROGRESS 3 PTS) and received collateral circulation from the 2nd marginal branch, Rentrop 2. C, D) The Left Anterior Descending artery (LAD) had a diffuse concentric lesion with regular margins in the proximal third which became a chronic total functional occlusion (JCTO 1 PT; PROGRESS 1 PT), in the middle third that received Rentrop 2, collateral circulation from the RCA and in its distal third a concentric tubular lesion of 80% with regular margins, a coronary muscle bridge, and early marginal branch were observed.

(5% to 0.5%) of erroneous hospital discharge in patients with chest pain.

Conclusion

Myocardial perfusion studies possess a high positive predictive value for the diagnosis of myocardial infarction, improving therapeutic interventions and patients' prognosis. Hence, they are of great use in emergency settings and for the evaluation of patients with chest pain. In this particular case, the anatomical and functional correlation between the perfusion defect at gated-SPECT and the obstructive lesion observed in angiography prompted the diagnostic and therapeutic decision in this patient.

References

1. Fox KAA, FitzGerald G, Puymirat E, Huang W, Carruthers K, Simon T, et al. Should patients with acute coronary disease be stratified for management according to their risk? Derivation, external validation, and outcomes using the updated GRACE risk score. BMJ Open. 2014;4:e004425.
2. Fox KAA, Dabbous OH, Goldberg RJ, Pieper KS, Eagle KA, van de Werf F, et al. Prediction of risk of death and myocardial infarction in the six months after presentation with acute coronary syndrome: Prospective multinational observational study (GRACE). BMJ. 2006;333(7578):1091.
3. Antman EM, Cohen M, Bernink PJLM, McCabe CH, Horacek T, Papuchis G, et al. The TIMI risk score for unstable angina/non-ST elevation MI: A method for prognostication and therapeutic decision making. JAMA. 2000;284(7):835-42.
4. Mahler SA, Riley RF, Hiestand BC, Russell GB, Hoekstra JW, Lefebvre CW, et al. The HEART pathway randomized trial: Identifying emergency department patients with acute chest pain for early discharge. Circ Cardiovasc Qual Outcomes. 2015;8(2):195-203.
5. Udelson JE, Beshansky JR, Ballin DS, Feldman JA, Griffith JL, Heller GV, et al. Myocardial perfusion imaging for evaluation and triage of patients with suspected acute cardiac ischemia: A randomized controlled trial. JAMA. 2002;288(21):2693-700.
6. Mehta SR, Wood DA, Storey RF, Mehran R, Bainey KR, Nguyen H, et al. Complete revascularization with multivessel PCI for myocardial infarction. New Eng J Med. 2019;381(15):1411-21.
7. Wald DS, Morris JK, Wald NJ, Chase AJ, Edwards RJ, Hughes LO, et al. Randomized trial of preventive angioplasty in myocardial infarction. New Engl J Med. 2013;369(12):1115-23.
8. Thiele H, Akin I, Sandri M, Fuernau G, de Waha S, Meyer-Saraei R, et al. PCI Strategies in patients with acute myocardial infarction and cardiogenic shock. New Engl J Med 2017;377(25):2419-32.
9. Sardella G, Lucisano L, Garbo R, Pennacchi M, Cavallo E, Stio RE, et al. Single-Staged compared with multi-staged PCI in multivessel NSTEMI Patients: The SMILE Trial. J Am Coll Cardiol 2016;67(3):264-72.
10. Candell-Riera J, Oller-Martínez G, Pereztol-Valdés O, Castell-Conesa J, Aguadé-Bruix S, García-Alonso C, et al. [Early myocardial perfusion Gated-SPECT in patients with chest pain and non-Diagnostic ECG in the Emergency Department]. Rev Esp Cardiol. 2004;57(3):225-33.
11. Barbirato GB, de Azevedo JC, Felix RCM, Correa PL, Volschan A, Viegas M, et al. Use of resting myocardial scintigraphy during chest pain to exclude the diagnosis of acute myocardial infarction. Arq Brasil Cardiol. 2009;92(4):269-74.